

**SEMMELWEIS EGYETEM  
DOKTORI ISKOLA**

**Ph.D. értekezések**

**2933.**

**OLIVER BLUME**

**Fogorvostudományi kutatások  
című program**

Programvezető: Dr. Varga Gábor, egyetemi tanár

Témavezető: Dr. Windisch Péter, habilitált egyetemi docens

**Usability and Tissue Stability of CAD/CAM Prefabricated  
Allogenic Bone Blocks for the Reconstruction of Severe Bone  
Defects in the Aesthetic Zone of the Maxilla**

**Ph.D thesis**

**Oliver Blume MD, DMD**

Károly Rácz Doctoral School of Clinical Medicine  
Semmelweis University Budapest



Supervisor: Péter Windisch DMD, Ph.D

Official reviewers: Tamas Sass DMD, Ph.D

Tamas Huszár DMD, Ph.D

Head of the Complex Examination Committee: Gábor Varga DMD, D.Sc

Members of the Complex Examination Committee: Katalin Nagy DMD, D.Sc  
Attila Szücs DMD, Ph.D

Budapest 2023

## Table of contents

List of abbreviations .....	III
1. Introduction .....	1
1.1 Bone grafting .....	1
1.1.1 Goals .....	1
1.1.2 Bone graft materials.....	2
1.1.3 Medical indications.....	7
1.2 Bone growth, repair and remodeling .....	9
1.2.1 Bone cells .....	9
1.2.2 Bone growth .....	12
1.2.3 Bone repair and remodeling .....	13
1.3 Current state of research and development in bone grafting .....	16
1.4 Guided bone regeneration using customized allogenic bone blocks .....	18
2. Objectives .....	24
2.1 General objective .....	24
2.2 Special objective .....	24
3. Materials and methods.....	26
3.1 Sources and collection of data .....	26
3.1.1 General study design .....	26
3.1.2 Semi-automatic segmentation method (SA).....	29
3.1.3 Global thresholding segmentation method (GT).....	29
3.1.4 Linear measurements .....	30
3.2 Patient demographics .....	32
3.3 CAD/CAM customization .....	33
3.4 Surgical procedure .....	34
3.4.1 General procedures .....	34
3.4.2 Flap elevation .....	35
3.4.3 Fixation of the allogenic bone block .....	36
3.5 Data analysis .....	37
4. Results .....	38
4.1 Patients and methods.....	38
4.2 Volumetric hard tissue changes .....	40
4.3 Linear hard tissue measurements .....	42
4.4 Effect of surgical size on clinical outcomes .....	44
4.5 Implant stability .....	45

4.6 Histological findings .....	46
4.7 One-year follow-up examination .....	49
4.7.1 Patient satisfaction .....	49
4.7.2 Clinical findings .....	49
4.7.3 Radiographical findings.....	51
5. Discussion.....	54
6. Conclusion .....	59
7. Summary.....	60
8. List of references .....	61
9. Bibliography of the candidate's publications .....	68
10. Acknowledgements .....	V
Figures .....	VI
Tables.....	VII

## List of abbreviations

BMP	bone morphogenic protein
CAD/CAM	Computer Aided Design and Computer Aided Manufacturing
CBCT	Cone-beam Computed Tomography
CT	Computed Tomography
DFDBA	demineralized freeze-dried bone allograft
DSC	dice similarity coefficient
DVT	Digital Volume Tomography
FDDBA	freeze-dried bone allografts
FFBA	fresh frozen bone allografts
FGF	fibroblast growth factor
GT	global thresholding segmentation
HVC	horizontal, vertical and combination
IGF-1	insulin-like growth factor-1
OPG	osteoprotegerin
PDGF	platelet-derived growth factor
PRF	platelet rich fibrin
PRP	platelet rich plasma
RANKL	receptor activator of nuclear factor kappa- $\beta$ ligand
SA	semi-automatic segmentation
TGF- $\beta$	transforming growth factor- $\beta$
VEGF	vascular endothelial growth factor

# **1. Introduction**

## **1.1 Bone grafting**

In order to understand the goals and procedures of the current Ph.D thesis, it is important to first define the term bone grafting and why it is done. Bone grafting can be carried out with different techniques and different materials, which will be explained in the following chapter. Further, the features of the distinct bone grafting materials will be explained in detail. This gives rise to the understanding why we preferred a certain bone graft material in our research.

### **1.1.1 Goals**

Bone grafting and bone reconstruction is a surgical procedure with the goal of replacing missing or resected bone material. This can be indicated when a patient suffered severe trauma to the bone, after resection of bone material, in patients with tumors, bone defects stemming from developmental disorders, or after the loss of teeth, due to severe periodontitis for example or due to the physiological atrophy of unloaded bone [1,2]. The goal of bone reconstruction is to completely restore the lost bone material which would not heal properly unassistedly for functional and aesthetic reasons. Bone augmentation uses transplanted bone and bone substitute materials to repair and restore diseased or damaged bone. This can be done almost everywhere in the body [3,4]

When bone is damaged due to an accident, trauma, a tumor or an infection, the natural healing process begins. As long as the damage to the bone is not too large, it can heal and restore itself naturally. The bone cells have the capacity to completely repair the damaged bone. On the other hand, when large portions of bone are lost due to trauma or large parts of the bone have been damaged by an infection or a tumor, the bone cannot restore itself naturally. Complete healing and restoration of the bone is, thus, not possible. In such cases bone grafting and bone reconstruction might be medically indicated [1-3].

Especially in the fields of maxillofacial and oral surgery the bone grafting techniques and materials have been improved significantly during the past years and decades. The reason

for this progress in research and development is the necessity of sufficient bone when it comes to dental implantation. Surgical procedures like osteoplastic operations, often combined with bone transplants or bone substitute materials, are used where the pristine bone of the patient has been damaged and needs to be restored, so that the bone cells inside the bone graft can seal themselves to the native bone of the patient [1]. For bone grafting, there are several possibilities, types and techniques. This will be discussed in the following chapters.

### 1.1.2 Bone graft materials

To date, several types of bone graft materials have been researched, developed and used. Hereby, the bone graft materials can be differentiated according to their origins [1,2]:

- Autologous
- Allogenic
- Xenogenic
- Synthetic

The materials mentioned above have different osteoinductive, osteogenic and osteoconductive properties [1,5,6]. The optimal bone graft material possesses osteogenic, osteoinductive as well as osteoconductive properties [3,7,8].

The different properties of the bone graft materials are listed in the table below:

**Table 1.** Properties of different bone graft materials. (Source: Baldwin 2019 [3])

<b>Bone graft material</b>	<b>Properties</b>
Autologous	Osteogenic, osteoconductive, osteoinductive
Allogenic	Osteoconductive, in some cases also osteoinductive

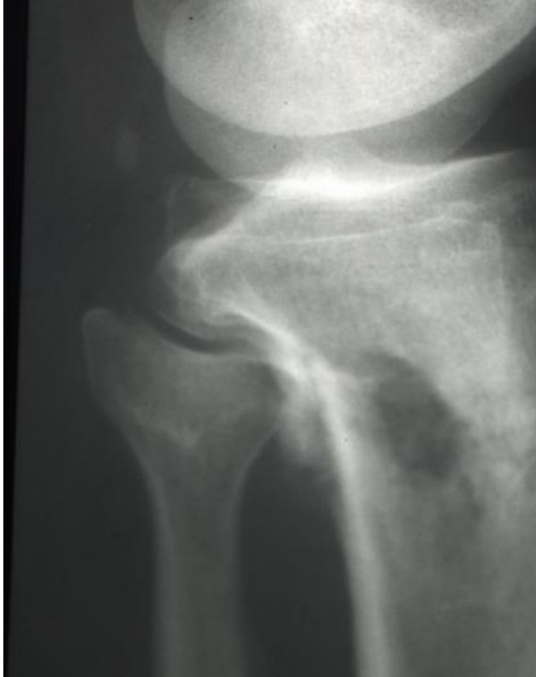Xenogenic	Osteoconductive
Synthetic	Osteoconductive

For a successful reconstruction of a hard tissue defect also the biomechanical stability of the grafting material is of great importance. Furthermore, there should be optimal conditions for neovascularisation and osteogenesis. Another important aspect, which affects the success of bone grafting is re-vascularisation [3,13]. This is a crucial factor for the vitality, function and regeneration of reconstructed bone [3,7,13-15]. Furthermore, the knowledge and skills of the surgeon are of great importance as well as the selection of material and the choice of the operation technique [3,7].

Autologous bone grafts have been considered as the gold standard to date because these materials provide in certain circumstances osteogenesis as well as neovascularisation [3,7,8]. Nevertheless, several risks with autologous bone grafts have been described [7-9]. Advantages of autologous bone grafts are histocompatibility and possess of osteogenic properties. Further, there is no risk of a possible transmission of diseases [10]. Problematics and challenges, which are associated with autologous bone grafting can be the need for general anesthesia, the limited supply, the increased magnitude of surgery, increased time for the operational procedure as well as the amount of blood loss for the patient and bone resorption as an unexpected event [9-10]. To date, the greatest concern with autologous bone grafting is the donor site morbidity [9-11]. This can include major complications like infections, the need for re-operation, chronic pain, wound drainage and sensory loss [9-11]. Other minor complications with autologous bone grafting can include wound healing problems, pain at the donor- and/or acceptor site and minor wound infections [11]. It has been shown previously that the degree of morbidity of autologous bone grafts strongly depend on the harvesting site [9-11]. The morbidity of using the iliac crest as the harvesting site has been well documented so far [9-12]. Complications include fractures, bleedings, acute and chronic pain as well as possible neural injuries. The risk of morbidities depends on the extent of harvesting and appears to be lower if a smaller piece of bone is transplanted [9-11].

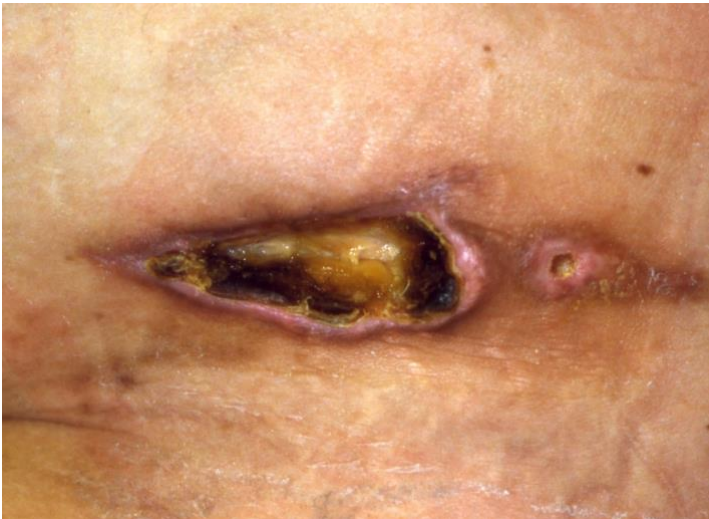The following figure shows a fractured tibia after harvesting of bone material from it:





**Figure 1.** Fractured tibia as complication after harvesting autologous bone material.  
(Source: own work)

Another complication, shown in the figure below, is necrosis of the soft tissue after harvesting bone material for autologous bone graft from the iliac crest:



**Figure 2.** Necrosis of the soft tissue at the iliac crest. (Source: own work)

While autologous bone graft materials originate from the same species and the same individual, allogenic transplants are derived from the same species but not the same individual [3,7,16]. So, this means for humans that the patients themselves receive the bone graft from another individual. Allogenic hard tissue grafts have gained popularity in the field of dental bone grafting, due the limited amount of donor tissue and to the possible complications, which can arise during or after harvesting [16,17]. The bone material for allogenic bone grafts is harvested during orthopaedic hip prosthesis surgery. The resected femur head is then cleaned and prepared for donation after having obtained written consent of the patient. In contrast to autologous bone material, pure allogenic bone is not capable of growing new bone by itself. Allogenic bone transplants are used as framework and the osseous tissue, which proliferates into the allogenic transplant derives from the patient's natural bone, which grows around the graft [16].

Nevertheless, allogenic bone graft materials possess several advantages over autologous bone [18]:

- 1) No risk of donor site morbidity and related complications
- 2) No second surgical site
- 3) Less patient discomfort
- 4) Reduced surgery time
- 5) Unlimited supply

The challenge with allogenic bone is, that it lacks osteoinductive properties. This can be overcome by adding growth factors like platelet-rich plasma (PRP) or gain platelet-rich fibrin (PRF) for example [18,66].

The difference between allogenic and xenogenic material is, that the allogenic bone grafts derive from the same donor species as the receiver, while the xenogenic material stems from a different species. Xenogenic bone graft materials are clinically widely used. The allogenic material is derived from another human being if the recipient is a human, while the xenogenic bone graft is mostly of bovine or porcine origin. It is also possible to gain xenogenic transplants from corals or plants.

By further chemical and thermic procession of xenogenic bone material, ceramic bone materials can be produced. The basis for these materials is mostly hydroxyapatite, which

represents also a large part of the natural bone material. Dependent on the temperature of the sintering procedure further materials like tricalciumphosphates can be yielded. Ceramic materials are mostly used as hydroxyapatite, tricalciumphosphates or mixtures of both. Tricalciumphosphates are quicker resorbed than hydroxyapatites. The latter are more stable to resorption. Nowadays, those xenogenic materials can also be produced full synthetically. The advantage of alloplastic materials is good biocompatibility and elasticity, low costs, good availability and easy storage [3]. But it is important to mention that if the bone graft differs significantly from the natural human bone in consistence, structure and porosity, it loses its biological value. Thus, a full synthetic hydroxyapatite possesses a lower biological value for bone reconstruction than allogenic bone material [3].

Which bone graft material fits best of a certain patient, is determined by the extent of the bone defect as well as the damage of the surrounding soft tissue. Another important determining factor is the current health-state of the patient as well as the surgical method which is chosen. In order to make the correct decision, a precise diagnostic is required [3,20,21]. To date, the autologous bone graft is still often recommended as the first choice [3,20,21]. This is because the risk for a rejection reaction is the lowest with autologous bone graft material. Furthermore, autologous material has osteoinductive as well as osteoconductive features, as shown in table 1 [3,19-21].

But to date, the possibilities of treating bone defects with autologous bone graft materials are still limited [3]. Furthermore, for the patients, autologous bone grafting requires additional surgery, to harvest the bone graft material and this may be dangerous for the health of certain patients. The additional surgery may also pose a further health risk for some patients. The surgical procedure which is required to harvest the autologous bone can bear complications and it is important to precisely consider the advantages and the risks for an additional surgery [3]. The most common complications associated with the surgery harvesting the autologous bone are damages to the nerves in that particular area, risk of post-operative infections, risk of fractures in the bone, where the autologous material was harvested from and risk of bleedings. It has to be also mentioned that the amount of autologous bone graft material which can be harvested, is limited.

Furthermore, in children and adolescents as well as in patients with severe injuries, alloplastic or allogenic bone grafting are performed for the reason mentioned above

[3,20,22]. Even though autologous bone materials are still the gold standard, new laws for purification and storage of allogenic bone material in Germany, have significantly minimized the risk of contamination. If the osteoinductive features of the allogenic material can be improved once by adding growth factors, this would make allogenic bone material to a promising alternative to autologous bone grafts. However, to date, treatment of complex bone defects, especially in the aesthetic areas, remains a challenge [3,7,23,24].

### **1.1.3 Medical indications**

In the body, there is a continuous cycle of bone tissue formation and resorption. These processes are carried out by osteoblasts, osteoclasts and osteocytes, regulated by a number of signal transduction pathways. Under certain circumstances this cycle is defective or the bone has been damaged to an extent that it cannot heal naturally to its healthy form [3,25,26]. In such cases bone grafting is required in order to help the bone heal back into its original form. Several types of bone grafting materials exist which were described in chapter 1.1.2. Bone graft surgery is indicated when there is too little bone substance in a certain bone area of the human skeleton, so that the damaged bone cannot naturally heal into its original form. This can be due to [3,25,26]:

- Tumors
- Trauma (accidents for example)
- Periodontitis and other infections
- After a surgical procedure, for example tumor resection
- Bone defects due to malformations
- Insufficient bone material due to bone atrophy

Thus, a bone graft is medically indicated when an extended amount of bone material has been lost, so that it is impossible that the bone heals naturally into its healthy state.

In such cases, bone grafts are medically indicated to potentiate the bone healing process [3,20]. Even though autologous bone grafts have high osteoinductive potential and no risk of immunogenic reaction as well as minimal risk of disease transmission, they have restrictions in availability and donor site morbidity [3,18,25,26]. Allogenic bone material is available in sufficient amounts in order to treat even large and severe bone defects [18]. The most frequent indication for dental bone grafting is due to tooth extraction [27]. In Germany, about 10 million tooth extractions are performed per year [27]. The most common medical indications of tooth extraction are [27]:

- Caries
- Periodontitis
- Orthodontic treatments
- Injuries and traumas

After tooth loss or tooth extraction it is crucial to maintain the affected bone [27,28]. When it is not worth to keep a certain tooth or several teeth anymore, due to severe caries, periodontitis, other damage or aesthetic reasons, they will be extracted and the patient receives a prosthesis for the missing tooth or the missing teeth. For the patients, not only dental health, but also the aesthetic aspects play an important role [29]. Enosseal implants are crucial for the replacement of teeth and the fixation of the prostheses. Therefore, bone material sufficient in quantity and quality is the key to successful implantation. This is why, after tooth loss or tooth extraction it is crucial to maintain or reconstruct the affected bone [27,28].

Hereby, the horizontal- and vertical dimensions of the affected bone and the surrounding soft tissue are of great importance. Further, an efficient integration of the bone graft and the choice of the right material is hereby crucial [29]. The goal of every single bone grafting is to achieve 100% formation of intact bone tissue, which will surround the implants [30].

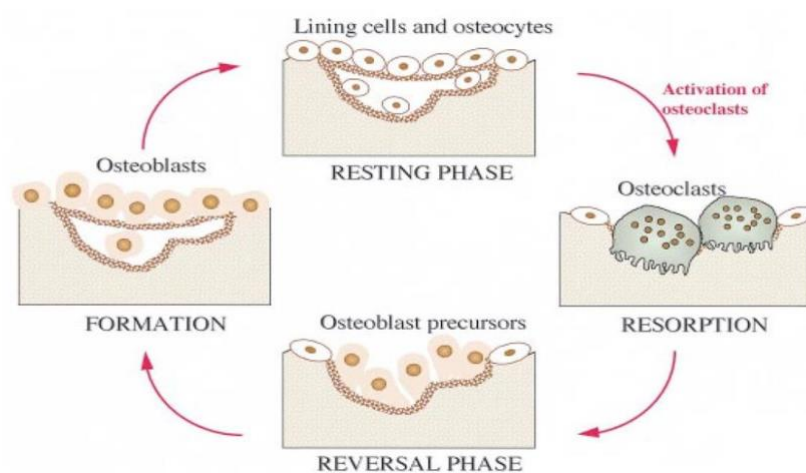
## 1.2 Bone growth, repair and remodeling

In order to understand the principles and effects of the different bone materials, it is important to first comprehend the basics about bone growth, remodeling and repair. Thus, this chapter aims to explain the fundamentals of growth and healing of natural bone.

### 1.2.1 Bone cells

The bone has remarkable regenerative properties because it is a highly dynamic organ. Important for the maintenance of bone homeostasis are viable bone cells: Osteoblasts, osteoclasts and osteocytes. Another crucial factor is perfusion and therefore, adequate vascularity. Growth factors are also required for bone growth and maintenance. When one or more of these mechanisms are inadequate, bone healing cannot occur properly. Thus, surgeons have to enable their patients to heal and regrow bone.

In the figure below the bone remodeling cycle is shown:



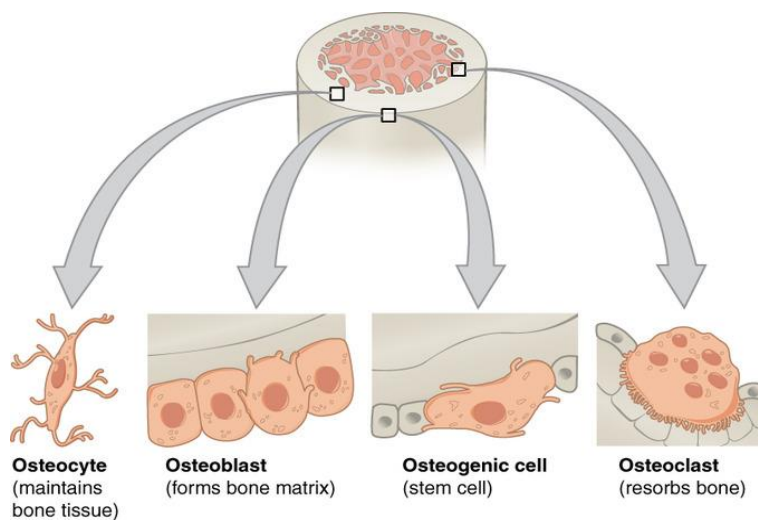
**Figure 3.** The bone remodeling cycle. (Source: Hill 1998 [67])

A fundamental aspect of bone growth, regrowth and remodeling is its dynamic nature [32]. There is a delicate balance between formation and resorption of bone material,

between the action of osteoblasts, osteoclasts and osteocytes. In fact, the bone material of the human skeleton is being replaced in its entire life. Every ten years the bone material of the skeleton is resorbed and renewed [31,32].

Bone consists of minerals and organic material. About 65% of bone substance is hydroxyapatite, in crystalline form, the remaining 35% is organic material. The latter is mainly composed of primarily Type-I-Collagen and non-collagenous proteins like osteopontin, osteocalcin and osteonectin. Those proteins form bonds between the collagen fibrils and play important roles in facilitating bone mineralization. Thus, the bone gets stability and strength through mineralization but also some flexibility by the collagen and the other organic material [33,34].

Several cell types can be found in bone tissue, responsible for bone maintenance during the whole life span of a human being. Bone cells develop from two distinct lineages: The osteogenic and the monocyte-macrophage lineage [34]. There are four types of bone cells, which are responsible for bone growth, renewal, resorption and remodeling: Osteoblasts, osteoclasts, stemcells and osteocytes, shown in the figure below:



**Figure 4.** The four types of bone cells. (Source: Ansari 2019 [38])

On the bottom left in the figure above the osteocytes are shown: Those are matured osteoblasts and are derived from mesenchymal stem cells. About 95% of all bone cells are osteocytes. The main role of the osteoblasts is the deposition of the osteoid matrix of the bone material [33]. During maturation the osteoblast becomes fused with the bone matrix material and matures into an osteocyte [33,34]. Osteocytes are large cells with multiple nuclei which stem from the fusion of multiple monocytes [33].

The mesenchymal stem cells, shown in the figure above (bottom, second from right) are cells which possess multiple potencies. They can differentiate into several different cell types. The stem cells play a crucial role in skeleton development during childhood and adolescence. In adult people the stem cells are found as in the periosteum, the bone marrow and the endosteum [34]. Upon stimulating signal for osteogenesis by distinct growth factors, the stem cells start their proliferation into osteoprogenitor cells. The osteoprogenitor cells stem from the osteochondral lineage, mentioned above, and are only able to differentiate into cells of the chondrogenic or osteogenic pathways. Osteoprogenitor cells are regulated by growth factors which stimulate the differentiation of osteoprogenitors into osteoblasts and eventually into osteocytes [33,34].

The osteoblasts, shown in figure 2, bottom, second on the left, provide the formation of the bone matrix and the production of bone material. They also play the key role in renewing bone tissue, modelling and re-modelling of the bone [33,34]. Osteoblasts possess a rough endoplasmatic reticulum and large Golgi apparatuses. The osteoblasts control, besides bone growth, modelling, remodeling and renewal also the bone mineralization processes [34].

Osteoblasts and osteocytes play a crucial role in the signal transduction pathways during bone growth and remodeling. Both cell types secrete signal proteins: Receptor activator of nuclear factor kappa- $\beta$  ligand (RANKL) and osteoprotegerin (OPG). The signal protein RANKL gives the signal for the maturation of osteoblasts and stimulates the resorption of bone material by osteoclasts [33]. The signal transduction protein OPG represents the antagonist of RANKL. It binds and sequesters RANKL, so that it cannot bind to the receptors on osteoclasts anymore. Another signal glycol-protein, Sclerostin, which stems from mature osteocytes seem to play an important role in regulation of bone mass [35]. Sclerostin is secreted when mechanical loading or an inflammation occurs. Inflammatory signals, such as prostaglandin or hormones such as estrogen, gonadotropin releasing



hormone or parathyroid hormone, stimulate the secretion of Sclerostin. The latter functions as negative regulator of bone mass and downregulates the activity of osteoblasts [36]. Thus, Sclerostin may play a crucial role in osteoporosis and its related bone fractures. Sclerostin may also play a role in insufficient osseointegration of implants [35]. Finally, the osteoclasts, shown in figure 2, bottom left, are derived from the vascular channels of the bone, from mononuclear precursor cells. Osteoclasts are large cells which possess multiple nuclei. The key role of osteoclasts is to remove and resorb bone material. During the bone remodeling process osteoclasts can be found in temporary cavities on the bone surface. Those cavities are called Howship's lacunae. Bone lining cells which retract from their usual location on the surface of the bone initiate the activity of the osteoclasts. The latter then attach to the bone matrix and start to break down bone material. The ions and minerals which result from bone breakdown are released by the osteoclasts into the extracellular matrix, hereby homeostasis can be maintained [33,34]. Osteoclasts, even though playing the key role in bone resorption, do not secrete signal proteins or ligands. They merely react to stimuli from the signal transduction pathways [35].

### **1.2.2 Bone growth**

The formation of new bone material and the growth of the bones occur during development from embryo to adult. The adaption of bone mass and remodeling occurs during the whole life span of an individual, depending on mechanical loadings (in sports for example or work). Hereby the geometry of the bone adapts to the specific loadings. The formation of new bone mass can take place through two different pathways: Intramembranous ossification or endochondral ossification. During bone growth, both pathways have in common that initially, organic material, osteoid or cartilage are deposited in the newly growing bone. By time, mineralization occurs in order to produce the stable bone matrix [34].

Endochondral ossification occurs in new bone formation in the embryo. It is initiated by the mesenchymal stem cells (see figure 3). The stem cells differentiate into chondroblasts and chondrocytes, while the latter secrete growth factors, initiating mineral deposition and promoting vascularization. Furthermore, the growth-factors activate and

recruit osteoblasts. The endochondral ossification takes place during childhood and adolescence [34].

Another pathway of bone formation and growth during development is the intramembranous pathway, which leads to the formation and growth of non-long bones. The stem cells within an embryo proliferate and aggregate. This aggregate becomes surrounded by a membrane. The stem cells then proliferate into osteoprogenitor cells and then, into osteoblasts. The osteoblasts begin to secrete an extracellular matrix material in which they eventually become embedded. There, they differentiate into osteocytes, forming the bone matrix [34].

### **1.2.3 Bone repair and remodeling**

Bone repair, renewal and remodeling occurs during the whole life span of an individual, from birth into late adulthood. Bone remodeling means that old bone tissue is broken down and replaced by new, fresh bone material. Thus, it involves bone decomposition by osteoclasts and the production of new bone material by osteoblasts. Bone break-down and renewal are regulated by several hormones and growth factors such as parathyroid hormone, Estrogen, calcitonin RANKL, Sclerostin or OPG [33,34]. The purpose of bone remodeling is the adaptation to mechanical load or other stressors. The bone therefore becomes thicker, more stable and more resistant to potential damages [34].

In the case, when damage to the bone occurred, due to an injury for example, bone repair mechanisms take place. Bone repair takes place in three different phases [33,37]:

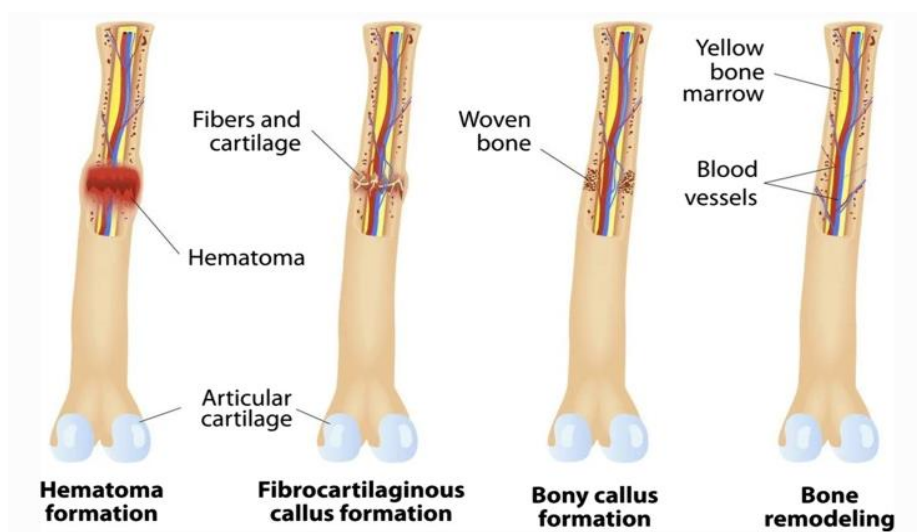
- 1) The inflammatory phase
- 2) The proliferative phase
- 3) The remodeling phase

The regulation of the inflammatory phase is exhibited by several inflammatory mediators and growth factors such as insulin-like growth factor-1 (IGF-1), transforming growth factor- $\beta$  (TGF- $\beta$ ) platelet-derived growth factor (PDGF), fibroblast growth factor (FGF), vascular endothelial growth factor (VEGF), interleukins and bone morphogenic proteins

(BMPs). The secretion of these growth factors leads to the recruitment and proliferation of mesenchymal stem cells (figure 2) at the place of injury and aid their proliferation and differentiation into osteoblasts (figure 2). This leads to the formation of a primitive callus [33].

In this callus the proliferative phase begins. A periosteal response occurs which leads to ossification of the callus. Thereby, lamellar bone is created then during the repair and remodeling phase by mineralization. The mineralized callus is converted into bone material, the bone heals to its natural shape and size and re-gains its stability [37].

When a bone is damaged, blood vessels can be torn. This leads to the formation of a hematoma. The blood clotting process starts and affected bone cells diminish, which do not receive enough blood because of vascular damage. Days after the damage, new blood capillaries grow into the place of the hematoma and immune cells remove the dead bone cells by phagocytosis. This builds the basics for the formation of new bone. The production of new bone materials starts as soon as coagulated blood which was formed by inflammation is substituted by fibrous tissue and soft callus [38]. The callus is replaced by new stable bone material; thus, the soft callus turns into hard callus. The osteoblasts form now new hard bone material by mineralization of the callus and the fractured bone returns to its normal form and stability. This process can take up to a couple of months. Once, the bone material is restoring, weight bearing induces the complete bone healing, as shown in the following figure:



**Figure 5.** Bone repair and restorage. (Source: Ansari 2019 [38])

### **1.3 Current state of research and development in bone grafting**

As the basics of bone growth, remodeling and repair have been explained in the previous chapter, the current chapter focusses on the latest research and development in bone grafting. Currently, if complete bone healing and restoration cannot occur naturally in a patient, bone grafting is an accepted treatment [38]. The preferred bone graft materials are either xenografts, allografts or autografts. In modern dentistry, bone grafting represents a standard procedure with dental implants.

Studies have shown that up to 50 % of dental implant placements are associated with procedures which aim to improve the status and health of the bone, like bone grafting [58-60]. In our private practice we counted 7587 patients who needed implantation between 2012 and 2022. In 3392 (44,7 %) of them, also bone grafting was medically indicated, whereby 4195 (55,3 %) implants could be inserted without bone grafting.

To date, treating complex and severe bone defects of the alveolar bone remains a demanding topic for dentists. There is a double challenge for the dentist: Not only the functional aspect has to be considered, but also the aesthetic one. Restoration of the alveolar bone in the aesthetic zone requires both. With autologous bone graft material this topic remains still a great challenge or is not even possible due to the drawbacks and limitation of the autologous bone grafting procedure which have been described in the previous chapters. Thus, the clinicians options to treat such complex alveolar bone defects are still limited [23,45,46].

For alveolar ridge reconstruction and -preservation autologous bone is still seen as the gold standard because it possesses osteoinductive, osteoconductive as well as osteogenic properties [3,7,8]. The autologous bone is harvested from either intra- or extraoral parts of the body [40].

Nevertheless, autologous bone grafts bear disadvantages, limitations and drawbacks (see chapter 1.1.2) like donor site morbidity, increased operation time, increased costs and complications as well as unpredictable resorption [17,23].

Allogenic bone grafting represents a suitable alternative to autologous bone. In Germany the material is mostly obtained from living human donors. This bypasses the problems of donor site morbidity and the limited amount of bone material available in autologous bone grafts. Allogenic bone is available as micellized and cancellous chips, demineralized

bone matrix, corticocancellous- or cortical graft materials. Furthermore, osteochondral and whole bone segments and blocks are available [4]. Allogenic bone may have various biological characteristics, some of the bone materials possess reduced osteoinductive properties. There are no cellular components.

Allogenic bone grafts have recently become more popular in modern dentistry, when it comes to the indication of alveolar ridge preservation [41,42]. Allogenic bone graft materials are often discussed as possible and suitable alternatives to autologous bone. Despite the finding of organic tissue remains in allogenic bone graft materials, studies could not find any clinical consequences of the utilization of allogenic bone graft materials, examined by validated purification methods and techniques [41,42].

The goal of the review study of Nkenke & Stelze (2009) [49] was to analyze the state of the literature concerning autologous- and allogenic bone grafting. The authors researched the literature that was available on the possible advantages and disadvantages of autologous bone graftings over bone substitutes in sinus floor augmentation in edentulous or partially dentate patients. Main outcomes were patient morbidity, sinusitis, implant survival, costs, risk of infections and transmission of diseases as well as graft loss. The literature analysis of the authors was limited to titanium implants with modified surfaces placed in sites with 6 mm of residual bone height and a lateral wall approach to the sinus. The literature research was focused only on human studies with sinus floor augmentation. Nkenke & Stelzer (2009) reviewed 21 publications, which matched their inclusion criteria. The highest level of evidence was found in prospective cohort studies. They found out that the type of bone graft material was not associated with success of the procedure. Nor were the complications and the duration of implant survival associated with the type of bone graft material used. Furthermore, the authors detected three studies showing that autologous bone grafts were associated with donor site morbidities. They found no significant effect of the bone graft material on the overall clinical outcome. This means that allogenic bone grafts seem non-inferior to autologous bone graft materials. Thus, Nkenke & Stelzer (2009) concluded that there may be no specific reasons to prefer autologous bone graft materials over other types of materials [49].

Allografts can be categorized into fresh frozen bone (FFBA), freeze-dried bone (FDBA) and demineralized bone (DFDBA) [39,55]. Especially freeze-dried bone allografts (FDBA) have been found to be well tolerated in previous studies [43, 44]. Low block

graft failure rates as well as minimal resorption and high survival rates of the implant could be showed with the FDBA [43,44,47]. Therefore, allogenic bone substitutes represent a valuable alternative to the autologous ones [49]. Studies have shown new solutions from the field of regenerative medicine in alveolar crest osteoplasty and bone grafting in general [43-49,58,60]. Research with allogenic bone grafting, adding growth factors like bone morphogenic protein 2 (BMP2) or platelet rich plasma (PRP) has been going on for the recent years [47-49]. Despite intense research in alternatives to autologous bone grafts, especially in the aesthetic areas, not much change has been going on in the treatment protocols [48], even though the idea of allogenic bone grafting with the addition of growth factors is not completely new. Further, allogenic bone graft materials are often used after the failure of the autologous bone graft [50].

Altogether, the application of allogenic bone blocks is becoming a popular alternative method to conventional augmentation procedures known to date.

A significant advantage of allogenic bone blocks over autologous bone material is the possibility of CAD/CAM technology. The allogenic bone blocks can be designed and fitted for each patient individually. The bone blocks are patient customized and are suitable for complex alveolar ridge augmentation. But still, there is limited research and limited literature on alveolar bone grafting with patient customized allogenic bone blocks. Thus, the current work aims to introduce its use in Guided Bone Regeneration for severely deficient bones. Additionally, a newly developed remote incision technique is presented. This technique is meant to avoid wound dehiscence. Established histological and histomorphometrical analyses of the tissue reactions and the integration pattern of the material are included to show its remodeling capacities. Furthermore, the current work aims to introduce volume rendering programs which can monitor the healing procedure after bone block grafting and are also able to measure the changes in volume of the bone during the healing process. A follow-up examination after the healing process was carried out.

#### **1.4 Guided bone regeneration using customized allogenic bone blocks**

The functional- and aesthetic advantages of computer-aided- and design-computer-aided manufactured (CAD/CAM) allogenic bone graft blocks lies in the precise fit of complex bone defects [48,51]. The space between the residual bone and the bone graft can be

reduced to a minimum by CAD/CAM. Thus, the physical contact between the residual bone and the graft material can be enhanced. This leads to easier revascularization and integration at the recipient site [53]. The direct contact with adjacent bone tissue allows a fast nutrition of the bone. Studies have shown that the application of the CAD/CAM allogenic bone blocks may reduce surgery time significantly. This is because the allogenic bone block does not have to be shaped anymore [48, 51-53, 59]. Previous studies could show that this significantly reduced time for surgery resulted in low complication rates. Risk of infection of the recipient site, which represents a major complication of allografts, could also be reduced with CAD/CAM [48,53,54].

The objective of one of our previous studies was to introduce CAD/CAM customized bone blocks for guided bone regeneration in patients with severely deficient maxillary bones [51]. It was one of our case reports in order to introduce guided bone regeneration with the help of CAD/CAM customized allogenic bone blocks in severe deficient bones. Furthermore, we introduced a newly developed remote incision technique. This new incision design was designed like a "semi-pillar" [51]. Therefore, we did not perform the incision over the alveolar ridge, but 20 mm horizontally in the flexible mucosa. This was accompanied by a lateral relief incision. A mucoperiosteal flap was elevated from the maxillary bone. This left the mucosa still covering the defect intact.

With this new flap design the incision can be relocated into the vestibulum. This leads, therefore, to the preservation of the intact keratinized mucosa on the alveolar ridge. The wound area is not in the region of maximal tension, instead, we could achieve tension-free wound closure. The wound healing is taking place in an area with maximal perfusion, thus, visible scars can be avoided which represents a crucial aesthetic aspect for many of our patients [52].

By utilizing a remote 'semi-pillar incision' technique we achieve a complete tension-free primary closure. This is because of the inability to obtain tension-free closure of the advanced flap can encourage incision line opening and membrane exposure. Those are common complications following augmentations with cancellous block allografts [54]. We describe the following advantages of this new technique:

- 1) Keratinized mucosa on the alveolar ridge as well as the papillae stay intact



- 2) Rarely visible scars from the surgery are left
- 3) The incision is positioned far away from the graft

This technique was also designed and developed in order to avoid wound dehiscence.

We could show optimal integration of the allogenic bone blocks after six months. We observed new, vital bone which had been formed. We could demonstrate in this case study that CAD/CAM allogenic bone blocks are eligible for treatment of complex and severe bone defects in the maxillary aesthetic zone [51].

Another previous case study of our research group demonstrated the successful treatment of a bilaterally severely resorbed posterior mandible by CAD/CAM-customized allogenic bone blocks [52]. We could show a significant shorter operation time compared to conventional methods and however, infection rates were also reduced to a great extent. Manual adjustment of the bone block is, thus, not necessary, as the bone graft is already shaped and designed by computer, for fitting precisely into the morphology of the defect. We could show that the customized fitting and the minimization of the space between the residual bone and the graft could support revascularization and leads to fast integration of the graft into the residual bone. We could conclude from our study [52] that the usage of customized allogenic bone blocks may represent a promising and successful treatment approach also for the augmentation of severely resorbed mandibles. The wound closure occurs tension-free and membrane exposures can be avoided [52].

Thus, the utilization of allogenic bone blocks as possible alternative to autologous bone has shown promising results so far in alveolar ridge reconstruction and even in severely deficient bone in the aesthetic zone [51,52]. Nevertheless, long-term studies are still lacking and literature which covers that topic is still rare, especially concerning long-term experiences with the allogenic bone blocks. Especially long-term data for the use of allogenic bone blocks in mandible reconstructions need to be further researched [52].

In one of our recent studies, a method for the assessment of volumetric changes of the bone block during the healing period was introduced [61]. Goal of that study was to present a method, which allows the assessment of the volumetric changes of the allogenic

bone blocks. We investigated the practicability of this method by analyzing the resorption of the allogenic bone block for reconstruction of a severe and complex maxillary defect. Therefore, we recorded cone-beam computed tomography (CBCT) scans of a nineteen year old male patient who was treated with allogenic bone block. We recorded CBCT-scans before and post-operation. Furthermore, a CBCT-scan was taken six months after healing. To assess graft shrinking, we used two image matching tools (coDiagnostiX® and Slicer). Further, we harvested a biopsy specimen along the implant canal at the timepoint of the implantation. Our findings showed that the bone defect could be successfully restored. We found advanced graft remodeling. Histo-morphometric and histologic analysis confirmed that graft remodeling had been taken place. We could find initial volumes of the graft of 0,373 ml (coDiagnostiX) and 0,370 ml (Slicer), respectively. We found a graft resorption of 0,011 ml, which corresponds to 3 % and 0,016 ml (4,33 %) after six months of healing [61].

However, before graft materials can be considered as save and effective, we must understand their clinical performance. Hereby, resorption stability is a crucial aspect. Our case study presented a limited resorption of the allogenic bone block and showed the practicability of this measurement method [61].

The study of Kloss et al. (2020) [57] analyzed the long-term outcomes of CAD/CAM allogenic bone blocks in their case report. The authors came to the result, that the CAD/CAM allogenic bone blocks may represent a successful approach to alveolar ridge augmentation in large and complicated bone defects. Kloss et al. (2020) showed histological and radiographic outcomes of CAD/CAM customized allogenic bone blocks after a 5-year follow-up period. The patient in the case report of Kloss et al. (2020) [57] was followed up for 5-years. The authors could demonstrate that there were no signs of infection, block graft exposure, post-surgery complications or wound healing problems. It was also shown that the allogenic bone block integrated well into the recipient site and remained stable for the 5-years follow up period. No prosthesis loss could be found either after the 5-year follow-up period and there were no bleeding complications. Kloss et al. (2020) could observe only a slight recession of the peri-implant mucosa but there were no signs of peri-implantitis or mucositis.

In addition Schlee et al. (2013) [56] carried out a case report study to evaluate the handling and healing patterns of customized allogenic bone blocks. The study was carried out with

two patients with three combined mandibular defects, horizontal, as well as vertical. Computer designed allogenic bone blocks were used as bone grafts. The patients were examined pre- and post-surgery by computer tomography (CT) scans. Further, clinical and radiographic examinations were carried out 6 and 12 months after surgery. Only a partial exposure of one bone block could be observed after 8 weeks in one patient, there were no other complications. Histological examination showed the formation of new bone in the augmentation areas. Patient satisfaction was good and long-term stability parameters were considered as excellent. Schlee et al. (2013) came to the conclusion that CAD allografts support the formation of new bone in the augmented area. Time for surgery was decreased compared to conventional bone grafting methods and patient acceptance was high.

The study of Otto et al. (2017) [48] investigated custom-milled cancellous bone block allografts in the repair of the alveolar cleft. Often, bone grafts from the iliac crest are used for osteoplasties of the cleft alveolus. The problem with those bone grafts is donor site morbidity. Therefore, Otto et al. (2017) analyzed the feasibility of custom-milled allogenic bone grafts to repair the alveolar cleft. The authors carried out a case study with a 36- year- old female patient, who was asking for an alternative for iliac crest bone grafting. Otto et al. (2017) could build up her alveolar cleft with custom-milled allogenic bone blocks (maxgraft® 80 bonebuilder). The case study of Otto et al. (2017) showed that allogenic bone blocks can facilitate alveolar cleft repair and could be an effective alternative to iliac crest bone graft [48].

One of our previous studies went even one step further than Otto et al. (2017) [48]: In this study we used a customized allogenic bone block for the augmentation and repair of an alveolar cleft and the successful insertion of dental implants [62]. Our study showed that customized allogenic bone blocks could be an alternative to iliac crest bone graft in patients with alveolar cleft. Furthermore, a successful implantation could be carried out. We observed high volumetric stability of the allogenic bone graft, further, ideal integration and revascularization, which resulted in functional bone tissue, eligible for implantation [62].

So far, several studies have shown, that customized allogenic bone blocks work as an optimal scaffold for the augmentation and repair of alveolar ridge defects. The success

rate shown in previous studies are high [43,51,52,56,57]. The computer-supported design and manufacture allows the individualization of the allogenic bone blocks which has been shown to be possible even for large and complex bone defects in the alveolar area [51-57].

Nevertheless, randomized, controlled studies with higher numbers of patients are still lacking to date.

## **2. Objectives**

### **2.1 General objective**

The general objective of this thesis was to increase the knowledge about and provide evidence for the new technology of CAD/CAM allogenic bone blocks for bone grafting. Another goal of the current study is to demonstrate the high implant survival rate, related to this new technology, as well as the success-rate of the surgical procedure. We collected data with autologous bone grafts from the literature and compared them to our patient data with the novel CAD/CAM allogenic bone block technology. We intend to show that both techniques are comparable in clinical outcomes, implant survival rates, patient morbidities and aesthetic aspects.

### **2.2 Special objective**

Even though several case reports [51-56] have shown the high success rate of CAD/CAM allogenic bone blocks for bone grafting even in complex and severe bone defects, no study with a larger number of patients has been carried out to date. The current thesis comprises a retrospective cohort study with 23 patients, receiving CAD/CAM allogenic bone blocks for alveolar bone grafting in the aesthetic zone of the maxilla. The current study aims to:

- 1) Provide evidence for the usability of CAD/CAM allogenic bone blocks
- 2) Analyze the clinical outcomes in patients with severe bone defects receiving bone grafting with CAD/CAM allogenic bone blocks
- 3) Investigate possible complications and drawbacks of the method of bone grafting with CAD/CAM allogenic bone blocks
- 4) Analyze the complication rates of this new technology and compare them to the complications in autologous bone grafting in the literature

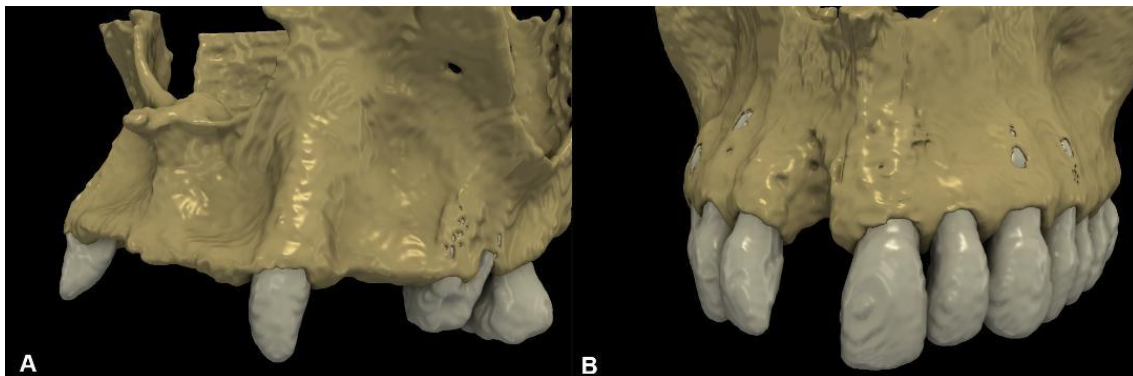- 5) Analyze the advantages of the CAD/CAM allogenic bone block technology and compare them to those of autologous bone grafting from the literature
- 6) Introduce this new technology on a large scale
- 7) Introducing a new digital technology to monitor volume changes in transplants during the healing process
- 8) Additionally, a newly developed remote incision technique is presented. This technique is meant to avoid wound dehiscence

### 3. Materials and methods

#### 3.1 Sources and collection of data

##### 3.1.1 General study design

Based on the data analysis of digital volume-tomography (DVT), 23 patients, who had severe bone defects in the region 13-23 could be reconstructed with computer-designed allogenic bone blocks.



**Figure 6.** Examples of bone defects in the aesthetic zone. (Source: Blume 2023 [68])

*A: 3D reconstruction of an alveolar ridge defect at a multiple-tooth gap*

*B: 3D reconstruction of an alveolar ridge defect at a single-tooth gap*

Patient data was collected in our Institute of Dres. Back and Blume, private practice and clinic for maxillo-, facial- and oral surgery in Munich, Germany. The participation in the study was not associated with further surgical interventions or with high risk of morbidity. We collected the data from patients we had treated in our private practice from their digital case histories. The medical histories of the patients were, therefore, already known age, gender, substance abuse, co-morbidities and prescribed medications. Each patient was educated in detail about the surgical procedure with the CAD/CAM-technology as

well as about other, alternative methods of treatment, eventually each patient in the current study gave consent and is therefore, the free will of each patient in the current study.

The following parameters were collected carrying out the current monocentric retrospective study:

- 1) Patients age
- 2) Patients gender
- 3) Location and geometry of the bone defect
- 4) Clinical diagnosis
- 5) Type of bone defect
- 6) The reason why the bone defect has occurred
- 7) Type of allograft and manufacturer
- 8) Post operative complications
- 9) Wound healing parameters
- 10) Extent of new bone growth (in ml)
- 11) Implant health and stability
- 12) Patient satisfaction

The programs coDiagnostiX (digital planning software coDiagnostiX, version 10.2.0.15659, Dental Wings Inc., Montreal, Canada) and Slicer (an open-source medical image processing software platform, 3D Slicer, [www.slicer.org](http://www.slicer.org)) were used to take the measurements of the area of the bone defect on different time points:

T1: before bone grafting

T2: 2 months after the insertion of the bone graft

T3: 6 months follow-up

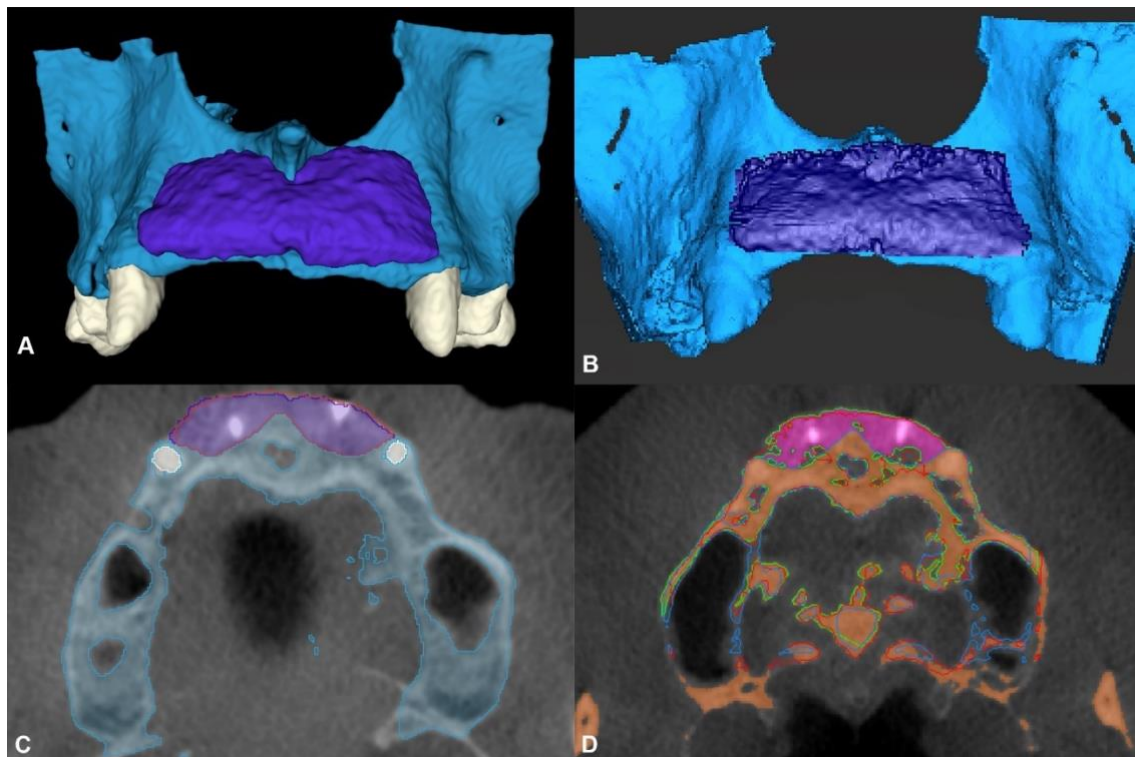
Our goal was to measure the three-dimensional bone gain after bone grafting and healing. Therefore, the volume of the bone graft was measured at T1 and T2 and the difference between those values was calculated. Additionally, volumetric changes of the bone blocks during the healing process were examined and analyzed. Additionally, we analyzed the



average survival time of the bone blocks as well as the implant success rate. The data was plotted and analyzed by Kaplan Meier plot.

Complications like membrane exposition, soft tissue dehiscence, bone block exposure or exposure of the osteosynthesis screws were documented and statistically analyzed and correlation with health status of the patient, gender, age, nicotine abuse or drug intake was calculated. Measurements were performed with the semi-automatic segmentation (SA) method (Slicer) and with the global thresholding segmentation (GT) method (coDiagnostiX).

Volumetric hard tissue changes were evaluated with two different radiographic methods by two independent examiners. The primary evaluation method utilized semi-automatic segmentation (SA) methods to acquire 3D virtual models of Cone-beam computed tomography (CBCT) datasets whereas in the second evaluation method a global thresholding segmentation (GT) method was utilized for the same reason.



**Figure 7.** 3D model from the implanted bone block. (Source: Blume 2023 [68])

*A, C: 3D model and axial view acquired via semi-automatic segmentation (blue: baseline alveolar ridge, purple: hard-tissue gain at the 6-month follow-up)*

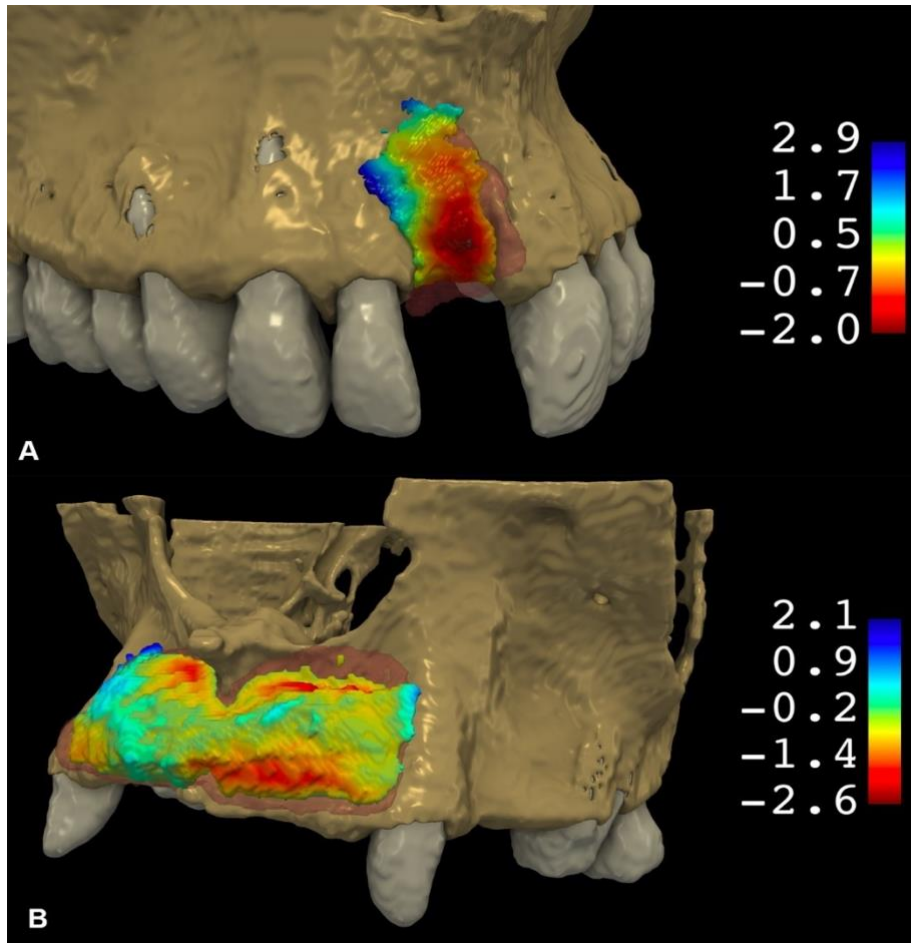
*B, D: 3D model and axial view acquired via global thresholding segmentation (blue: baseline alveolar ridge, purple: hard-tissue gain at the 6-month follow-up)*

### **3.1.2 Semi-automatic segmentation method (SA)**

The open-source medical image processing software platform (3D Slicer, [www.slicer.org](http://www.slicer.org)) was used to reconstruct T1, T2 and T3 CBCT images as 3D virtual models. After performing an image segmentation of the CBCT scans, automatic voxel intensity-based registration was done. To analyze the hard tissue changes between the different timepoints, logical operators were used to subtract the aligned 3D models from one another. Then, 3D models of the new hard tissues at T2 and T3 timepoints could be created. Furthermore, we could calculate the dice similarity coefficient (DSC) to determine the spatial overlap between the created models. The DSC metric provides information on how well the implanted bone block retained its original shape.

### **3.1.3 Global thresholding segmentation method (GT)**

In the GT method, the three-dimensional models of the CBCT scans at each time point could be automatically acquired with the coDiagnostiX software package. The CBCT scans at each timepoint were aligned, thereby, the software mathematically calculated the volumetric differences between the 3D models. We calculated the volume stability of the allogenic bone block by taking the ratio of T3/T2 in percent. This was carried out in both of the models used, as shown in the figure below:



**Figure 8.** Three-dimensional morphological alterations between T2 and T3 visualized via a 3D colormap analysis. (Source: Blume 2023 [68])

*A: 3D hard-tissue alterations between T2 and T3 at a single-tooth gap*

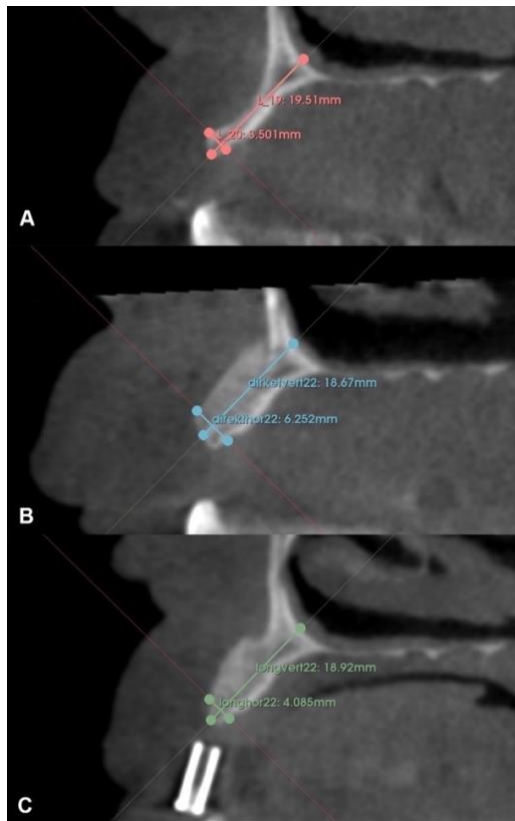
*B: 3D hard-tissue alterations between T2 and T3 at a multiple-tooth gap*

(red: hard-tissue loss, blue: hard-tissue gain)

### 3.1.4 Linear measurements

As seen in the figure below, the implant positions at T3 CBCT scans were marked by radiopaque radiographic markers. At the future implantation sites absolute horizontal- and vertical linear dimensions were marked at each timepoint in 3D slicer.

The datasets of the CBCT scans were reoriented so that the coronal plane became parallel. Furthermore, the reorientation resulted in the axial plane becoming perpendicular to the long axis of the edentulous ridge. As depicted in the figure below, a vertical linear dimension of the alveolar ridge was measured. This was done from the midcrestal point along the long axis of the alveolar ridge to the base of the nasal cavity. The horizontal lines were measured 2 mm apical to the alveolar crest at the same aspect perpendicular to the long axis of the alveolar ridge. This was done between the palatal and the buccal cortical plate, as depicted in the figure below.



**Figure 9.** Linear measurements. (Source: Blume 2023 [68])

### 3.2 Patient demographics

We carried out a monocentric study at the Institute of Dres. Back and Blume, private practice and clinic for maxillo-, facial- and oral surgery in Munich, Germany. In this retrospective study we analyzed the clinical and radiological data of 23 patients, who had received bone grafting in the maxilla. Goal of the current study was the evaluation whether alveolar bone defects can be treated with a cancellous customized allogenic bone block (maxgraft bone builder®, Botiss Biomaterials GmbH, Zossen, Germany). We only included patients who had severe bone defects in the aesthetic zone in the region 13-23, which could be reconstructed with computer-designed allogenic bone blocks. Hereby, the patients were divided into two groups: Group A and group B. In group A 13 patients with single tooth gap were included. Group B consisted of 10 patients with a multiple tooth gap.

The inclusion criteria were:

- Age over 18 years
- Severe three-dimensional bone defect of the upper jaw in the aesthetic zone
- Medical indication for bone grafting
- Treated by only one surgeon medical indication of an implant
- Signed the letter of consent
- No serious previous illness (e.g. cancer)
- The patient is currently not undergoing radiation therapy
- The patient is not taking bisphosphonates

The exclusion criteria for the current study were:

- Age under 18 years old
- Medication with bisphosphonates

- Tumor disease
- The patient is currently undergoing radiation therapy
- Diabetes
- Hypertension
- Other serious health problems (e.g. bleeding disorder, malignant tumor)

All patient data were recorded personally and pseudo-anonymized before data analysis. Every patient data received a three-digit code. In order to participate in the current study, patients had to give their consent after a detailed patient education about the risks and benefits.

The patients in the current study were treated with a customized CAD/CAM allogenic bone block between 2017 and 2020.

The study was approved by the local ethical committee (Ethical Committee Ludwig-Maximilians-University Munich, Germany; Approval Number: 18-898). A signed informed consent was acquired from all the patients.

### **3.3 CAD/CAM customization**

For the manufacturing of the CAD/CAM allogenic bone blocks the design tool software coDiagnostiX was used. Integration of surgical and prosthetic workflows through real-time case sharing between coDiagnostiX and Dental Wings (DWOS) CAD/CAM was possible.

We obtained tomographic data from the jaws of our patients, which are essential to plan and manufacture a CAD/CAM produced allogenic bone block. Based on the tomographic data, digital models of the bone defects were simulated, which served as template for the design of the customized allogenic bone blocks. The measurements of the designed bone blocks were then programmed into a computerized bone mill, which was used to produce a rectangular, spongy bone block, according to the previously computer-designed model.

For the current study, we used the maxgraft® bonebuilder (Botiss Biomaterials GmbH, Berlin, Deutschland; number of approvals: PEI.H.11672.01.1). The product consists of human spongiosa bone, which had been approved by the Paul Ehrlich Institute in Germany, earlier. The bone blocks were covered with a resorbable collagen membrane from porcine pericardium (Jason® membrane, Botiss Biomaterials, Germany) and fixated to the jaw ridge with titanium osteosynthesis-screws (Medartis AG, Basel, Switzerland).

### **3.4 Surgical procedure**

#### **3.4.1 General procedures**

Following the surgical protocol of Choukroun for the preparation of platelet rich fibrin [66] blood was taken from the patients in order to gain platelet-rich fibrin (PRF) matrices. The patients received injections of 600 mg Clindamycin for antibiotic prophylaxis. The surgical procedure was done in general anesthesia. The incision was performed with a newly developed „semi-pillar” technique. Therefore, we did not perform the incision over the alveolar ridge, but 20 mm horizontally in the flexible mucosa. This was accompanied by a lateral relief incision. A mucoperiosteal flap was elevated from the maxillary bone. This left the mucosa still covering the defect intact. Then, we perforated the cortical layer with the help of a diamond burr. This was done to improve the integration of the bone graft.

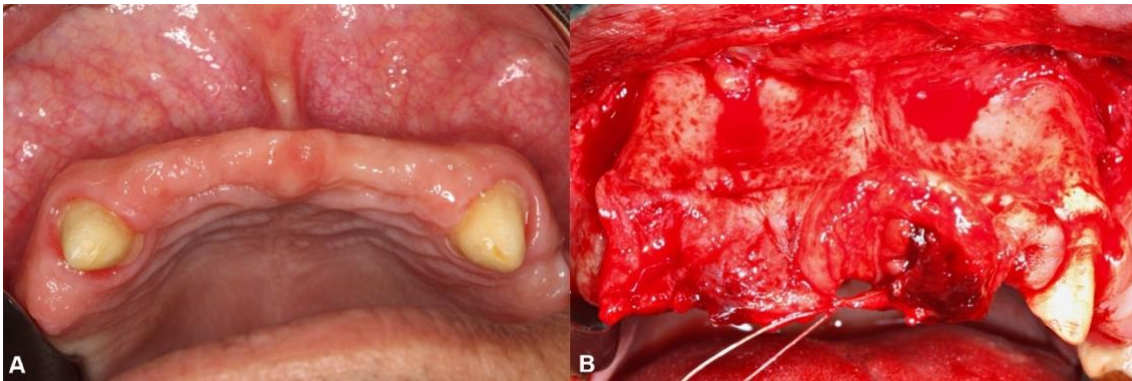
Exudate serum was utilized to rehydrate the sterile allogenic CAD/CAM bone block, otherwise no further modifications were needed. The allogenic bone block was fixated with a single titanium osteosynthesis screw of 1.5 mm diameter and 7-9 mm length (Medartis AG, Basel, Switzerland). The allogenic bone block was first covered with a resorbable collagen membrane which had been manufactured from native pericardium (Jason® membrane, Botiss Biomaterials GmbH, Zossen, Germany). We applied a PRF membrane to support the healing of the surrounding soft tissue. The flap was then sutured with a single button pulley suture, in order to get a tension free suture (Vicryl 4.0/ 5.0 Rapid®, Ethicon, Raritan, New Jersey, USA).

The patients received closed-mashed monitoring after surgery. The surgical suture was removed 14 days post-operation. After a healing period of six months, the implant was

set, this time only under local anesthetic. Through a jaw ridge incision, a mucoperiosteal flap was elevated minimal-invasively and the osteosynthesis material was removed. Then the implant was inserted. According to the recommendation of an antibiotic prophylaxis with a penicillin for the insertion of dental implants [65] the implant insertion was done under a one-shot antibiotics with 1000 mg Amoxicilline. The suture was removed 7 days post-operation. After a healing period of 3 months, healing screws were inserted.

### 3.4.2 Flap elevation

The flap preparation on the buccal aspect was carried out according to the semi-pillar incision design as shown in the figure below:



**Figure 10.** Flap elevation procedure. (Source: Blume 2023 [68])

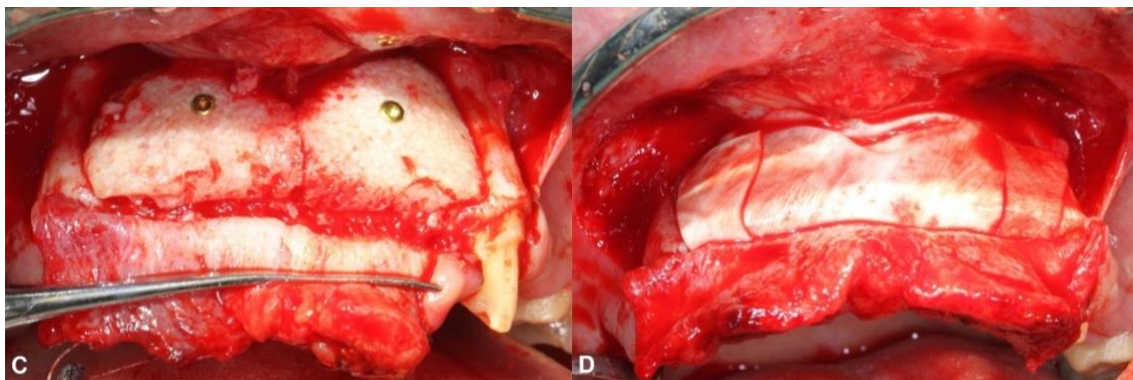
First, we made a horizontal incision on the buccal aspect within the mobile mucosa, as shown in the figure above (panel A and B). The incision was made 2 cm apically from the midcrestal line. Afterwards, we carried out a single vertical releasing incision at the distal aspect of the surgical area. Then, a unilateral full-thickness mucoperiosteal flap was elevated on the buccal aspect and the keratinized mucosa on the crestal remained intact, the palatal aspects remained attached to the bone.



### 3.4.3 Fixation of the allogenic bone block

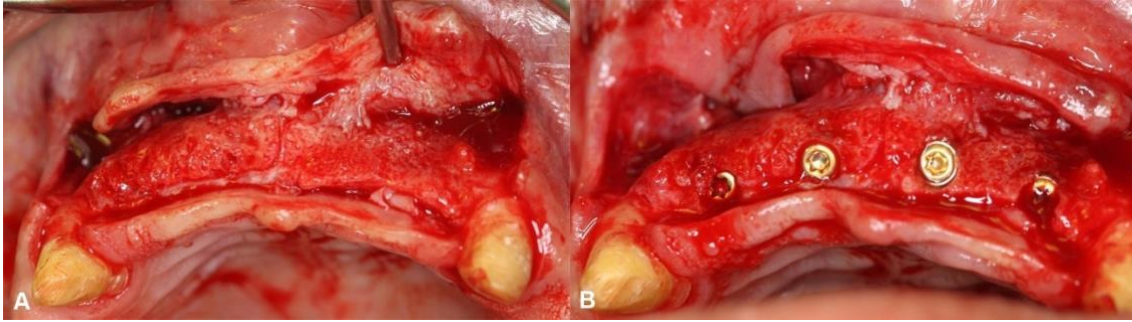
The cortical layer at the augmented site was perforated with a diamond bur. This was done prior to bone block position and to induce bleeding for an enhanced vascularization of the bone graft. Then, the allogenic bone block was inserted. No further adjustments were needed. The bone block was fixated by titanium osteosynthesis screws (Medartis AG, Basel, Switzerland), as shown in the following figure 11.

To add an additional barrier function, we covered the area with a long-term resorbable porcine pericardium membrane (Jason® membrane, Botiss Biomaterials GmbH, Zossen, Germany). Tension free wound closure achieved by using single interrupted sutures utilizing 4.0 and 5.0 resorbable suturing materials (Vicryl Rapid®, Ethicon, Raritan, New Jersey, USA). Sutures could be removed after two weeks.



**Figure 11.** Fixation of the bone block with titanium screws. (Source: Blume 2023 [68])

After a 6-month healing period guided implant placement was planned. Hard tissue augmentation was not necessary. We carried out the direct evaluation of the reconstructed alveolar ridge, removal of the block fixation screws and dental implant placement during a re-entry procedure.



**Figure 12.** Reentry after 6 months and implant placement. (Source: Blume 2023 [68])

### 3.5 Data analysis

To analyze the overall changes of the hard tissue, we used descriptive statistics. The data of 23 patients could be included in the current study. The overall changes of the hard tissue were expressed as mean standard deviation. The statistical differences were calculated with non-parametric statistical tests. The statistical differences between each time point T1-T3 for each variable was calculated by Wilcoxon matched pairs signed rank test. The differences between the variables of the groups were calculated by Mann-Whitney-U-Test. Furthermore, we used non-parametric statistical tests in order to evaluate the correlations and differences between the datasets which had been acquired by distinct evaluation methods. The statistical differences were calculated by Wilcoxon matched pairs signed rank test, correlation between the datasets was analyzed by Spearman rank order correlation. We performed all statistical calculations with the software SPSS (IBM, Armonk, USA).

## 4. Results

### 4.1 Patients and methods

In our study 23 patients, meeting our inclusion criteria were included. The patients had received bone grafting with CAD/CAM allogenic bone blocks. 14 of the 23 patients were male and 9 female. The mean age of our patients was  $45,48 \pm 12,52$  years. 10 patients presented with multiple tooth gaps and 13 patients had only a single tooth gap. 6 patients presented with two tooth gaps, 2 patients had three tooth gaps and another two patients presented four tooth gaps. No complications would be observed, neither during surgery, nor post-operative. We could not observe any wound dehiscence nor wound infections. After a healing period of six months, all patients could be undertaken to three-dimensional radiographic diagnostics (CBCT-scans). All patients met the criteria for implant insertion. According to the horizontal, vertical and combination- (HVC) ridge deficiency classification (subclassification: small (S)  $\leq 3$  mm; medium (M) 4-6 mm; large (L)  $\geq 7$  mm) 27 defects could be characterized as horizontal-large, 6 were identified as combination-large, 6 defects could be classified as combination-medium, and one defect was defined as horizontal-medium.

**Table 2.** Patient demographic data and baseline defect characteristics. (Source: Blume 2023 [68])

Participant	Sex	Age	Surgical area size	Tooth	HVC
1	F	34	2 teeth	11	CM
				21	HL
2	M	38	1 tooth	21	HL
3	M	41	1 tooth	21	HL
4	F	53	1 tooth	21	HL
5	F	42	1 tooth	11	CM

6	F	47	1 tooth	11	CL
7	M	44	2 teeth	22	HL
				21	HL
8	M	53	1 tooth	11	HL
9	F	42	4 teeth	12	HL
				11	HL
				21	CL
				22	HL
10	F	60	2 teeth	11	HL
				12	HL
11	M	55	2 teeth	12	HL
				11	HL
12	F	70	2 teeth	11	HL
				21	CM
13	F	48	1 tooth	12	HL
14	M	28	1 tooth	11	CM
15	M	72	3 teeth	12	HL
				11	HL
				21	HL
16	M	47	4 teeth	12	CL
				11	CL
				21	CL
				22	CM
17	M	55	1 tooth	21	CM
18	M	30	3 teeth	12	HL
				11	HL
				21	HL
19	M	20	1 tooth	12	HL
20	F	42	3 teeth	13	HL
				12	HL
				11	HM

21	M	32	1 tooth	11	HL
22	M	48	1 tooth	21	CL
23	M	45	1 tooth	11	HL

## 4.2 Volumetric hard tissue changes

In the current study, we could find a volumetric hard tissue gain in average of  $0.75 \text{ cm}^3 \pm 0.57 \text{ cm}^3$  measured with the semi-automatic segmentation method (SA), with a median value of  $0.49 \text{ cm}^3$ . After 6 months we detected an average hard tissue gain of  $0.52 \text{ cm}^3 \pm 0.42 \text{ cm}^3$  with a median value of  $0.37 \text{ cm}^3$  and  $0.29 \text{ cm}^3 \pm 0.12 \text{ cm}^3$ . Between the timepoints T2 and T3 we could detect a statistically significant amount of hard tissue resorption ( $p < 0.05$ ). The average volume stability of the bone block determined by the T3/T2 ratio was  $67.83\% \pm 18.72\%$  on average with a median value of  $72.46\%$  measured with the SA method.

**Table 3.** Volumetric hard tissue changes with the semi-automatic segmentation ( $n=23$ ).  
(Source: Blume 2023 [68])

	Mean $\pm$ St. Dev. <sup>1</sup>	Median	Min – Max
New volume at T2 <sup>2</sup> (cm <sup>3</sup> )	$0.75 \pm 0.57$	0.49	0.19 – 2.35
New volume at T3 <sup>3</sup> (cm <sup>3</sup> )	$0.52 \pm 0.42$	0.37	0.09 – 1.54
T3/T2 ratio (%) <sup>2</sup>	$67.83 \pm 18.72$	72.46	19.57 – 95.83
$p$ value <sup>4</sup>	< 0.05		
<i><sup>1</sup>standard deviation, <sup>2</sup>2-month follow-up, <sup>3</sup>6-month follow-up, <sup>4</sup>Wilcoxon matched pairs signed rank test</i>			

With the global thresholding method at T2 we could find an average of  $0.69 \text{ cm}^3 \pm 0.56 \text{ cm}^3$  hard tissue gain, with a median value of  $0.46 \text{ cm}^3$ . At timepoint T3 we could measure an average hard tissue gain of  $0.53 \text{ cm}^3 \pm 0.46 \text{ cm}^3$  with a median value of  $0.37 \text{ cm}^3$ . Hereby, we could detect statistically significant amount of volumetric hard tissue resorption between T2 and T3 timepoints ( $p < 0.05$ ). Using the GT- method resulted in an average volume stability of the allogenic bone blocks of  $75.50 \% \pm 13.68 \%$ , with a median value of  $72.46\%$ .

**Table 4.** Volumetric hard tissue changes with global thresholding segmentation ( $n=23$ ). (Source: Blume 2023 [68])

	Mean $\pm$ St. Dev. <sup>1</sup>	Median	Min - Max
New volume at T2 <sup>2</sup> ( $\text{cm}^3$ )	$0.69 \pm 0.56$	0.46	0.19 - 2.24
New volume at T3 <sup>3</sup> ( $\text{cm}^3$ )	$0.53 \pm 0.46$	0.37	0.11 - 2.05
T3/T2 ratio (%)	$75.50 \pm 13.68$	76.47%	46.15 - 97.87
$p$ value <sup>4</sup>	< 0.05		
<i><sup>1</sup>standard deviation, <sup>2</sup>2-month follow-up, <sup>3</sup>6-month follow-up, <sup>4</sup>Wilcoxon matched pairs signed rank test between (significance level: <math>p &lt; 0.05</math>) “New volume at T2” and “New volume at T3”</i>			

Comparing the resulting data of the two segmentation methods at T2, a statistically significant difference could be detected with the Wilcoxon matched pairs signed rank test ( $p = 0.009$ ), although high level of correlation could be detected between the two metrics at (Spearman correlation coefficient: 0.95). On the other hand regarding the volumetric hard tissue gain at T3 ( $p = 0.89$ ) there was no statistically significant difference between

the semi-automatic- and the global thresholding segmentation method. High levels of correlation were also found between the two datasets regarding this metric (Spearman correlation coefficient: 0.91).

**Table 5.** Comparison of results acquired with the semi-automatic segmentation and the global thresholding segmentation methods ( $n=23$ ). (Source: Blume 2023 [68])

	Semi-automatic segmentation		Global thresholding segmentation		$p$ value <sup>2</sup>	Spearman Correlation coefficient
	Mean $\pm$ St. dev. <sup>1</sup>	Median	Mean $\pm$ St. dev.	Median		
New volume at T2 <sup>3</sup> (cm <sup>3</sup> )	0.75 $\pm$ 0.57	0.49	0.69 $\pm$ 0.56	0.46	= 0.009	0.95
New volume at T3 <sup>4</sup> (cm <sup>3</sup> )	0.52 $\pm$ 0.42	0.37	0.53 $\pm$ 0.46	0.37	= 0.89	0.91
<sup>1</sup> standard deviation, <sup>2</sup> Wilcoxon matched pairs signed rank test (significance level: $p < 0.05$ ), <sup>3</sup> 2-month follow-up, <sup>4</sup> 6-month follow-up						

### 4.3 Linear hard tissue measurements

In the current study we performed linear measurements at 40 future implantation sites. At T1 the baseline vertical alveolar ridge dimensions at the planned implant position resulted in an average of 15.45 mm  $\pm$  3.32 mm and 3.30 mm  $\pm$  1.04 mm in the horizontal dimension. At T2 the average linear vertical dimension at future implantation sites averaged at 17.60 mm  $\pm$  2.82, horizontal ridge dimensions were measured at an average of 7.85 mm  $\pm$  1.14 mm. At T3 vertical- and horizontal ridge dimensions averaged at 16.97

mm  $\pm$  2.86 mm and 6.43 mm  $\pm$  1.27 mm respectively. Statistically significant differences were recorded between all the metrics. Resulting in a statistically significant vertical- and horizontal linear gain between T1 and both follow-up timepoints (T2 and T3). Simultaneously a statistically significant linear hard tissue loss could be detected between T2 and T3. The data is summarized in the following table below:

**Table 6.** Vertical linear dimension at future implant positions ( $n=40$ ). (Source: Blume 2023 [68])

	Mean $\pm$ St. Dev. <sup>1</sup>	Median	Min - Max
Vertical dimension T1 <sup>2</sup> (mm)	15.45 $\pm$ 3.32	15.15	9.06 - 21.95
Vertical dimension T2 <sup>3</sup> (mm)	17.60 $\pm$ 2.82	18.22	11.34 - 21.53
Vertical dimension T3 <sup>4</sup> (mm)	16.97 $\pm$ 2.86	17.53	12.02 - 21.42
$p$ value <sup>5</sup> (T1 - T2)	< 0.05		
$p$ value <sup>5</sup> (T2 - T3)	< 0.05		
$p$ value <sup>5</sup> (T1 - T3)	< 0.05		
<i><sup>1</sup>standard deviation, <sup>2</sup>baseline, <sup>3</sup>2-month follow-up, <sup>4</sup>6-month follow-up, <sup>5</sup>Wilcoxon matched pairs signed rank test (significance level: <math>p &lt; 0.05</math>)</i>			

**Table 7.** Horizontal linear dimension at future positions ( $n=40$ ). (Source: Blume 2023 [68])

	Mean $\pm$ St. Dev. <sup>1</sup>	Median	Min - Max
Horizontal dimension T1 <sup>2</sup> (mm)	3.30 $\pm$ 1.04	3.32	1.49 - 6.43



Horizontal dimension T2 <sup>3</sup> (mm)	7.85 ± 1.14	7.61	5.93 - 10.32
Horizontal dimension T3 <sup>4</sup> (mm)	6.43 ± 1.27	6.53	3.61 - 9.33
<i>p</i> value <sup>5</sup> (T1 - T2)	< 0.05		
<i>p</i> value <sup>5</sup> (T2 - T3)	< 0.05		
<i>p</i> value <sup>5</sup> (T1 - T3)	< 0.05		
<i><sup>1</sup>standard deviation, <sup>2</sup>baseline, <sup>3</sup>2-month follow-up, <sup>4</sup>6-month follow-up, <sup>5</sup>Wilcoxon matched pairs signed rank test (significance level: <i>p</i>&lt;0.05)</i>			

#### 4.4 Effect of surgical size on clinical outcomes

We compared the results of alveolar ridge augmentation at single- and multi-tooth gaps. Hereby, we calculated the differences in linear hard tissue dimensions at T2 and T3 and the differences in DSC values and volumetric stability (T2/T3 ratio). The table below shows the comparison between the alveolar ridge augmentation in patients with single- and multiple tooth gaps. It can be seen in the table above, that one of the linear measurements at any timepoint showed statistically significant differences (*p*>0.05). We found slightly higher DSC values and graft stability at larger augmentations sites, in group B compared to group A, however, the differences were statistically not significant (*p*>0.05).

**Table 8.** Comparison between single- and multiple tooth gaps. (Source: Blume 2023 [68])

Variables	Single tooth gap (Group A)	Multi tooth gap (Group B)	<i>p</i> -value
Volume stability SA/GT (%)	62.53 ± 22.75/ 73.61 ± 16.76	74.71 ± 8.56/ 77.95 ± 8.75	0.12/ 0.46
Dice similarity coefficient	0.68 ± 0.18	0.80 ± 0.05	0.08

Vertical dimension T1 (mm)	16.44 ± 2.99	14.97 ± 2.13	0.28
Vertical dimension T2 (mm)	18.71 ± 1.87	17.06 ± 2.49	0.14
Vertical dimension T3 (mm)	18.15 ± 2.44	16.40 ± 2.26	0.09
Horizontal dimension T1 (mm)	3.15 ± 0.96	3.36 ± 1.22	0.53
Horizontal dimension T2 (mm)	8.07 ± 1.04	7.75 ± 1.30	0.32
Horizontal dimension T3 (mm)	6.53 ± 1.61	5.98 ± 9.90	0.82

#### 4.5 Implant stability

All of our 23 patients were eligible for implant insertion after a six month healing period. No further augmentation was necessary. Altogether, 39 implantations were carried out, shown in the following table:

**Table 9.** Implant insertion. (Source: own work)

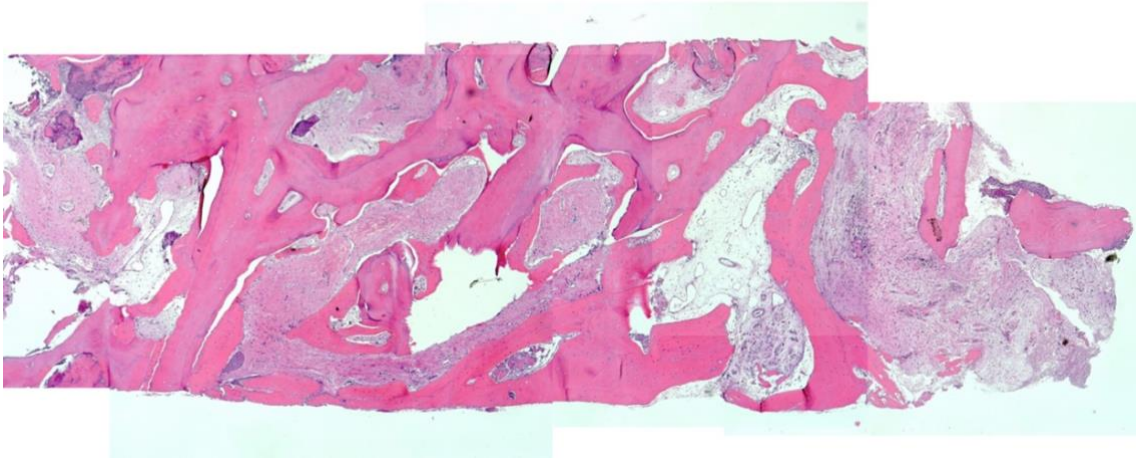
Number of implants	39
Number of patients (n)	23
Implant regions	13-22
Implanttype	
ITI	18
Nobel Active	8
Camlog	7

Conelog	3
Xive	2
Astra	1
Primary stability (Ncm)	34,26 ± 11,42
MIN - MAX	15 - 50

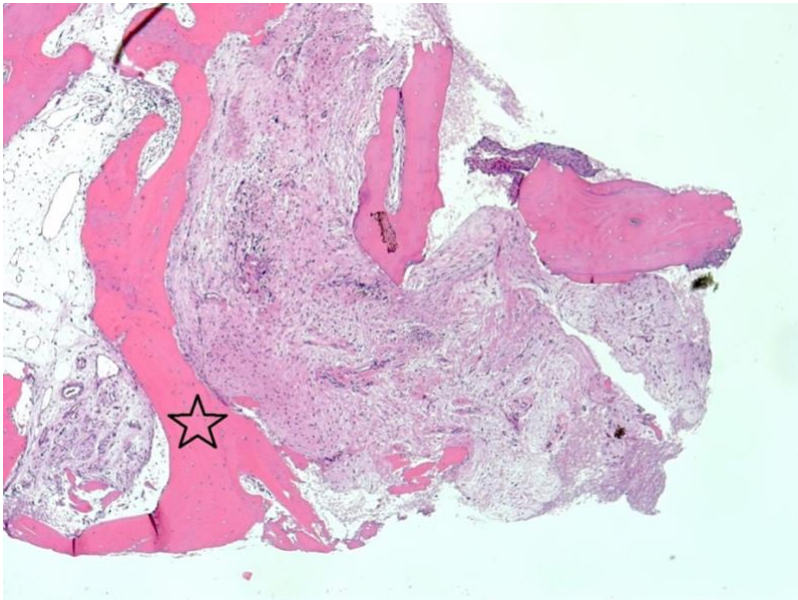
The primary stability of the implants (Ncm) was in average 34.26, with a standard deviation of 11.42. The implants were all carried out in the regions 13-22. We used different implant types. Mostly we used ITI 18, Nobel Active was used on 8 implant sites, Camlog on 7 sites, Conelog on 3 sites. On 2 implant sites Xive was utilized and on 1 site Astra. Implant stability ranged from 15 to 50 Ncm. Among the 39 implants we could not observe any complication, all implants could be successfully inserted. After a healing period of 3 months, we examined the implants and a final CBTC-scan was taken. We could not observe any pathological tissue- or bone changes. No wound infections had occurred. No patient had suffered any complications.

#### **4.6 Histological findings**

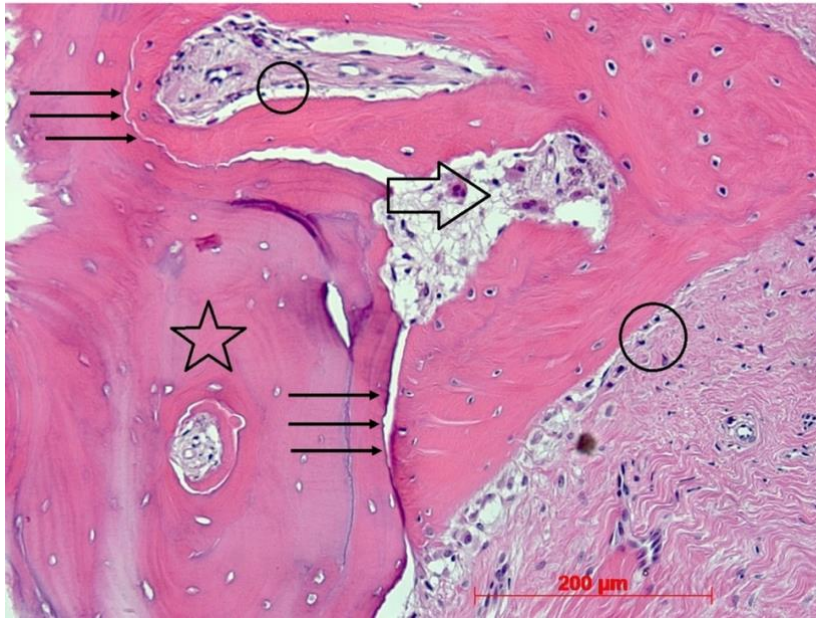We furthermore, carried out a histological analysis of a framework of allogenic cancellous bone. Hereby, we could observe trabeculae of varying thickness from lamellar bone with empty osteocyte cavities. We also saw attached peritrabecular direct ossification of varying width from woven bone with occasional (crestal) initial remodeling in lamellar bone. Crestal transverse trabecula of newly formed bone, covered by tight connective tissue (propria) with loose infiltrates and allogenic bone fragments could be observed. Furthermore, we could find fragmented multi-layered squamous epithelium, partly adherent to bone fragments, as shown in the figures below (figure 13).



A



B



C

**Figure 13.** Results of the histological analysis. (Source: own work)

In the figure above on panel (A) an overview of the histological cut, left = apical, right = crestal can be seen. Panel (B) shows newly formed bone trabecula (star). Panel (C) represents osteogenesis on allogenic block (star), osteoblasts (circle), osteoclasts (open arrow), transition zone between allogenic block and newly formed bone (arrows).

We found as preliminary diagnosis an advanced osteogenesis on the allogenic block. Also signs of remodeling could be detected. We further observed in our analysis crestal mucosal remnants and a slight inflammatory reaction crestal. Overall, our histological analysis showed active remodeling and osseointegration in progress. The osseointegration of the allogenic bone block took place in all dimensions. A histomorphometric analysis showed newly formed bone tissue within the specimen at an average of 41,5 % of residual augmentation material of 29,2 % as well as soft tissue of 29,3 %.

## 4.7 One-year follow-up examination

### 4.7.1 Patient satisfaction

Twelve patients showed up for a follow-up examination at least one-year post-implantation. The patients were examined clinically and radiologically. In total, 22 implants could be examined. We carried out a survey among the patients who were present for follow-up examinations. The patients had to rate, how satisfied they were with their new implants and the procedure. Thereby, on a scale from 1 to 10 they rated their personal satisfaction, while 1 stood for “unsatisfactory” and 10 “very satisfied”.

**Table 10.** Patient satisfaction. (Source: own work)

Number of implants	22
Number of patients ( <i>n</i> )	12
Patient satisfaction*	10 ± 1
Min - Max	8 - 10
*1 = not satisfied; 10 = very satisfied	

As the table above shows, patients were highly satisfied with the procedure and their implants. We found an average rating of 10, with a standard deviation of 1. The ratings ranged from 8 to 10. Our results, thus, show a very high patient satisfaction.

### 4.7.2 Clinical findings

The 12 patients with 22 implants were undertaken a clinical and radiological examination.

**Table 11.** Results from one-year-follow-up clinical examinations. (Source: own work)

Number of implants	22
Number of patients	12
Implant regions	13-22
Type of implant	
ITI	54,5 % (12)
Camlog	18,2% (4)
Conelog	13,6 % (3)
Nobel Active	13,6 % (3)
Primary stability (Ncm)	31,59 ± 10,01
Min - Max	20 - 50
Days between surgery and examination	1175 ± 531
Min - Max	358 - 2313
Pain	0
Pus	0
Mobility	0
Dull knocking sound	0
Plaqueindex on the implant*	35,61 ± 42,51 %
Min - Max	0 – 100 %
* Average taken from 6 measurements (mesio-, medial-, disto- oral and –vestibular each); Plaque/ no Plaque	
BOP on implant*	7,58 ± 9,93 %
Min - Max	0 – 33 %
* Average taken from 6 measurements (mesio-, medial-, disto- oral and vestibular each); BOP+ oder BOP-	

Gingiva index* on implant**	
0	68,2 % (15)
1	22,7 % (5)
2	9,1 % (2)
** Maximal value from 6 measurements (mesio-, medial-, disto- oral and vestibular)	
Probing depth on implant*	3,0 ± 1,0 mm
Min - Max	2 – 6 mm
* <i>Maximal value from 6 measurements (mesio-, medial- disto- oral and vestibular each)</i>	
Recession on implant*	0,1 ± 0,3 mm
Min - Max	0 – 1 mm
* <i>Maximal value from 6 measurements (mesio-, medial- disto- oral and vestibular each)</i>	

After a time period of one year (days between surgery and examination: 1175 ± 531) we could find a primary stability of the implant of 31,59 Ncm ± 10,01, while implant stabilities ranged from minimum 20 Ncm to maximum 50 Ncm. None of the patients reported pain, dull knocking sounds of the implants, infection or loosening of the implant. Average plaque index was 35,61 ± 42,51 %. In 15 of the 22 implants, we found an average gingiva index of 68,2 %. Recession on the implant side was low: We detected in average 0,1 ± 0,3 mm. The table above shows successful bone graft and implantation, with no complications, no pain and no infections.

#### **4.7.3 Radiographical findings**

The 12 patients with 22 implants underwent a radiological examination as well.

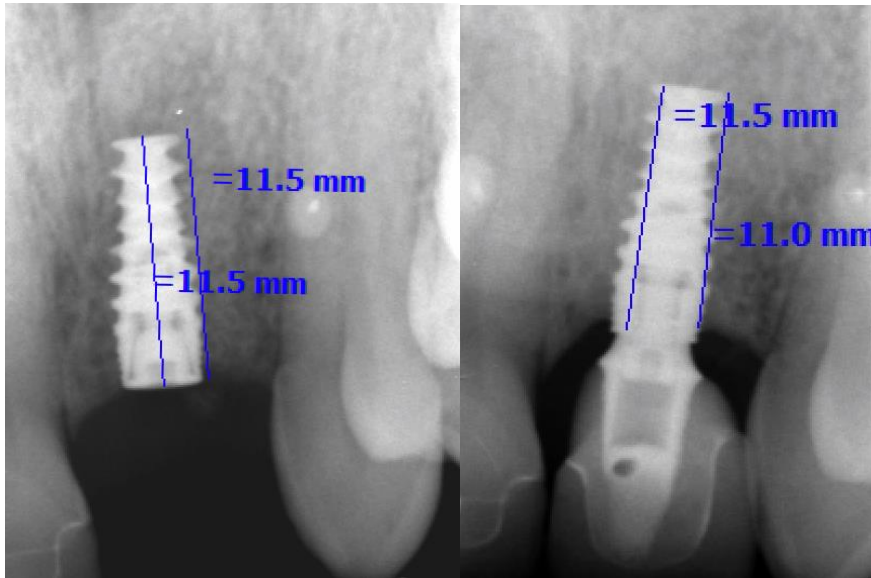


**Table 12.** Results of radiological follow-up examination. (Source: own work)

Loss of bone radiologically detected		
In mm	$0,5 \pm 0,5$ mm	$0,4 \pm 0,4$ mm
Min - Max	0,0 – 1,6 mm	0,0 – 1,4 mm
In %	$4,9 \pm 4,6$ %	$4,1 \pm 3,6$ %
Min - Max	0,0 – 16,0 %	0,0 – 14,0 %

Radiographical data were analyzed by the program CLINIVIEW (Version 4.2.2) and VixWinPro (Version 1.5f). Analogue pictures from the implant sites were digitalized, using a digital camera (Canon Eos 7D). Then, the height of the marginal bone level mesial and distal of the implant were measured, as shown in the figure below. In order to analyze three dimensional scans, we used the program iCATVision and eXam Vision (Version 19.3.13). To assure comparability of the pictures, we reconstructed two-dimensional pictures, according to orthopantomogram. We measured the heights of the marginal bone level from the tip of the implant mesial and distal, along the dental arch. We calculated the difference between the marginal bone level on the postoperative scans and the one-year follow-up scans. As seen in the table above, we could find a loss of bone of  $0,5 \pm 0,5$  mm and  $0,4 \pm 0,4$  mm respectively. The maximum bone loss, we detected was 1,6 mm.

The following figure shows the calculation of bone loss:



**Figure 14.** Calculation of bone loss. (Source: own work)

The figure shows the difference between marginal bone level post-surgery (left) and at one-year follow up (right). As it can be seen in the figure on the left, bone level was 11,5 mm post-surgery and 11 mm after one year, which results in a maximal bone loss of 0,5 mm. The percentages of maximal bone losses – calculated in % of the implant lengths are shown in the table above. Our findings indicate a low percentage of bone loss in patients with CAD/CAM customized bone blocks, following implant insertion.

## 5. Discussion

To date, the treatment of severe and complex bone defects has remained a challenge in oral surgery. In some cases, there are not only functional aspects which have to be considered, but also aesthetic ones. In complex bone defects of the alveolar ridge of the maxilla both aspects are of crucial importance. With autologous bone grafts the options are still limited, due to donor side morbidity, limited amount of autologous bone which can be harvested [23,45,46].

Due to the limitations in autologous bone grafting, customized CAD/CAM allogenic bone grafting had become an acceptable alternative for several indications [48,51-53,62].

In previous studies with CAD/CAM customized allogenic bone blocks, we could detect a low rate of complications and a significantly reduced surgical time compared to iliac crest autologous bone grafting [48,53,54,62]. Furthermore, the studies have shown a significant lowered risk of infection compared to autologous bone grafts [48,53,54]. Previous studies [48,51,52,62] have shown as well that customized allogenic bone blocks bear many advantages: They have been shown to be suitable for the precise fit and augmentation of complex bone defects. CAD/CAM technology enables the reduction of the space between the residual bone and the allogenic bone graft to a minimum. The physical contact between the customized CAD/CAM allogenic bone block and the residual bone can be achieved and enhanced which leads to an early revascularization [48, 51-53].

In one previous study [62] we successfully reconstructed the alveolar cleft of a patient with cleft lip and palate, using customized CAD/CAM allogenic bone blocks. Similar to the case study of Otto et al. (2017) [48], we succeeded to reconstruct the severe and complex bone defect, but also showed that an implant insertion after bone reconstruction can be successfully achieved. To date, most cases of osteoplasties are still carried out with autologous bone grafts [48,62].

The objective of our current study was to use customized CAD/CAM allogenic bone blocks in patients with severe defects in the maxillary bone, the aesthetic zone. In the current study, 23 patients were included. The bone defects were in the upper anterior region (13-22), thus, in the aesthetic zone, which posed the double challenge of 1)

functionally and 2) aesthetically restore the defective bone, so that tooth implants could be successfully inserted. Our patients had either single- or multiple tooth gaps.

Besides the bone blocks, we used a new incision technique in order to minimize the risk of wound infection, wound dehiscence and thus, reduce recipient site morbidity. This new incision technique, the so called “semi-pillar” technique, was introduced in one of our previous studies [51].

In the “semi-pillar” technique we do not perform the incision over the alveolar ridge. Instead, the incision is made 20 mm horizontally in the flexible mucosa. A relief incision was additionally made laterally. The mucoperiosteal flap could then be elevated from the maxillary bone. With this new flap design the incision can be relocated into the vestibulum [51]. The keratinized mucosa and the alveolar ridge could be still left intact and wound closure occurred tension-free. This incision technique was accompanied by low complication rates and no wound infections [51]. Our current results confirm our previous findings [51].

After a time period of six months we had observed optimal integration of the allogenic bone blocks and the reentry showed the formation of new, vital bone. All 23 patients met the criteria to be eligible for implantation after a healing period of six months.

In the current study, the alveolar ridge defects were categorized into two groups, according to the size of the surgical area. Patient group A had single tooth defects, while group B had multiple teeth missing. We performed volumetric and radiographic assessments with two distinct methods, as described in chapter 3. We observed that the two evaluation methods showed high correlation, there was no statistically significant difference for any of the measures. The GT method resulted in higher percentages of volume stability. This can be due to the fact that in the GT method the algorithm automatically labels voxels that fall in the threshold range. Furthermore, anatomical features cannot be recognized by the GT method. Nor can be artifacts on the CBCT scans. In contrast, with the SA method the input data for region growing and watershed segmentation algorithms are generated manually. Nevertheless, we found both methods to be feasible for the volumetric evaluation of hard tissue changes. We could validate new average volume gain at T2 of  $0.75 \text{ cm}^3 / 0.69 \text{ cm}^3$  (SA/GT) which reduced to  $0.52 \text{ cm}^3 / 0.37 \text{ cm}^3$  (SA/GT) at T3. The detected average resorption rate measured with the SA-method was with 32% slightly higher than the average resorption rate of 25% measured

with GT method. These resorption rates are similar to previously reported data on cancellous allogenic bone blocks – approximately 29% [64].

Like wise to the volumetric data, a linear vertical and horizontal hard-tissue gain between T1/ T2 (vertical: 2,15mm, horizontal: 4,55mm) and a significant resorption between T2/T3 was detected (vertical: 0,63mm, horizontal: 1,42mm) in the current investigation. In the study by Wang et al.(2002), horizontal resorption of the corticocancellous allogenic graft averaged at 2,28 mm, and vertical hard-tissue dimension loss averaged at 1,77 mm. The implanted customized CAD/CAM allogenic bone blocks in our study presented similar or less dimensional loss than did those documented in the studies by Tresguerres et al. (2019) and Wang et al.(2002) [63, 64]. The results we obtained from the current study are at least in line with the previous literature showing a high-volume stability [48,50-53].

However, we could not find statistically significant differences in volumetric- and linear hard tissue alteration, volumetric graft stability and DSC values between alveolar ridge defects in patients with single- and multiple tooth gaps. Although we found a lower volumetric- and linear hard tissue resorption in larger surgical areas, the difference to smaller surgical areas, was not statistically significant. The size of the surgical area therefore seems to have no influence on the clinical outcomes.

In the current study, we investigated a framework of allogenic cancellous bone histologically and trabeculae of varying thickness from lamellar bone with empty osteocyte cavities. Furthermore, we observed direct ossification of varying widths. This included woven bone with initial remodeling into lamellar bone. Trabecula of newly formed bone, covered by tight connective tissue and allogenic bone fragments could be observed. Thus, our histological results confirm our radiological findings and further support the clinical data. Guided bone regeneration with CAD/CAM allogenic bone blocks seem to lead to effective formation of new bone tissue and bone regeneration. Further, our histological findings support the findings of previous studies, which showed that cancellous CAD/CAM manufactured allogenic bone blocks can be reliably used for reconstruction of severely atrophied bone and complex bone defects [48,49,51,52, 62].

Our previous study [62] demonstrated high volume stability of the allogenic bone block, providing optimal conditions for implantations. Our case study (Blume et al. 2019) [62] showed ideal integration and high revascularization, resulting in functional new bone

tissue, which was eligible for implant insertion and aesthetic restorage in a patient with alveolar cleft [62]. Our clinical and radiological findings in the current study could confirm our previous results [51,52,62].

Clinical examination of the patients after a follow-up period of one year showed no complications. We detected high success-rate of the implants, while the patients did not suffer any serious complications. We found good gingival indices, no infections, no pus, low plaque indices and a low rate of implant recession, furthermore we detected high implant stability. This has been shown by our research group on customized CAD/CAM allogenic bone blocks before [51,52,62].

Patient satisfaction was high in the current study. On a scale from 1 to 10, where 1 stands for “totally unsatisfactory” and 10 for “very satisfied”, the average rating of our patients was 10 (standard deviation 1). This shows very high patient satisfaction after a CAD/CAM customized allogenic bone grafting, following implantation in the aesthetic zone as well.

Our current and previous results [51,52,62] are further confirmed by the study of Kloss et al. (2010) [57]. Our studies had no long-term follow-up included, which represents a limitation of the current- and of our previous studies [51,52,62]. The study of Kloss et al. (2020) [57] included a 5-year follow-up period. The authors analyzed the long-term outcomes of guided bone regeneration with CAD/CAM customized allogenic bone blocks. Kloss et al. (2020) showed histological and radiographic results of CAD/CAM customized allogenic bone blocks. Our current histological-, clinical- and radiologic findings confirm the results of Kloss et al. (2020) [57]. Neither in the current, nor in our previous studies, wound infections, post-operative complications or implant loss could be observed. Guided bone regeneration with customized allogenic bone blocks presented to be a safe and effective method, shown in the current study, as well as in our previous research [51,52,62]. Our results have been confirmed by other authors [48,57].

After a period of 5-year follow-up Kloss et al. (2020) [57] could find no signs of block graft exposure, wound infection, post-operative complications, or wound healing problems. We could not detect such complications in the current study either.

The current study showed that CAD/CAM customized allogenic bone blocks may be a suitable alternative to autologous bone grafting, even in the aesthetic zone. The implants

have successfully integrated. Furthermore, we could show high volume stability, low complication rate, short surgical time and high patient satisfaction.

Nevertheless, the current study has some limitations. We could include 23 patients in our study, which represents a small number of patients with CAD/CAM customized bone blocks. Most of the literature so far, are only case studies with an even smaller number of patients. Further research with large numbers of patients is required to confirm our findings. On the other hand, our current study shows promising results with customized CAD/CAM allogenic bone blocks. CAD/CAM customized bone blocks could represent a feasible alternative to autologous bone grafts, especially in the aesthetic zones. Another limitation of the current study is, that there was no long-term follow-up. We carried out a one-year follow-up of the patients, while only 12 patients showed up for follow-up examinations.

To date, there are no randomized, controlled trials available comparing allogenic CAD/CAM bone blocks with autologous bone grafts from the iliac crest. Thus, further studies still remain to be carried out to confirm our results.

## 6. Conclusion

Even though there is plenty of literature about the successful implantation of allogenic bone materials for the reconstruction of bone defects, randomized controlled studies with a large number of patients, examining the customized allogenic CAD/CAM bone blocks are still rare, to date. The current study with 23 patients who presented with severe bone defects in the aesthetic zone in the upper jaw showed, that customized allogenic CAD/CAM bone blocks may be suitable as a reliable bone graft in those patients. We found a very small complication rate with the customized CAD/CAM bone blocks. Volume stability was comparable to autologous bone blocks. The avoidance of donor morbidity makes the customized allogenic CAD/CAM bone blocks to a serious alternative to autologous bone grafts. We found in our study that none of our 23 patients needed a reaugmentation. This demonstrates the safety and reliability of customized allogenic CAD/CAM bone blocks. The current study provided evidence for the reliability and safety of this method.

The utilization of the volumetric measuring methods utilizing Slicer and coDiagnostiX showed to be practicable and reliable to measure volume changes of hard tissue. Especially the coherence of our results demonstrated the reliability and practicability of those methods for digital volumetric measurements. To validate the results of our current study, further studies are needed, especially in other intraoral areas like the mandibula or the posterior maxilla.



## **7. Summary**

The analyzation of the clinical, radiological and histological outcomes in patients with severe bone defects of the aesthetic zone in maxilla, receiving bone grafting with CAD/CAM prefabricated allogenic bone blocks, provides the evidence of the usability of this technique. The clinical results showed a successful reconstruction of all bone defects, without the need of re-augmentation in any patient. Low complication rates, complete osseointegration of the allografts and a volume stability similar to autologous bone blocks offered anatomical requirements for a successful implantation in all patients. Considering this and the fact, that the use of allografts allows a patient individually designed prefabrication of the graft using CAD/CAM technology, combined with the lack of donor morbidity, indicates that CAD/CAM allogenic bone blocks are a serious alternative to autologous bone blocks for the reconstruction of severe defects of the alveolar crest.

The use of digital volume rendering software is feasible for the volumetric evaluation of hard tissue changes. The coherence of two different independently used measuring methods (Slicer and CoDiagnostix) validates the reliability and practicability of this approach.

## 8. List of references

- [1] Zhao R, Yang R, Cooper PR, Khurshid Z, Shavandi A, Ratnayake J. (2021). Bone Grafts and Substitutes in Dentistry: A Review of Current Trends and Developments. *Molecules*. 18;26(10):3007.
- [2] Majzoub J, Ravida A, Starch-Jensen T, Tattan M, Suárez-López Del Amo F. (2019). The Influence of Different Grafting Materials on Alveolar Ridge Preservation: A Systematic Review. *J Oral Maxillofac Res*. 5;10(3):e6.
- [3] Baldwin P, Li DJ, Auston DA, Mir HS, Yoon RS, Koval KJ. (2019). Autograft, Allograft, and Bone Graft Substitutes: Clinical Evidence and Indications for Use in the Setting of Orthopaedic Trauma Surgery. *J Orthop Trauma*. 33(4):203-213.
- [4] Dimitriou R, Jones E, (2011). McGonagle D, Giannoudis PV. Bone regeneration: current concepts and future directions. *BMC Med*.9:66.
- [5] Yamada M, Egusa H. (2018). Current bone substitutes for implant dentistry. *J Prosthodont Res*.;62(2):152-161.
- [6] Bauer TW, Muschler GF. (2000). Bone graft materials. An overview of the basic science. *Clin Orthop Relat Res*.(371):10-27.
- [7] Azi ML, Aprato A, Santi I, Kfuri M Jr, Masse A, Joeris A. (2016). Autologous bone graft in the treatment of post-traumatic bone defects: A systematic review and meta-analysis. *BMC Musculoskelet Disord*. 17(1):465.
- [8] Pape HC, Evans A, Kobbe P. (2010). Autologous bone graft: properties and techniques. *J Orthop Trauma*.;24 Suppl 1:S36-40.
- [9] Schmidt AH. (2021). Autologous bone graft: Is it still the gold standard? *Injury*.52 Suppl 2:S18-S22.
- [10] Fillingham Y, Jacobs J. (2016). Bone grafts and their substitutes. *Bone Joint J*.98-B: 6-9.
- [11] Stumbras A, Kuliesius P, Januzis G, Juodzbaly G. (2019). Alveolar Ridge Preservation after Tooth Extraction Using Different Bone Graft Materials and Autologous Platelet Concentrates: a Systematic Review. *J Oral Maxillofac Res*. 31;10(1):e2.

- [12]. Liu Y, Sun X, Yu J, Wang J, Zhai P, Chen S, Liu M, Zhou Y. (2019). Platelet-Rich Fibrin as a Bone Graft Material in Oral and Maxillofacial Bone Regeneration: Classification and Summary for Better Application. *Biomed Res Int.* 6;2019:3295756.
- [13] Shavit E, Shavit I, Pinchasov D, Shavit D, Pinchasov G, Juodzbaly G. (2019). The Use of Tooth Derived Bone Graft Materials in Sinus Augmentation Procedures: a Systematic Review. *J Oral Maxillofac Res.* 30;10(2):e1.
- [14] Buser Z, Brodke DS, Youssef JA, Meisel HJ, Myhre SL, Hashimoto R, Park JB, Tim Yoon S, Wang JC. (2016). Synthetic bone graft versus autograft or allograft for spinal fusion: A systematic review. *J Neurosurg Spine* 25(4):509-516.
- [15] Avila-Ortiz G, Elangovan S, Kramer KW, Blanchette D, Dawson DV. (2014). Effect of alveolar ridge preservation after tooth extraction: a systematic review and meta-analysis. *J Dent Res.*;93(10):950-8.
- [16] Artas G, Gul M, Acikan I, Kirtay M, Bozoglan A, Simsek S, Yaman F, Dundar S. (2018). A comparison of different bone graft materials in peri-implant guided bone regeneration. *Braz Oral Res.* 32:e59.
- [17] Chavda S, Levin L. (2018). Human Studies of Vertical and Horizontal Alveolar Ridge Augmentation Comparing Different Types of Bone Graft Materials: A Systematic Review. *J Oral Implantol.* 44(1):74-84.
- [18] Jacotti M, Wang HL, Fu JH, Zamboni G . (2012). Ridge Augmentation With Mineralized Block Allografts: Clinical and Histological Evaluation of 8 Cases Treated With the 3-Dimensional Block Technique. *Implant Dent.* 21(6):444-448.
- [19] DGI, DGZMK: Implantologische Indikationen für die Anwendung von Knochenersatzmaterialien, AWMF -Registernummer: 083-009.
- [20] Aludden HC, Mordenfeld A, Hallman M, Dahlin C, Jensen T. (2017). Lateral ridge augmentation with Bio-Oss alone or Bio-Oss mixed with particulate autogenous bone graft: A systematic review. *Int J Oral Maxillofac Surg.* 46(8):1030-1038.
- [21] Starch-Jensen T, Deluiz D, Bruun NH, Tinoco EMB. (2020). Maxillary Sinus Floor Augmentation with Autogenous Bone Graft Alone Compared with Alternate Grafting Materials: A Systematic Review and Meta-Analysis Focusing on Histomorphometric Outcome. *J Oral Maxillofac Res.* 30;11(3):e2.
- [22] Papageorgiou SN, Papageorgiou PN, Deschner J, Götz W. (2016). Comparative effectiveness of natural and synthetic bone grafts in oral and maxillofacial surgery prior

to insertion of dental implants: Systematic review and network meta-analysis of parallel and cluster randomized controlled trials. *J Dent.*;48:1-8.

[23] Nkenke E, Weisbach V, Winckler E. (2004). Morbidity of harvesting of bone grafts from the iliac crest for preprosthetic augmentation procedures: A prospective study. *Int J Oral Maxillofac Surg.* 33(2):157-163.

[24] Chiapasco M, Zaniboni M. (2011) Failures in jaw reconstructive surgery with autogenous onlay bone grafts for pre-implant purposes: Incidence, prevention and management of complications. *Oral Maxillofac Surg Clin North Am.*23(1):1-15, v.

[25] Testori T, Weinstein T, Taschieri S, Wallace SS. (2019). Risk factors in lateral window sinus elevation surgery. *Periodontol 2000.*;81(1):91-123.

[26] Klifto CS, Gandhi SD, Sapienza A. (2018). Bone Graft Options in Upper-Extremity Surgery. *J Hand Surg Am.* 43(8):755-761.e2.

[27] Richards W, Ameen J, Coll AM, Higgs G. (2005). Reasons for tooth extraction in four general dental practices in South Wales. *Br Dent J.* 12;198(5):275-8.

[28] Min S, Liu Y, Tang J, Xie Y, Xiong J, You HK, Zadeh HH. (2016). Alveolar ridge dimensional changes following ridge preservation procedure with novel devices: Part 1 CBCT linear analysis in non-human primate model. *Clin Oral Implants Res.*;27(1):97-105.

[29] Scheyer ET, Heard R, Janakievski J, Mandelaris G, Nevins ML, Pickering SR, Richardson CR, Pope B, Toback G, Velásquez D, Nagursky H. (2016). A randomized, controlled, multicentre clinical trial of post-extraction alveolar ridge preservation. *J Clin Periodontol.*;43(12):1188-1199.

[30] Solakoglu Ö, Götz W, Heydecke G, Schwarzenbach H. (2019). Histological and immunohistochemical comparison of two different allogenic bone grafting materials for alveolar ridge reconstruction: A prospective randomized trial in humans. *Clin Implant Dent Relat Res.*;21(5):1002-1016.

[31] Kenkre JS, Bassett J. (2018). The bone remodeling cycle. *Ann Clin Biochem.*;55(3):308-327.

[32] Feng X, McDonald JM. (2011). Disorders of bone remodeling. *Annu Rev Pathol.*;6:121-45.

- [33] Ramesh N, Moratti SC, Dias GJ. (2018). Hydroxyapatite-polymer biocomposites for bone regeneration: A review of current trends. *J Biomed Mater Res B Appl Biomater.* 106(5):2046-2057.
- [34] Florencio-Silva R, Sasso GR, Sasso-Cerri E, Simões MJ, Cerri PS. (2015). Biology of Bone Tissue: Structure, Function, and Factors That Influence Bone Cells. *Biomed Res Int.* 2015:421746.
- [35] Compton JT, Lee FY. (2014). A review of osteocyte function and the emerging importance of sclerostin. *J Bone Joint Surg [Am]* 96-A:1659–1668
- [36] Lin C, Jiang X, Dai Z. (2009). Sclerostin mediates bone response to mechanical unloading through antagonizing Wnt/beta-catenin signaling. *J Bone Miner Res* 24:1651–1661
- [37] Oryan A, Monazzah S, Bigham-Sadegh A. (2015). Bone injury and fracture healing biology. *Biomed Environ Sci* 2015;28:57–71.
- [38] Ansari, M. (2019) Bone tissue regeneration: Biology, strategies and interface studies. *Prog Biomater* 8, 223–237
- [39] Pereira E, Messias A, Dias R. (2015). Horizontal resorption of fresh-frozen corticocancellous bone blocks in the reconstruction of the atrophic maxilla at 5 months. *Clinical Implant Dentistry and Related Research.* ;17:444-458.
- [40] Albrektsson T, Johansson C. (2001). Osteoinduction, osteoconduction and osseointegration. *European Spine Journal.*; 10(2):96-101
- [41] Carlson ER, Marx RE, Buck BE. (1995). The potential for HIV transmission through allogenic bone. A review of risks and safety. *Oral Surg Oral Med Oral Pathol Oral Radiol Endol.*; 80:17-23.
- [42] Spin Neto R, Felipe Leite C, Pereira LA. (2013). Is peripheral blood cell balance altered by the use of fresh frozen bone block allografts in lateral maxillary ridge augmentation? *Clin Implant Dent Relat Res.*; 15:262-270.
- [43] Monje A, Pikos MA, Chan H-L. (2014). On the feasibility of utilizing allogenic bone blocks for atrophic maxillary augmentation. *Biomed Res Int.*:814578.
- [44] Novell J, Novell-Costa F, Ivorra C, Fariñas O, Munilla A, Martinez C. (2012). Five-year results of implants inserted into freeze-dried block allografts. *Implant Dent.*;21(2):129-135.

- [45] Leonetti J, Koup R. (2003). Localized Maxillary Ridge Augmentation With a Block Allograft for Dental Implant Placement: Case Reports. *Implant Dent.*;12(3):217-226.
- [46] Carlsen A, Gorst-Rasmussen A, Jensen T. (2013). Donor site morbidity associated with autogenous bone harvesting from the ascending mandibular ramus. *Implant Dent.*;22(5):503-6.
- [47] Motamedian SR, Khojaste M, Khojasteh A. (2016). Success rate of implants placed in autogenous bone blocks versus allogenic bone blocks: A systematic literature review. *Ann Maxillofac Surg.*;6(1):78-90.
- [48] Otto S, Kleye C, Burian E, Ehrenfeld M, Cornelius CP. (2017). Custom-milled individual allogenic bone grafts for alveolar cleft osteoplasty -A technical note. *J Craniomaxillofac Surg.*;45(12):1955-1961.
- [49] Nkenke E, Stelzle F. (2009). Clinical outcomes of sinus floor augmentation for implant placement using autogenous bone or bone substitutes: A systematic review. *Clin Oral Implants Res.*;20 Suppl 4:124-33
- [50] Whitesides LM, Radwan A, Sharawy M. (2006). Sinus floor augmentation using a composite graft of bone morphogenetic protein-2 and allogenic cancellous bone (Puros): A case report. *J Oral Implantol.*;32(5):259-64.
- [51] Blume O, Hoffmann L, Donkiewicz P, Wenisch S, Back M, Franke J, Schnettler R, Barbeck M. (2017). Treatment of Severely Resorbed Maxilla Due to Peri-Implantitis by Guided Bone Regeneration Using a Customized Allogenic Bone Block: A Case Report. *Materials (Basel)*. 21;10(10):1213.
- [52] Blume O, Back M, Born T, Smeets R, Jung O, Barbeck M. (2018). Treatment of a bilaterally severely resorbed posterior mandible due to early tooth loss by Guided Bone Regeneration using customized allogenic bone blocks: A case report with 24 months follow-up data. *J Esthet Restor Dent.*;30(6):474-479.
- [53] Eskow AJ, Mealey BL. (2014). Evaluation of healing following tooth extraction with ridge preservation using cortical versus cancellous freeze-dried bone allograft. *J Periodontol.*;85(4):514-524.
- [54] Chaushu G, Mardinger O, Peleg M, Ghelfan O, Nissan J. (2010). Analysis of complications following augmentation with cancellous block allografts. *J Periodontol.*;81(12):1759-1764.

- [55] Acocella A, Bertolai R, Ellis E. (2012). Maxillary alveolar ridge reconstruction with monocortical fresh-frozen bone blocks: a clinical, histologic and histomorphometric study. *J craniomaxillofac Surg.*;40:525-533.
- [56] Schlee M, Rothamel D. (2013). Ridge augmentation using customized allogenic bone blocks: Proof of concept and histological findings. *Implant Dent.*;22(3):212-8.
- [57] Kloss FR, Offermanns V, Donkiewicz P, Kloss-Brandstätter A. (2020). Customized allogenic bone grafts for maxillary horizontal augmentation: A 5-year follow-up radiographic and histologic evaluation. *Clin Case Rep.* 11;8(5):886-893.
- [58] Cha HS, Kim JW, Hwang JH, Ahn KM. (2016). Frequency of bone graft in implant surgery. *Maxillofac Plast Reconstr Surg.* 31;38(1):19.
- [59] Venet L, Perriat M, Mangano FG, Fortin T. (2017). Horizontal ridge reconstruction of the anterior maxilla using customized allogenic bone blocks with a minimally invasive technique - a case series. *BMC Oral Health.* 8;17(1):146.
- [60] Starch-Jensen T, Deluiz D, Tinoco EMB. (2020). Horizontal Alveolar Ridge Augmentation with Allogenic Bone Block Graft Compared with Autogenous Bone Block Graft: A Systematic Review. *J Oral Maxillofac Res.* 31;11(1):e1.
- [61] Blume O, Donkiewicz P, Palkovics D, Götz W, Windisch P. (2021). Volumetric Changes of a Customized Allogenic Bone Block Measured by Two Image Matching Tools: Introduction of a Novel Assessment Technique for Graft Resorption. *Acta Stomatol Croat.*;55(4):406-417.
- [62] Blume O, Back M, Born T, Donkiewicz P. (2019). Reconstruction of a Unilateral Alveolar Cleft Using a Customized Allogenic Bone Block and Subsequent Dental Implant Placement in an Adult Patient. *J Oral Maxillofac Surg.*;77(10):2127.e1-2127.e11.
- [63] Tresguerres FGF, Cortes ARG, Hernandez Vallejo G, Cabrejos-Azama J, Tamimi F and Torres J (2019) Clinical and radiographic outcomes of allogenic block grafts for maxillary lateral ridge augmentation: A randomized clinical trial. *Clin Implant Dent Relat Res* 21:1087-1098. doi: 10.1111/cid.12834
- [64] Wang HL and Al-Shammari K. (2002) HVC ridge deficiency classification: A therapeutically oriented classification. *Int J Periodontics Restorative Dent* 22:335-43.

[65] Al-Nawas B, Stein K. (2010) Indication of a preoperative antibiotic prophylaxis for the insertion of dental implants – A systematic review. *ZZI* 01/2010: 49-60. Doi 10.3238/ZZI.2010.0049

[66] Toffler M, Toscano N, Holtzclaw D, Del Corso , Ehrenfest D. (2009) Introducing Choukroun's Platelet Rich Fibrin to the reconstructive surgery milieu. *Journal of Implant & Advanced Clinical Dentistry* Vol 1, No. 6 2009: 21-32

[67] Hill PA, Orth M. (1998) Bone remodeling. *British Journal of Orthodontics*, 25 (2), 101-107

[68] Blume O, Back M, Dinya E, Palkovics D, Windisch P. (2023). Efficacy and volume stability of a customized allogenic bone block for the reconstruction of advanced alveolar ridge deficiencies at the anterior maxillary region: A retrospective radiographic evaluation. *Clin Oral Investig.* 14. doi: 10.1007/s00784-023-05015-0. Epub ahead of print. PMID: 37055540.



## 9. Bibliography of the candidate's publications

1. [51] Blume O, Hoffmann L, Donkiewicz P, Wenisch S, Back M, Franke J, Schnettler R, Barbeck M. Treatment of Severely Resorbed Maxilla Due to Peri-Implantitis by Guided Bone Regeneration Using a Customized Allogenic Bone Block: A Case Report. *Materials (Basel)*. 2017 Oct 21;10(10):1213.
2. [52] Blume O, Back M, Born T, Smeets R, Jung O, Barbeck M. Treatment of a bilaterally severely resorbed posterior mandible due to early tooth loss by Guided Bone Regeneration using customized allogenic bone blocks: A case report with 24 months follow-up data. *J Esthet Restor Dent*. 2018 Nov;30(6):474-479.
3. [61] Blume O, Donkiewicz P, Palkovics D, Götz W, Windisch P. Volumetric Changes of a Customized Allogenic Bone Block Measured by Two Image Matching Tools: Introduction of a Novel Assessment Technique for Graft Resorption. *Acta Stomatol Croat*. 2021 Dec;55(4):406-417.
4. [62] Blume O, Back M, Born T, Donkiewicz P. Reconstruction of a Unilateral Alveolar Cleft Using a Customized Allogenic Bone Block and Subsequent Dental Implant Placement in an Adult Patient. *J Oral Maxillofac Surg*. 2019 Oct;77(10): 2127.e1-2127.e11.
5. [68] Blume O, Back M, Dinya E, Palkovics D, Windisch P. Efficacy and volume stability of a customized allogenic bone block for the reconstruction of advanced alveolar ridge deficiencies at the anterior maxillary region: A retrospective radiographic evaluation. *Clin Oral Investig*. 2023 Apr 14. doi: 10.1007/s00784-023-05015-0. Epub ahead of print. PMID: 37055540.

## 10. Acknowledgements

Firstly, I would like to thank my supervisor Peter Windisch, for his trust in me and my work and for his professional scientific guidance and assistance.

I want to thank Daniel Palkovics for his fantastic work with “Slicer”, for his teamwork with me and I really hope that we will collaborate in many more scientific projects.

I want to thank Balint Molnar for reviewing my work and giving me so important and valuable suggestions for improvement.

I want to thank my friend and partner in my office Michael Back and the whole team of our practice, especially Jennifer for supporting me with the project obtaining a PhD degree.

I would like to thank the Semmelweis University for providing me the possibility to do and to finish my PhD studies.

I would like to thank my British mother-in-law Penelope for her linguistic and my sister-in-law Nora for her scientific support.

And, finally I would like to thank my family, my wife Anna, my children Leonard, Matilda, Jonathan and Benedict, my sister Nicola and my mother Gerda for believing in me.

## Figures

<b>Figure 1.</b> Fractured tibia as complication after harvesting autologous bone material. (Source: own work) .....	4
<b>Figure 2.</b> Necrosis of the soft tissue at the iliac crest. (Source: own work) .....	4
<b>Figure 3.</b> The bone remodeling cycle. (Source: Hill 1998 [67]) .....	9
<b>Figure 4.</b> The four types of bone cells. (Source: Ansari 2019 [38]).....	10
<b>Figure 5.</b> Bone repair and restorage. (Source: Ansari 2019 [38]) .....	15
<b>Figure 6.</b> Examples of bone defects in the aesthetic zone. (Source: Blume 2023 [68])	26
<b>Figure 7.</b> 3D model from the implanted bone block. (Source: Blume 2023 [68]) .....	28
<b>Figure 8.</b> Three-dimensional morphological alterations between T2 and T3 visualized via a 3D colormap analysis. (Source: Blume 2023 [68]) .....	30
<b>Figure 9.</b> Linear measurements. (Source: Blume 2023 [68]) .....	31
<b>Figure 10.</b> Flap elevation procedure. (Source: Blume 2023 [68]).....	35
<b>Figure 11.</b> Fixation of the bone block with titanium screws. (Source: Blume 2023 [68]) .....	36
<b>Figure 12.</b> Reentry after 6 months and implant placement. (Source: Blume 2023 [68]) .....	37
<b>Figure 13.</b> Results of the histological analysis. (Source: own work) .....	48
<b>Figure 14.</b> Calculation of bone loss. (Source: own work) .....	53

## Tables

<b>Table 1.</b> Properties of different bone graft materials. (Source: Baldwin 2019 [3]) .....	2
<b>Table 2.</b> Patient demographic data and baseline defect characteristics. (Source: Blume 2023 [68]) .....	38
<b>Table 3.</b> Volumetric hard tissue changes with the semi-automatic segmentation ( $n=23$ ). (Source: Blume 2023 [68]) .....	40
<b>Table 4.</b> Volumetric hard tissue changes with global thresholding segmentation ( $n=23$ ). (Source: Blume 2023 [68]) .....	41
<b>Table 5.</b> Comparison of results acquired with the semi-automatic segmentation and the global thresholding segmentation methods ( $n=23$ ). (Source: Blume 2023 [68]) .....	42
<b>Table 6.</b> Vertical linear dimension at future implant positions ( $n=40$ ). (Source: Blume 2023 [68]) .....	43
<b>Table 7.</b> Horizontal linear dimension at future positions ( $n=40$ ). (Source: Blume 2023 [68]) .....	43
<b>Table 8.</b> Comparison between single- and multiple tooth gaps. (Source: Blume 2023 [68]) .....	44
<b>Table 9.</b> Implant insertion. (Source: own work) .....	45
<b>Table 10.</b> Patient satisfaction. (Source: own work) .....	49
<b>Table 11.</b> Results from one-year-follow-up clinical examinations. (Source: own work) .....	50
<b>Table 12.</b> Results of radiological follow-up examination. (Source: own work) .....	52