

**SEMMELWEIS EGYETEM  
DOKTORI ISKOLA**

**Ph.D. értekezések**

**3026.**

**FONTANINI DANIELE MARIASTEFANO**

**Szív- és érrendszeri betegségek élettana és klinikuma  
című program**

Programvezető: Dr. Merkely Béla, egyetemi tanár

Témavezető: Dr. Csobay-Novák Csaba, egyetemi adjunktus

# **PULSATILITY ASSESSMENT IN PATIENTS WITH ABDOMINAL AORTIC ANEURYSMS AND NATIONAL ADVANCEMENTS IN ENDOVASCULAR AORTIC REPAIR**

**PhD Thesis**

**Daniele Mariastefano Fontanini MD**

Cardiovascular Medicine and Research Program

Semmelweis University



Supervisor:

Csaba Csobay-Novák MD, PhD

Official reviewers:

Bálint Lakatos MD, PhD

Eszter Végh MD, PhD

Head of the Complex Examination Committee:

Prof. Tivadar Tulassay

Members of the Complex Examination Committee:

Prof. Henriette Farkas MD, PhD

Prof. Charaf Hassan, PhD

Budapest

2023

## Table of Contents

Table of Contents.....	1
List of Abbreviations .....	3
1. Introduction .....	4
1.1. Epidemiological Overview .....	4
1.2. Aortic Disease .....	5
1.2.1. Aortic Aneurysm .....	5
1.2.2. Acute Aortic Syndrome .....	7
1.3. Imaging of the Aorta .....	9
1.3.1. Ultrasonography .....	9
1.3.2. Computed Tomography .....	10
1.3.3. Magnetic Resonance Imaging .....	11
1.4. Treatment of Aortic Disease .....	11
1.4.1. Endovascular Repair of the Aorta .....	13
1.4.2. Aortic Pulsatility and Endovascular Repair Planning .....	15
1.4.3. Endoanchors in Endovascular Aortic Repair .....	15
1.4.4. Endovascular Aortic Repair in Hungary .....	17
2. Objectives .....	19
2.1. Aortic Pulsatility in Patients with AAA .....	19
2.3. Use of Endoanchors in EVAR in Hungary .....	19
2.4. TEVAR in Hungary Between 2012 and 2016 .....	19
3. Methods .....	20
3.1. Aortic Pulsatility Assessment in Patients with AAA .....	20
3.1.1. CT Imaging .....	20
3.1.2. CT Image Analysis .....	21
3.2. Use of Endoanchors in EVAR in Hungary .....	23
3.3. TEVAR in Hungary Between 2012 and 2016 .....	24
3.4. Statistical Analysis .....	25
4. Results .....	26
4.1. First Study: Aortic Pulsatility Assessment in Patients with AAA .....	26

4.2. Second Study: Use of Endoanchors in EVAR in Hungary .....	29
4.3. Third Study: TEVAR in Hungary Between 2012 and 2016.....	31
5. Discussion.....	35
5.1. Study Limitations.....	40
6. Conclusions .....	41
7. Summary.....	42
8. References .....	43
9. Bibliography of the candidate's publications .....	53
9.1. Publications related to the present thesis .....	53
9.2. Publications not related to the present thesis .....	53
10. Acknowledgements.....	56

## **List of Abbreviations**

AA – Aortic Aneurysm

AAA – Abdominal Aortic Aneurysm

AAS – Acute Aortic Syndrome

AD – Aortic Dissection

BEVAR – Branched Endovascular Aneurysm Repair

CT – Computed Tomography

CTA – Computed Tomography Angiography

CVD – Cardiovascular Disease

ECG – Electrocardiogram

ESVS - European Society for Vascular Surgery

EVAR – Endovascular Aneurysm Repair

FET – Frozen Elephant Trunk

FEVAR – Fenestrated Endovascular Aneurysm Repair

IMH – Intramural Haematoma

MRI – Magnetic Resonance Imaging

PAU – Penetrating Aortic Ulcer

PCCT – Photon-Counting Computed Tomography

QISS – Quiescent-Interval Single-Shot

RAAA – Ruptured Abdominal Aortic Aneurysm

SMA – Superior Mesenteric Artery

SVS – Society for Vascular Surgery

TAA – Thoracic Aortic Aneurysm

TAAA – Thoracoabdominal Aortic Aneurysm

TAAD – Type A Aortic Dissection

TBAD – Type B Aortic Dissection

TEVAR – Thoracic Endovascular Aortic Repair

US – Ultrasound

## 1. Introduction

In recent decades, significant progress has been achieved in the field of aortic diseases, leading to improved outcomes for patients. Notable advancements have contributed to more accurate diagnostic techniques and a wider array of treatment options, leading to better clinical strategies for patients with aortic disease.

Diagnostic advances have revolutionized vascular medicine. Non-invasive imaging techniques such as high-resolution computed tomography angiography (CTA), ultrasound (US) and magnetic resonance imaging (MRI) have played a pivotal role in accurate detection, localization, and characterization of aortic pathology (1, 2).

Treatment modalities have also witnessed significant progress in recent decades. Endovascular techniques, such as endovascular aneurysm repair (EVAR) and thoracic endovascular aortic repair (TEVAR), have emerged as minimally invasive alternatives to open surgical repair. Additionally, the advent of hybrid procedures combining endovascular and surgical techniques has expanded treatment options for complex aortic pathologies (3-5).

### 1.1. Epidemiological Overview

Although there have been different regional trends in mortality from cardiovascular disease (CVD) over the past few decades, CVD maintains its position as the world's number one cause of death. CVD is responsible for 17.3 million deaths worldwide, accounting for 31.5% of all deaths and 45% of all non-communicable disease deaths. It is noteworthy that this number exceeds the number of deaths caused by cancer, with CVD accounting for more than twice as many deaths (6, 7). CVD is also a major public health burden in Hungary, as it has been the leading cause of death in the country for several decades (8).

In terms of mortality, the most important diseases within CVD are coronary heart disease and cerebrovascular disease (6). Nevertheless, aortic disease also poses a significant healthcare challenge. The most important risk factors for aortic disease include

atherosclerosis, hypertension, and smoking. The global death rate from aortic disease, including aortic aneurysm (AA) and aortic dissection (AD), increased slightly between 1990 and 2010, from 2.49 to 2.78 per 100,000 population. In Western Europe, on the other hand, there was no significant change in the death rate from aortic disease, which was 7.69 per 100,000 population in 1990 and 7.68 in 2010. It is also worth mentioning that there is a notable difference in mortality rate regarding patient sex. In 1990, the death rate was 2.86 for men and 2.12 for women. By 2010, it had risen to 3.4 for men and 2.15 for women. These figures show a consistent pattern of higher aortic disease death rates for men compared to women in both 1990 and 2010 (9).

## 1.2. Aortic Disease

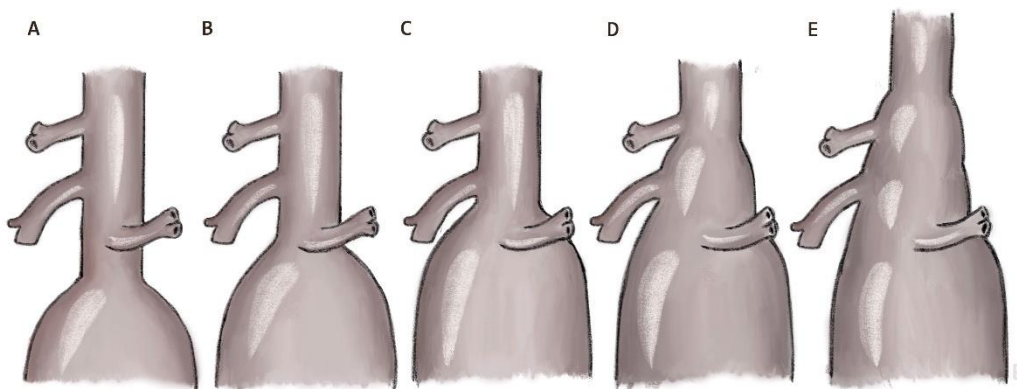
### 1.2.1. Aortic Aneurysm

An aneurysm is a localized dilatation of an artery that exceeds the normal diameter by at least 50%. A true aneurysm is caused by a progressive weakening of the structural components of the arterial wall, with expansion involving all three layers (intima, media and adventitia). On the other hand, pseudoaneurysms form when the vessel wall is injured, allowing extraluminal blood flow that is contained by the surrounding tissue. Aneurysms can also be categorised according to their shape. Fusiform aneurysms show symmetrical widening around the entire circumference of the aortic wall, while saccular aneurysms show bulging of only part of the circumference of the aortic wall (10, 11).

AAs can be divided into three main categories based on their location along the aorta: thoracic aortic aneurysms (TAA), which are located in the chest and involve the ascending aorta, aortic arch and/or descending aorta, abdominal aortic aneurysms (AAA), which are located below the diaphragm and affect the abdominal aorta, and thoracoabdominal aortic aneurysms (TAAA), which involve both the thoracic and abdominal aorta. AAAs are by far the most common of all AAs (10, 12).

Complex AAAs are characterized by the involvement of renal and/or mesenteric arteries and extension up to the level of the diaphragm. However, they do not extend into the thoracic aorta and don't involve the celiac trunk. A widespread classification system is

used regarding complex AAAs, which describes the most proximal extension of the aneurysm in relation to the location of the renal and mesenteric vessels. This classification system includes the description of short-neck infrarenal aortic aneurysms defined by the presence of an infrarenal aortic neck between 4 to 10 mm in length, and juxtarenal aortic aneurysms defined by a neck equal or less than 4 mm in length with aneurysm extension to, but not beyond the renal arteries. Pararenal aortic aneurysms involve at least one of the renal arteries and extend up to, but not cranial to, the superior mesenteric artery (SMA). Paravisceral aortic aneurysms involve the renal arteries and the SMA, but not the celiac axis (13, 14) [Figure 1].



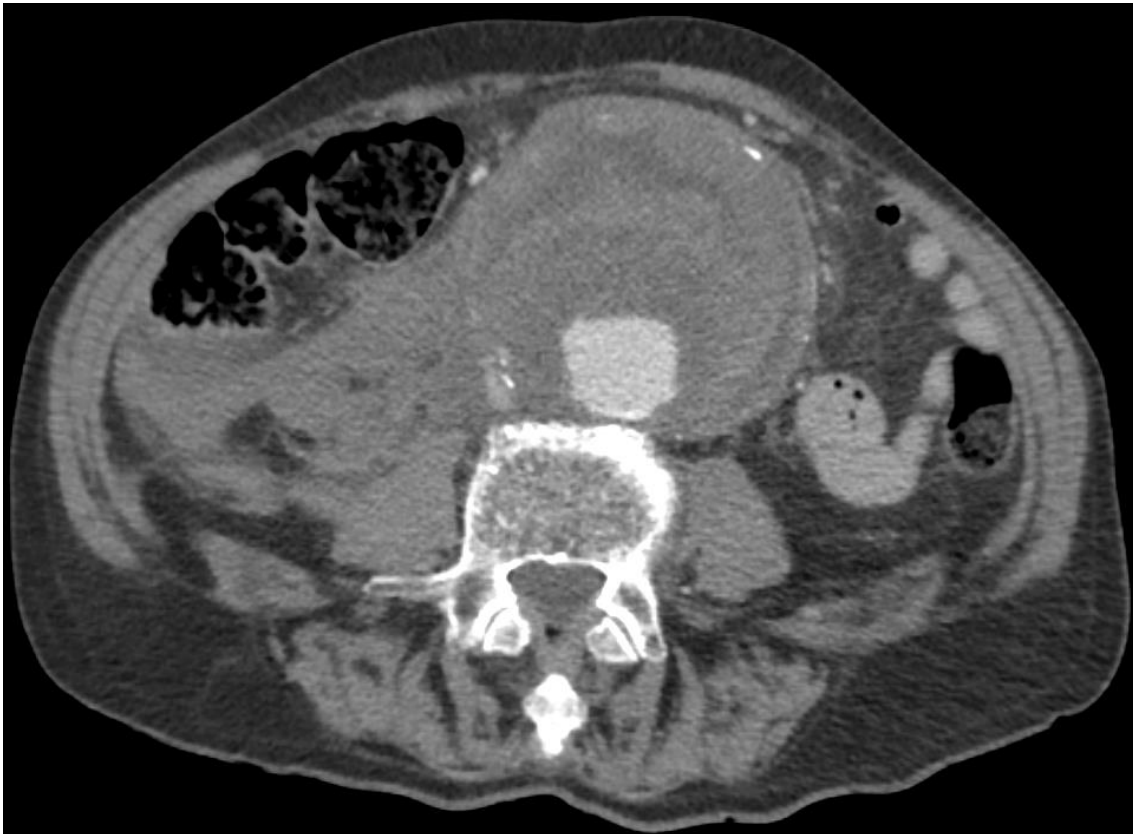*Figure 1: Classification of complex abdominal aortic aneurysms in relation to renal and visceral branches. Short-neck infrarenal (A); juxtarenal (B); pararenal (C); paravisceral (D) and type IV thoracoabdominal aortic aneurysm (E). (By permission of Anna Kelemenné Polgár, Heart and Vascular Center, Semmelweis University)*

The most common etiology of AAs is degenerative, although it is often associated with atherosclerosis (11). Several risk factors contribute to the development of aortic aneurysms. Hypertension, tobacco use, age, male sex, family history of AA, hyperlipidaemia and certain genetic disorders such as Marfan syndrome and Ehlers-Danlos syndrome are among the factors connected to AA development (14-17).

The most severe complication of an AA is rupture. A ruptured abdominal aortic aneurysm (RAAA) is an aneurysm with blood extravasation, usually confirmed by computed tomography (CT). Contained rupture refers to extravasation from the aneurysm sac, tamponaded by the surrounding tissues. This form of rupture is most commonly observed



in the retroperitoneum. Free rupture, on the other hand, refers to bleeding into the peritoneal cavity, or thorax in the case of TAAs, without tamponade. AA rupture is an acute medical emergency, that require urgent diagnostic assessment and intervention (3, 10, 11) [Figure 2].



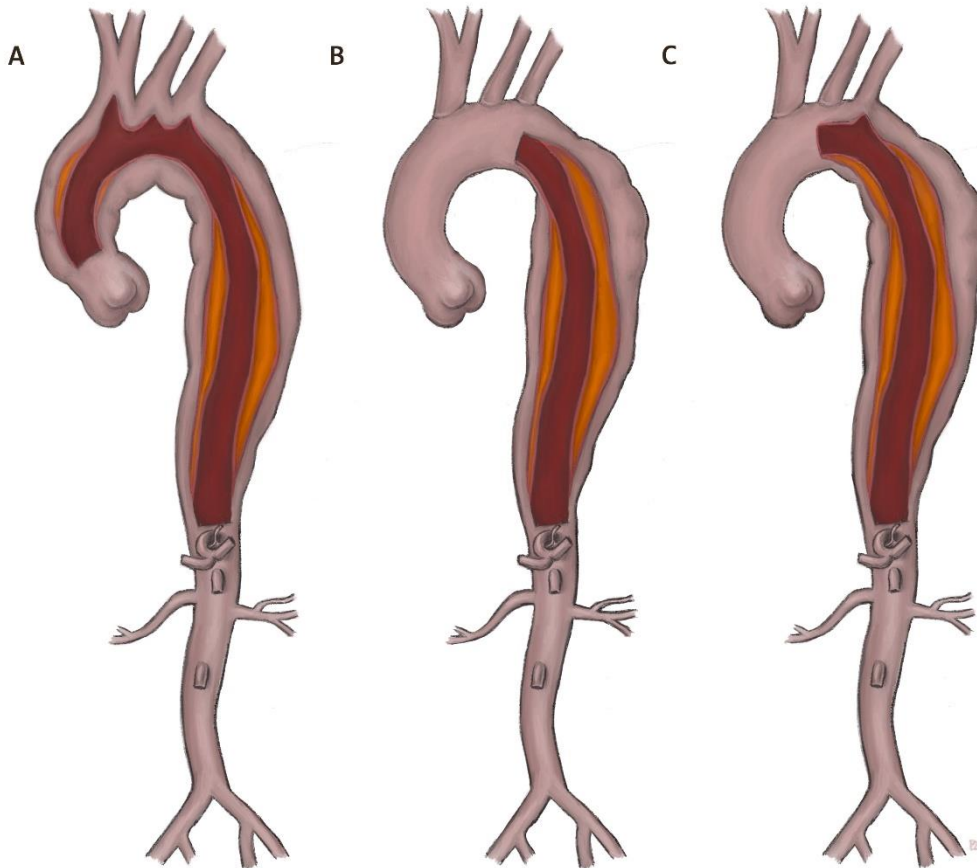
*Figure 2: Contrast-enhanced CT image of an abdominal aortic aneurysm with free rupture into the retroperitoneum and the abdominal cavity. (Image by the author)*

### 1.2.2. Acute Aortic Syndrome

Acute aortic syndromes (AAS) are a group of life-threatening aortic conditions that often present with extreme pain and require urgent medical intervention. By far the most important condition among them is aortic dissection (AD). AAS also includes intramural haematoma (IMH), penetrating aortic ulcer (PAU) and blunt aortic trauma. (11).

AD is categorized by the widely adopted DeBakey and Stanford classifications, the latter of which is regularly used in everyday vascular medicine (18, 19). According to the classification adopted by the most recent 2019 European Society for Vascular Surgery (ESVS) guidelines based on the original Stanford system, type A aortic dissection

(TAAD) refers to any dissection involving the ascending aorta. In the case of type B aortic dissection (TBAD), only the descending aorta is involved. Non-A-non-B aortic dissection refers to a TBAD that involves the arch, either by the most proximal tear or by retrograde extension (4) [Figure 3].



*Figure 3: Modified Stanford classification of aortic dissections based on the 2019 European Society for Vascular Surgery Guidelines. Type A (A); Type B (B); Non-A-non-B (C) (4) (By permission of Anna Kelemenné Polgár, Heart and Vascular Center, Semmelweis University).*

Recently, there have been several attempts to update the classification of AD, including the DISSECT and TEM systems (20-22). The Society for Vascular Surgery (SVS) and Society of Thoracic Surgeons have recommended using the Stanford classification in conjunction with the aortic zones of attachment (described later). Dissections that have an entry tear starting in Z0 with distal extension into Z1 to Z11 are referred as TAAD, while dissections that have an intimal tear starting at Z1 and extending into zones Z2 to Z11 are categorized as TBAD. It is worth mentioning that according to these reporting

standards, an AD resulting from an entry tear of the arch, or the descending aorta is considered TBAD even in the case of retrograde involvement of the ascending aorta (23).

In terms of AD phases, a dissection with an onset of less than 2 weeks is considered acute, subacute if between 2 weeks and 3 months, and chronic if more than 3 months have elapsed since the onset of the symptoms (14). Risk factors for AD include hypertension, pre-existing or history of other aortic disease, tobacco use and use of intravenous drugs (11, 24). Regarding complications, TAAD poses a significant risk for myocardial ischaemia, heart tamponade and congestive heart failure, whereas paraplegia, renal, visceral or limb malperfusion may result from both TAAD and TBAD (11, 25-27).

### 1.3. Imaging of the Aorta

Diagnostic imaging is a cornerstone of modern cardiovascular medicine. Screening, surgical decision-making, pre-operative planning, post-operative care, and long-term follow-up rely on many modalities of radiology, of which CT, US and MRI are of paramount importance (1-5).

#### 1.3.1. Ultrasonography

The first-line imaging tools for detecting AAAs are abdominal ultrasound (US) and duplex ultrasonography. Widely utilized in emergency medicine, US is a readily available and fast modality that has excellent sensitivity and specificity for the assessment of the abdominal aorta. US is also the first choice in the management of small AAAs. It is important to mention however, that the visualisation of the descending aorta is limited with US. Nevertheless, it is worth noting that transesophageal echocardiography and intravascular US may in some cases provide additional information in the assessment of AD. In terms of more contemporary advances in the field, contrast-enhanced US has become a promising alternative to CTA for endoleak detection after EVAR, potentially reducing the regular radiation exposure of these patients (11, 28-32).

### 1.3.2. Computed Tomography

CTA is the prevailing imaging technique utilized for aortic imaging, offering several advantages over alternative modalities. At present, it remains the preferred radiology modality of choice. As a widely available safe and fast imaging technique, it plays a crucial role in the elective setting of pre-operative EVAR/TEVAR planning, as well as follow-up. In addition, CT is the first choice in the event of AAS or AA rupture (1, 2, 33-35).

In the past decades, advances in CT technology resulted in high spatial and temporal resolution that allow multiplanar reformations and vessel segmentation (3). Nonetheless, the most revolutionary feature that has been implemented into routine CTA imaging is electrocardiogram (ECG) gating. Synchronizing CT acquisition to the ECG signal has led to a notable decrease in motion artefacts that have previously been a noteworthy burden, especially in coronary and thoracic aortic imaging. Two main different forms of ECG synchronization are used in cardiovascular CT diagnostics: prospective triggering and retrospective gating. Prospective triggering leads to substantially reduced radiation dose but results in a stationary image, retrospective gating, on the other hand, allows for a comparison between multiple phases within a cardiac cycle. This makes it possible to compare systolic and diastolic images (phases 30-50% and 70-90% of the R-R cycle), which plays a key role in the subject matter of this thesis. Using retrospective gating dynamic data can be collected, but radiation doses are higher than those registered during prospective triggering (4, 36).

More recent development in the field of aortic CT imaging includes high-pitch time-resolved dynamic CTA, which is a promising technique in postoperative endoleak detection after EVAR (37-39). The advent of photon-counting CT (PCCT) detectors capable of spectral data acquisition allows an unparalleled contrast-to-noise ratio, thereby reducing the amount of intravenous contrast agent required for diagnostic image quality. Moreover, PCCT is also able to operate with optimized radiation exposure (40).

### 1.3.3. Magnetic Resonance Imaging

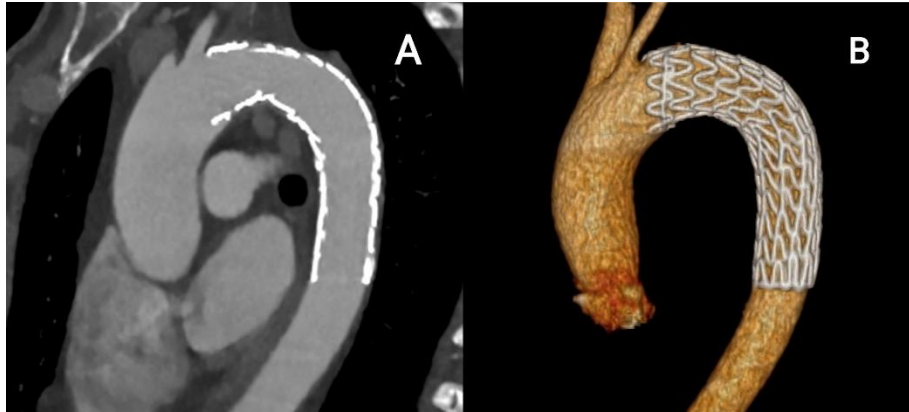
Magnetic resonance angiography (MRA) is not as widely accessible as CTA and may be limited for patients with claustrophobia or certain metal implants. Nevertheless, MRA has advantages over CTA in that it does not involve radiation exposure. This makes MRA particularly advantageous when repeated imaging is required for the management of AAAs. Gadolinium contrast enhanced measurements and non-contrast sequences can play an equally important role in vascular imaging, depending on the assessed segment and indication of the study. Recent advances in vascular MRI include quiescent-interval single-shot (QISS) MRA, a novel non-contrast technique that has shown promising results in aorto-iliac disease assessment (32, 41, 42).

### 1.4. Treatment of Aortic Disease

Conservative therapy remains an important element in the management of aortic disease. For patients with small AAs, smoking cessation is recommended. Medical therapy aimed at reducing aneurysm growth rate includes blood pressure control, antiplatelet therapy, and statins. In acute TBAD, blood pressure control and pain relief are the fundamental pillars of medical therapy (3, 5).

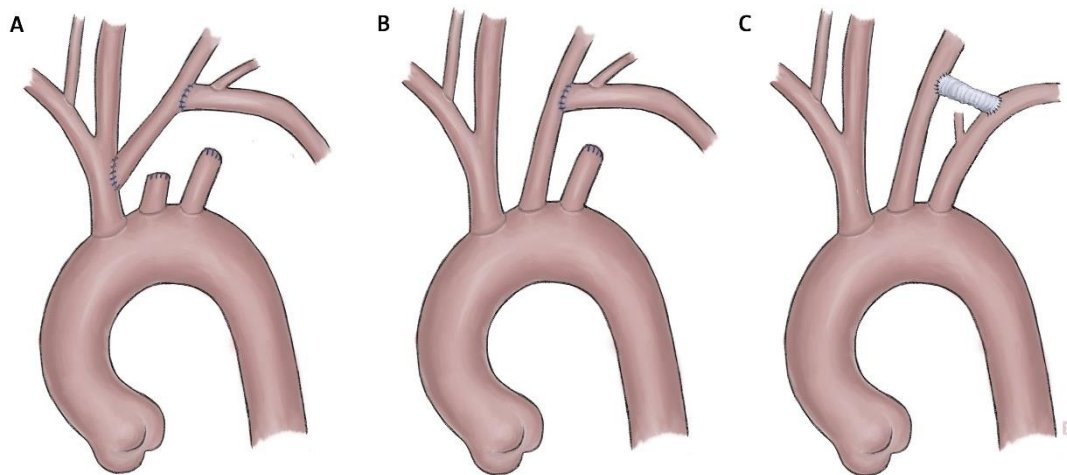
Nonetheless, endovascular and surgical interventions are the key components of definitive aortic disease treatment. With regard to the indication for elective repair, it should be emphasised that an AAA with a diameter of 5.5 cm or more is an indication for elective repair in men. In women, this threshold may be lowered to 5.0 cm if the surgical risk is acceptable. Fast-track referral to vascular surgery is advised in the case of rapid aneurysm growth of more than 1 cm/year or the development of symptoms of a known aneurysm. EVAR and open repair are both viable options for elective AAA repair. In most patients with suitable anatomy and reasonable life expectancy, EVAR is to be considered as the preferred technique, whereas in patients with long life expectancy, open surgery is advised to be the preferred treatment modality (3).

Invasive treatment of AAS mainly depends on the form in which it presents. In the case of TAAD, surgery is indicated due to the high mortality and severe complications of the condition. TEVAR is the first-line treatment for acute complicated TBAD, acute IMH, descending TAA rupture or blunt aortic trauma. (5, 11) [Figure 4].



*Figure 4: Oblique planar (A) and volume rendering (B) reformations show a postoperative follow-up CTA scan after zone 2 thoracic endovascular aortic repair for type B aortic dissection. (Image by the author.)*

The management of patients with aortic disease involving the arch is complex. In addition to open surgical techniques such as aortic arch replacement, hybrid approaches such as the elephant trunk and frozen elephant trunk (FET) procedures are becoming a widespread alternative. Concerning TEVAR involving the arch, it is important to note that revascularisation of the supra-aortic branches can be achieved either by various forms of surgical debranching [Figure 5] or by performing a total endovascular aortic arch repair using fenestrated or branched endografts. In every case, it is very important to emphasise that hybrid and endovascular aortic arch repair should be centralised in centres with appropriate volume and experience in both open and endovascular aortic arch surgery (4).

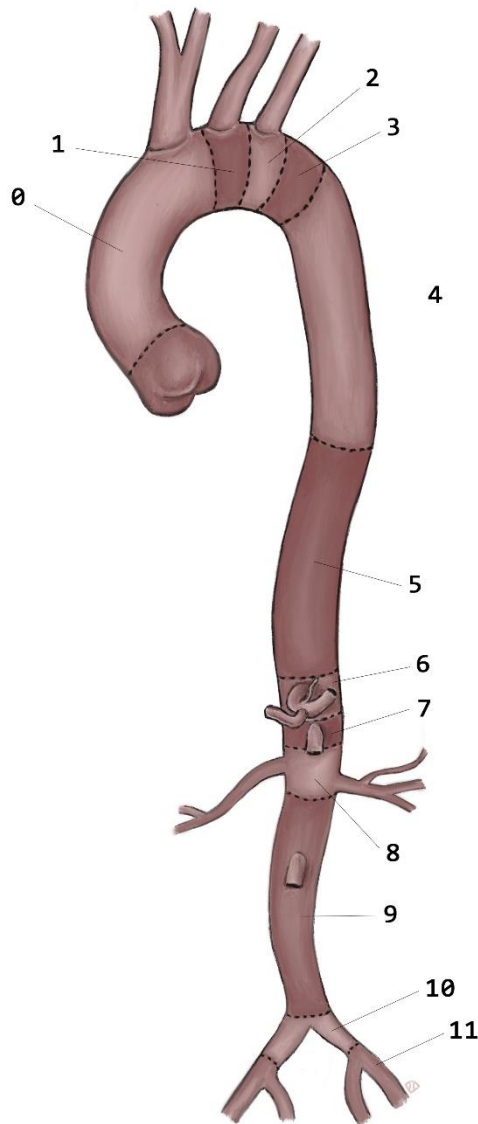


*Figure 5: Surgical debranching techniques for TEVAR-associated supra-aortic artery revascularization include extra-anatomical transposition and bypass. Transposition of the left subclavian and left common carotid arteries (A), left subclavian artery transposition (B), carotid-subclavian bypass (C). (By permission of Anna Kelemenné Polgár, Heart and Vascular Center, Semmelweis University)*

#### 1.4.1. Endovascular Repair of the Aorta

The first endovascular aortic intervention in history, more precisely a TEVAR of a traumatic pseudoaneurysm was performed in 1987 by Nicolai Volodos in Ukraine (43-45). Since then, revolutionary advances have been made in the field of aortic intervention. Endovascular repair of the aorta has evolved from a promising and innovative alternative to open surgery to the first-line treatment for most aortic diseases (3-5, 46, 47).

These procedures require precise pre-operative planning, with CTA based endograft sizing playing a key role of the preparation. Correct measurements of the aorta are crucial in order to avoid complications such as endoleaks or endograft migration (34, 48-50). For the exact planning of stent graft placement and determination of landing zones, the aorta and the iliac arteries have been divided into zones, originally based on the segments proposed by Ishimaru (51, 52). The aorto-iliac zonal subdivision begins at the ascending aorta (Z0) and terminates at the common iliac arteries distal to the iliac bifurcation (Z11) (4, 12, 14) [Figure 6].



*Figure 6: Aortic zones from the ascending aorta to the iliac arteries. (By permission of Anna Kelemenné Polgár, Heart and Vascular Center, Semmelweis University)*

Complex aortic interventions such as fenestrated and branched endovascular aneurysm repair (FEVAR and BEVAR) are becoming a widespread technique for the management of complex AAAs or TAAAs. FEVAR and BEVAR solutions may also be promising for thoracic aortic disease involving the ascending aorta and the arch (4, 14, 53-55).



#### 1.4.2. Aortic Pulsatility and Endovascular Repair Planning

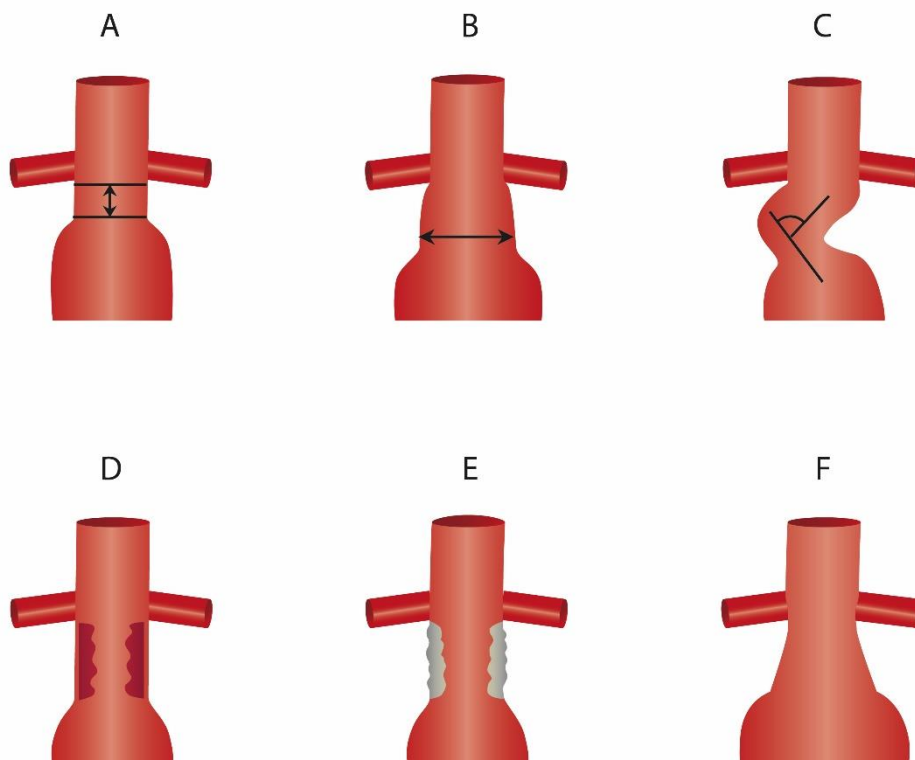
Recent technological advances in CT imaging have made it possible to perform rapid ECG-gated CTA of the entire aorta within a single breath. However, these innovations have introduced a new set of challenges: the dilemma of determining the optimal phase of the cardiac cycle for both image acquisition and subsequent reconstruction. Aortic dimensions can vary considerably due to the pulsatile motion of the vessel wall throughout the cardiac cycle, particularly in younger patients. (56).

In our previous studies our research group investigated the extent of pulsatility along the course of the aorta in elderly atherosclerotic patients. Subsequently, aortic pulsatility of younger patients has been evaluated focusing on the descending aorta. Nevertheless, the examined cohorts did not suffer from AA (57, 58). Aortic pulsatility in aneurysmatic patients has not yet been assessed.

In cases where there is a notable difference in aortic diameter between systole and diastole, there may be a potential risk of undersizing a stent graft. The pulsatile behaviour of aortic segments frequently employed as landing zones for EVAR raises potential concerns regarding complications like endograft migration or endoleaks. Furthermore, given the expanding application of TEVAR involving the ascending aorta as a landing zone, changes in diameter within this segment could become a notable consideration (56-58).

#### 1.4.3. Endoanchors in Endovascular Aortic Repair

Proximal fixation of the stent graft has a major impact on the success of EVAR. The term "hostile neck" is used to summarise all the anatomical features of the initial segment of the infrarenal aorta that compromise proximal fixation. Configurations that are considered as hostile neck include short, thrombotic, calcified, angulated, dilated and conical shaped necks (59, 60) [Figure 7].

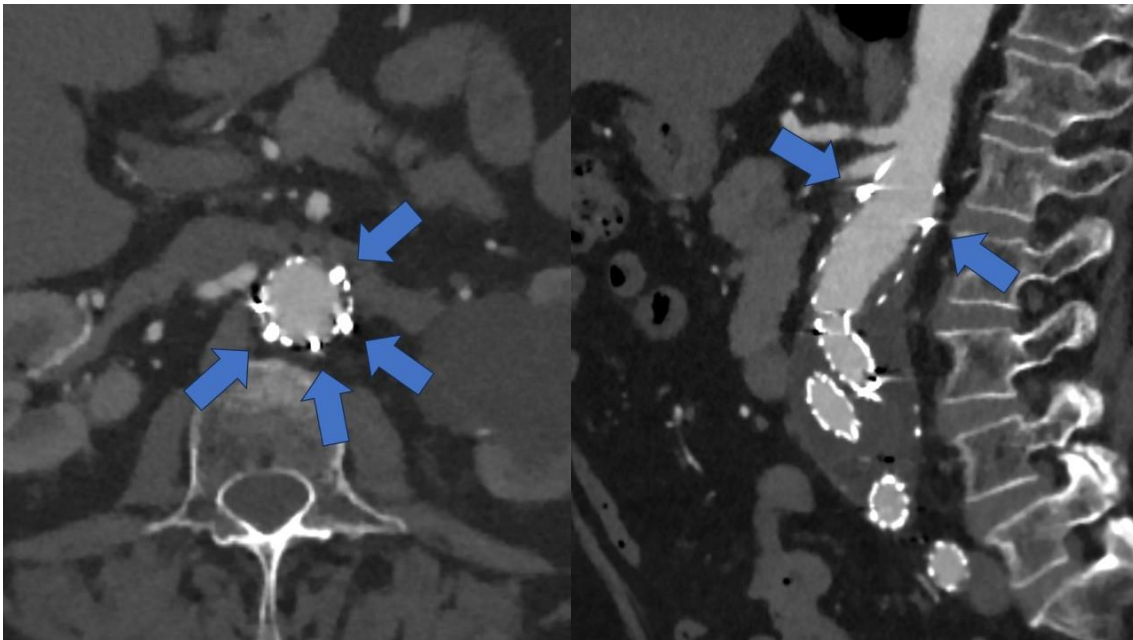


*Figure 7: The term „hostile neck” may refer to a short neck with  $<10$  mm length from the renal orifices (A); dilated neck with  $>28$  mm diameter (B); angulated neck with an angle of  $>60^\circ$  (C); thrombotic neck (D); calcified neck (E); or conical neck (F). (By permission of Zsófia Jokkel, Heart and Vascular Center, Semmelweis University)*

In EVAR cases featuring a hostile neck as a proximal landing zone, the use of endoanchors has become a promising technique in order to prevent type Ia endoleaks and endograft migration. The Heli-FX (Medtronic, Dublin, Ireland) endoanchor is a small corkscrew-shaped metal object that is implanted through a dedicated system. As the endoanchor is screwed inside the aortic wall through the textile material of the endograft, it further fixates the graft in the proximal landing zone of the aorta [Figures 8 and 9] (59, 60).



*Figure 8: Illustration of a Medtronic Heli-FX endoanchor. (By permission of Anna Kelemenné Polgár, Heart and Vascular Center, Semmelweis University)*



*Figure 9: Postoperative follow-up CTA scan after EVAR supplemented with Heli-FX endoanchors. Oblique planar reconstructions show endoanchors (arrows) screwed into the endograft in order to seal the proximal neck used as landing zone. (Image by the author)*

#### 1.4.4. Endovascular Aortic Repair in Hungary

In line with the prevailing trends in Europe and worldwide, endovascular aortic procedures are gradually becoming standard practice in vascular care in Hungary (61). Therefore, the analysis of data on aortic procedures performed in Hungarian centres is of

great importance. Keeping abreast of these European and global developments allows for a better understanding of the outcomes and effectiveness of aortic procedures performed in the country. This data analysis contributes to the advancement of vascular medicine in Hungary, ensuring that it remains aligned with the latest advances and best practices in the field.

## **2. Objectives**

Three studies on the current state of aortic disease management have contributed to this thesis, with the following objectives:

### **2.1. Aortic Pulsatility in Patients with AAA**

Pulsatile changes of aortic diameter between systole and diastole may pose a challenge in endograft sizing. In our first, retrospective study, the primary purpose of our research was to investigate aortic pulsatility in 31 patients with AAA. Our secondary goal was to examine the potential correlation between systolo-diastolic pulsatile changes of the aortic diameter and aneurysm growth rate.

### **2.3. Use of Endoanchors in EVAR in Hungary**

In our second, retrospective study, our purpose was to analyse the perioperative and early risk, as well as the success rate of EVAR with adjunct endoanchors in the Hungarian patient population. 14 cases of the procedure were examined.

### **2.4. TEVAR in Hungary Between 2012 and 2016**

In our third study, our aim was to create a national database with perioperative data and 5-year mortality outcome of 131 TEVAR cases performed in Hungary.

### 3. Methods

Our research was approved by the Semmelweis University Regional and Institutional Committee of Science and Research Ethics (92/2107; 93/2021; 95/2021). All studies were conducted with informed consent, in accordance with the Declaration of Helsinki.

#### 3.1. Aortic Pulsatility Assessment in Patients with AAA

In this retrospective, single-center study, we analyzed readily accessible images of 31 patients who underwent ECG-gated CTA as part of their routine AAA surveillance at the Semmelweis University Heart and Vascular Centre. For our research, we selected a cohort of patients who had undergone a minimum of two aortic CTA scans with a time interval of at least four years between them. The examinations utilized for this study were conducted between 24/11/2005, and 12/06/2020.

##### 3.1.1. CT Imaging

CTA scans were performed either with a 8-slice (GE Lightspeed Ultra, GE Healthcare, United States, 2005-2011) or a 256-slice multidetector scanner (Philips Brilliance iCT; Koninklijke Philips N.V., Best, The Netherlands 2011-2020). ECG gated scans were performed using 100 kV tube voltage. The acquired series covered the entire aorta and iliofemoral arteries. Non-ionic iodinated intravenous contrast media (Iomeron 400, Bracco Ltd, Milan, Italy) was administered at a flow rate of 4 to 5 mL/s.

Retrospective ECG-gating was used for a helical protocol, optimised to reduce, or possibly eliminate artefacts caused by pulsatile aortic motion. This technique allowed acquisition during both systolic and diastolic phases. Iterative reconstructions (iDose 5, Koninklijke Philips N.V., Best, The Netherlands) were performed with 1 mm slice thickness and 1 mm increments for every 10% of the R-R cycle, resulting in 10 image series per patient. For further analysis, the acquired image data was then transferred to a dedicated workstation.

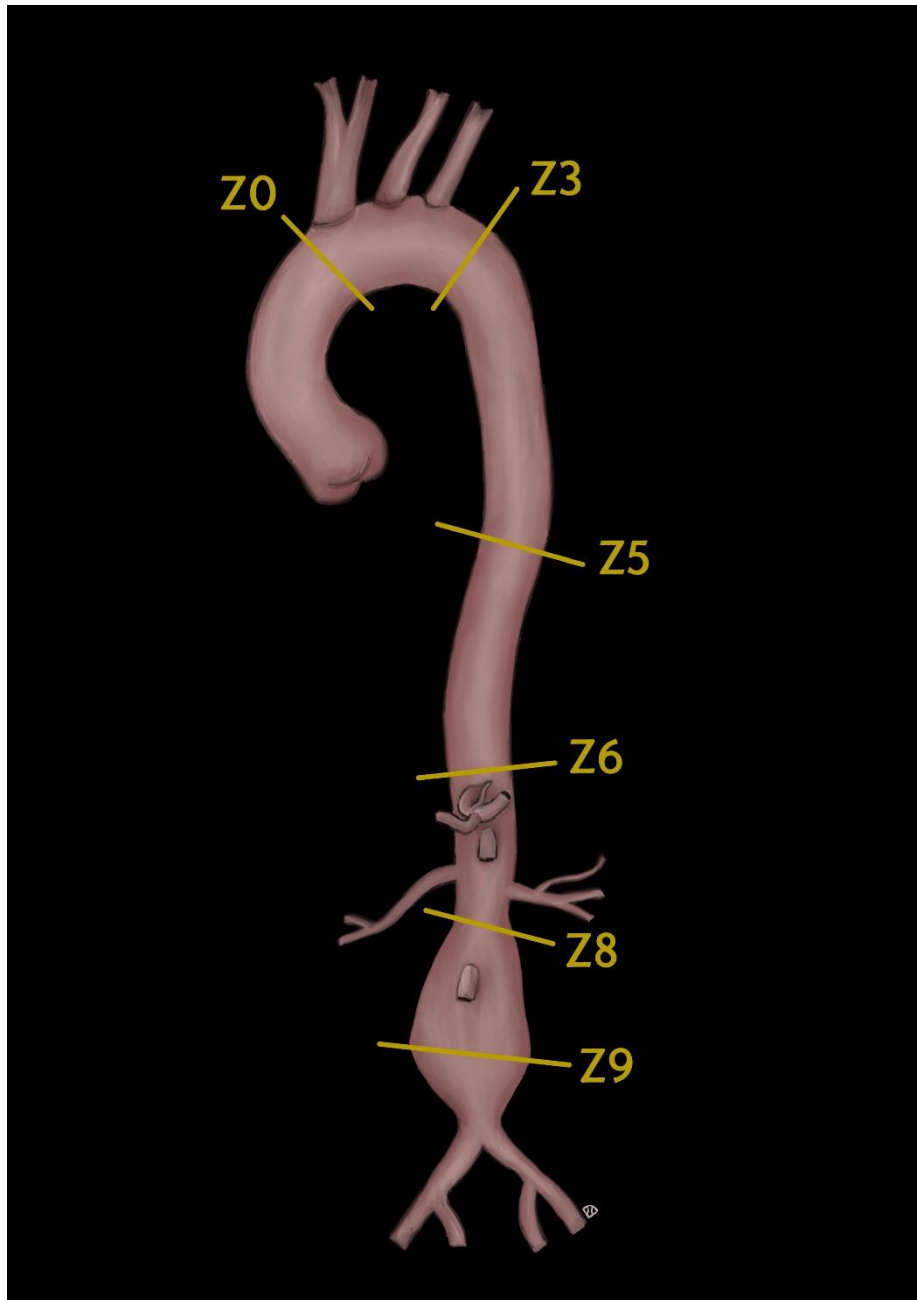
### 3.1.2. CT Image Analysis

CTA series were evaluated with 3mensio Vascular software (Pie Medical Imaging BV, Maastricht, Netherlands). After manually placing markers into the aortic root, bifurcation and common femoral arteries, automatic lumen segmentation was performed. An ellipsoid contour was manually drawn along the outer wall of the aorta, in the cross-sectional plane. This allowed the effective aortic diameter to be determined. Measurements were taken at various positions, including Z0 (1 cm proximal to the brachiocephalic trunk orifice), Z3 (distal to the origin of the left subclavian artery), Z5 (10 cm proximal to the celiac trunk orifice), Z6 (at the celiac trunk origin), Z8 (distal to the renal orifices), and Z9 (the largest diameter of the AAA) [Table 1, Figure 10].

As a part of our previous retrospective research that involved 28 elderly non-aneurysmatic patients, the R-R cycle was divided into 10% increments. Our results suggested that the largest aortic diameter is measured at 30% in systole, while the smallest aortic diameters could be measured in diastole at 90% of the cardiac cycle (58). Taking our previous findings into consideration, each measurement was made in both the systolic series at 30% of the R-R cycle and the diastolic phase at 90% [Figure 11]. The positions along the midline remained constant in both phases. A total of 24 measurements were obtained for each patient, resulting in a cumulative total of 744 pulsatility measurements.

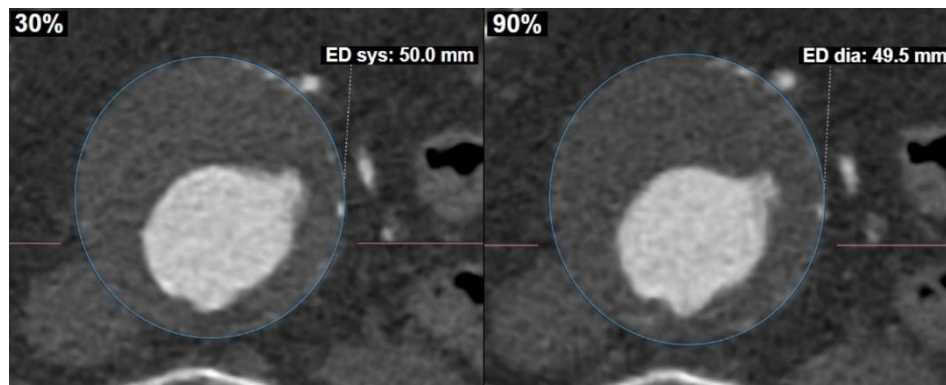
*Table 1: Measurement points.*

<i>Position along the aorta</i>	<i>Zone</i>
Proximal to the origin of the <b>brachiocephalic trunk</b>	Z0
Distal to the origin of the left <b>subclavian artery</b>	Z3
10 cm proximal from Z6	Z5
Proximal to the origin of the <b>celiac trunk</b>	Z6
Distal to the origin of the <b>renal arteries</b>	Z8
In the plane of the maximal diameter of the <b>AAA</b>	Z9



*Figure 10: Measurement points illustrated along the aorta. (By permission of Anna Kelemenné Polgár, Heart and Vascular Center, Semmelweis University)*





*Figure 11: Systolic (30%) and diastolic (90%) phase AAA effective diameter measured in the Z9 position. The difference of these values determines absolute pulsatility. (Image by the author)*

Absolute pulsatility refers to the numerical difference in millimeters (mm) between the effective diameters (EDs) of the vessel, measured in systole and diastole ( $ED_{sys} - ED_{dia}$ ). Relative pulsatility, on the other hand, is expressed as a percentage, calculated as the ratio of absolute pulsatility and the diastolic ED  $[(ED_{sys} - ED_{dia}) / ED_{dia}]$ .

The assessment of AAA expansion rate was conducted using CTA studies of the patients, which were performed independently from our research. These studies included baseline diagnostic scans as well as follow-up examinations for AAA surveillance.

### 3.2. Use of Endoanchors in EVAR in Hungary

In our retrospective, single-center study we analyzed data of patients who have undergone EVAR with adjunctive endoanchoring to treat hostile neck AAAs, performed at the Semmelweis University Heart and Vascular Centre. The following data were collected from the clinic's electronic and paper records: demographic and medical history data, index intervention and control examinations, as well as the results of imaging studies.

EVAR procedures utilizing the Heli-FX endoanchor system used for primary prophylactic indication were considered an index intervention [Figure 7]. Primary use was considered to be the case where the implantation of endoanchors was performed in one session with

the EVAR. A prophylactic indication is when the procedure is performed because of a hostile neck in order to minimize the chance of development of a short- or long-term proximal endoleak. The necks in which the diameter of the infrarenal aorta showed at least a 10% increase caudal to the renal orifices, were called conical. The neck was considered calcified or thrombotic in cases when it was affected on at least 50% of the aortic perimeter. Angulation was measured in degrees, by calculating the angle between the axis of the infrarenal neck and the terminal segment of the infrarenal aorta. The following AAA neck features were named „hostile neck”: a neck shorter than 10 mm or with a diameter greater than 28 mm, neck angulation above 60°, conical neck, thrombotic or calcified neck. The definition of technical and clinical success was determined in concordance with the SVS reporting standards (14). Technical success was defined as placement of the number of endoanchors deemed necessary by the physician, adequate penetration, no technical complications, and no type I or III endoleak at 30-day follow-up. Clinical success was characterized by the patient's survival without major adverse aorta-related events (such as rupture, AAA sac growth, type I or III endoleaks), or unrelated to the aorta (such as stroke, myocardial infarction, or renal failure).

Follow-up after EVAR was performed according to current guidelines (3). Depending on the results of the routine 30-day follow-up CTA, US or CTA was performed annually or more frequently if complications were suspected. The aneurysmal sac was considered unchanged, if no more than 5 mm change was observed from the baseline study. An increase in aortic diameter of more than 5 mm was considered to be enlargement, and shrinkage was defined as a decrease in aneurysm diameter of more than 5 mm. We recorded aneurysm sac diameter at baseline and follow-up. Mean follow-up time was 7.0 ± 9.9 month. We describe technical complications during the procedure by describing the success rate and mortality rate assessed on follow-up.

### 3.3. TEVAR in Hungary Between 2012 and 2016

In our retrospective, multicenter study, we collected perioperative and long-term data from all Hungarian tertiary centers that performed TEVAR between 01/01/2012 and 31/12/2016. Long-term mortality data were collected and verified via official death

records of the National Health Insurance Service to ensure data consistency and accuracy. Our data collected and systematized at the Semmelweis University Heart and Vascular Centre was supplemented with data provided by other major vascular centres: the Hungarian Defense Forces Medical Centre in Budapest, the University of Pécs Vascular Surgery Clinic, the University of Szeged Surgical Clinic, the Borsod-Abaúj-Zemplén County Hospital and University Teaching Hospital in Miskolc, and the Petz Aladár County Teaching Hospital in Győr. As a result, we have developed our dataset into a national database, which includes all TEVAR performed in Hungary in the above mentioned 5-year period. Long-term survival analysis was performed using Kaplan-Meier test.

#### 3.4. Statistical Analysis

Continuous variables were presented as either mean  $\pm$  standard deviation (SD) or median with interquartile ranges, while categorical variables were presented as numbers and percentages. Normality of continuous parameters was assessed using the Kolmogorov-Smirnov test. A paired t-test was used to compare systolic and diastolic measurements. One-way repeated measures analysis of variance (ANOVA) was used to compare absolute and relative pulsatility values along the aorta. Correlation between different continuous variables was assessed using Pearson correlation analysis. Two-sided  $p < 0.05$  was considered statistically significant for all evaluations. Kaplan-Meier analysis was conducted for mortality assessment. Calculations were performed using SPSS software (IBM, Armonk, NY, USA version 27.0).

## 4. Results

### 4.1. Aortic Pulsatility Assessment in Patients with AAA

806 measurements were conducted for assessing aortic pulsatility and AAA growth rate in a total of 31 patients (25 men) with a median age of 73 years. Demographic data is presented in Table 2.

Table 2: Demographic data. (IQR: Interquartile range)

<i>Patients data</i>	<i>n = 31</i>
Age, years (IQR)	73 (70-77)
Men, n (%)	25 (80.6)
BMI, kg/m <sup>2</sup> (IQR)	26.9 (24.7-29.8)
Active smokers, n (%)	9 (29.0)
Previous smokers, n (%)	26 (83.9)
Pack-years, years (IQR)	30 (10-40)
Hypertension, n (%)	28 (90.3)
hypercholesterinaemia, n (%)	24 (77.4)
Diabetes mellitus, n (%)	8 (25.8)
Chronic obstructive pulmonary disease, n (%)	17 (54.8)
Cardiac disease, n (%)	22 (30.1)
Peripheral arterial disease, n (%)	8 (25.8)
Chronic kidney disease, n (%)	13 (41.9)
Malignancy in patients' history, n (%)	5 (16.1)

At every measuring point, significantly larger maximum systolic diameters were observed compared to diastolic measurements: Z0: 34.82±2.96 mm versus 34.62±2.78 mm, Z3: 30.73±4.40 mm versus 30.31±3.27 mm, Z5: 28.53±2.97 mm versus 28.31±4.07 mm, Z6: 27.02±3.76 mm versus 27.00±3.22 mm, Z8: 23.97±4.61 mm versus 23.43±4.47 mm, Z9: 40.55±7.33 mm versus 39.90±7.33 mm, all with p<0.001.

The mean values for absolute and relative pulsatility were determined based on the dual measurements. There were no significant differences in the absolute pulsatility values between the measured positions, with the following mean values: Z0:  $0.7 \pm 0.8$  mm, Z3:  $1.0 \pm 0.6$  mm, Z5:  $1.0 \pm 0.6$  mm, Z6:  $0.8 \pm 0.7$  mm, Z8:  $0.7 \pm 1.0$  mm, Z9:  $0.9 \pm 0.9$  mm ( $p=0.62$ ).

While relative pulsatility values showed a tendency to decrease along the course of the aorta, the difference in these values was not statistically significant. The calculated relative pulsatility values were as follows Z0:  $2.3\% \pm 2.3\%$ , Z3:  $3.6\% \pm 2.1\%$ , Z5:  $3.6\% \pm 2.5\%$ , Z6:  $3.2\% \pm 2.5\%$ , Z8:  $2.9\% \pm 4.4\%$ , Z9:  $2.2\% \pm 2.2\%$ . Both absolute and relative aortic pulsatility peaked at Z3, with values of 1.0 mm and 3.6% respectively [Table 3] [Figures 12 and 13].

*Table 3: Absolute and relative pulsatility values.*

<i>position</i>	<i>absolute pulsatility (mm)</i>	<i>relative pulsatility (%)</i>
Z0	$0.7 \pm 0.8$	$2.3 \pm 2.3$
Z3	$1.0 \pm 0.6$	$3.6 \pm 2.1$
Z5	$1.0 \pm 0.6$	$3.6 \pm 2.5$
Z6	$0.8 \pm 0.7$	$3.2 \pm 2.5$
Z8	$0.7 \pm 1.0$	$2.9 \pm 4.4$
Z9	$0.9 \pm 0.9$	$2.2 \pm 2.2$

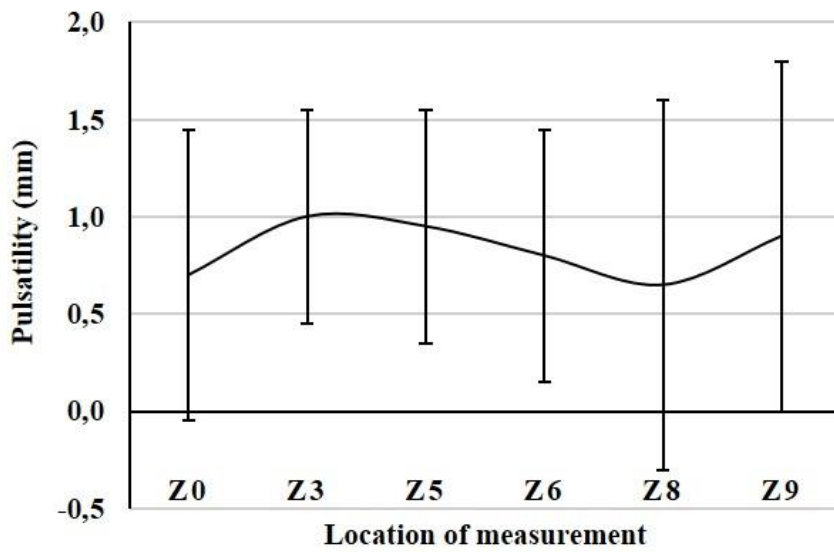


Figure 12: Absolute pulsatility values.

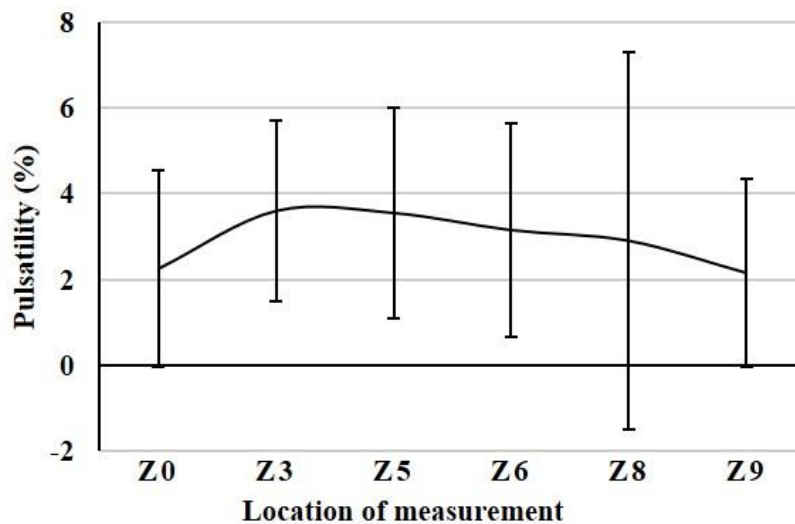


Figure 13: Relative pulsatility values.

During the evaluation of aneurysm growth rate, maximum diameters of the AAAs were recorded from baseline and latest preoperative follow-up images. The average time interval between the two examinations was  $5.5 \pm 2.2$  years. Throughout the follow-up period, all patients exhibited growth in the maximum diameter of their AAAs. The mean absolute diameter of the aneurysms changed from  $41.6 \pm 7.3$  mm to  $52.8 \pm 11.3$  mm during the observed time frame. The average extent of aneurysm growth was  $13.4 \pm 9.1$  mm over the observed period, equivalent to an average yearly growth rate of  $2.5 \pm 1.6$  mm, assuming that the growth rate of the AAAs was constant.

When examining the correlation between absolute or relative aortic pulsatility values at each position and the growth rate of the aneurysms, no significant associations were found.

#### 4.2. Use of Endoanchors in EVAR in Hungary

Between 01/01/2019, and 30/09/2021, a total of 214 EVAR were performed, of which 14 with adjunct Heli-FX endoanchors (6.5%), with prophylactic indication (11 men, mean age:  $70.4 \pm 8.1$  years). Demographic data is shown in Table 4, while the anatomical and surgical parameters are depicted in Table 5.

During the interventions, no technical complications occurred in any case. In one case in which endoanchors were used to treat an intraoperative type Ia endoleak, a smaller persisting type Ia endoleak was confirmed during the 30-day imaging control, but it disappeared by the 3-month control imaging examination as a result of conservative treatment (temporarily discontinuing the antiplatelet therapy). Therefore, the technical success rate was 92.9% (13/14).

The average initial aneurysm sac diameter of  $64.9 \pm 10.8$  mm decreased to  $60.6 \pm 11.8$  mm by the end of the  $7.0 \pm 9.9$ -month follow-up period, representing no significant change in the average diameter. Significant shrinkage was observed in 21.4% of the cases (3/14). In the remaining cases, the AAA was stable (11/14, 78.6%). Aneurysm sac growth was not shown in any of the cases (0/14, 0%). No mechanical complications were detected (endoanchor breakage or migration) during the follow-up period. We detected type II endoleaks in nearly half of the cases (6/14, 42.9%) during follow-up. Since none of these cases were associated with sac growth, conservative treatment was chosen. No reintervention took place (0/14, 0%). During follow-up, we lost one patient due to a complication unrelated to the aorta (in the 8th postoperative month; cause of death: myocardial infarction), hence our mortality rate is 7% (1/14), and our clinical success rate is 92.9% (13/14).

Table 4: Demographic data.

<b>Patient data</b>	<b>n=14</b>
Age, years	70,4 ± 8,1
Men, n (%)	11 (78,6)
Hypertension, n (%)	14 (100,0)
Diabetes mellitus, n (%)	0 (0,0)
Coronary artery disease, n (%)	3 (21,0)
Chronic obstructive pulmonary disease, n (%)	6 (43,0)
Active smokers, n (%)	8 (57,0)
Chronic kidney disease, n (%)	2 (14,0)
<b>Surgical risk groups:</b>	
ASA II, n (%)	3 (21,0)
ASA III, n (%)	8 (57,0)
ASA IV, n (%)	3 (21,0)



Table 5: Anatomical and surgical data.of the Heli-FX cohort

<b>Preoperative and surgical data</b>	<b>n=14</b>
AAA diameter (mm)	64.9 ± 10.8
Proximal neck length (mm)	12.2 ± 6.0
Proximal neck diameter (mm)	24.0 ± 4.1
Hostile neck, n (%)	12 (86.0)
Short neck, n (%)	7 (50.0)
Dilated neck, n (%)	2 (14.0)
Conical neck, n (%)	4 (29.0)
Severe angulation, n (%)	3 (21.0)
Thrombotic neck, n (%)	1 (7.0)
Calcified neck, n (%)	0 (0.0)
<b>Endograft type</b>	
Cook Zenith, n (%)	4 (29.0)
Gore Excluder, n (%)	1 (7.0)
Medtronic Endurant, n (%)	7 (50,0)
Terumo Treo, n (%)	2 (14,0)
Endograft diameter (mm)	28,1 ± 4,2
Endograft oversizing (%)	17,7 ± 4,9
No. of endoanchors used (n)	6,4 ± 1,7

#### 4.3. TEVAR in Hungary Between 2012 and 2016

In Hungary, between 01/01/2012 and 31/12/2016, a total of 131 TEVAR procedures were performed at the Semmelweis University Heart and Vascular Centre and 5 other major vascular centres. Table 6 shows the names of the institutions and the number of interventions carried out by them.

Table 6: Vascular Centres involved in our study.

<i>Vascular Centre</i>	<i>Number of procedures</i>
Semmelweis University Heart and Vascular Centre, Budapest	57
University of Pécs Vascular Surgery Clinic	25
Hungarian Defense Forces Medical Centre, Budapest	24
Borsod-Abaúj-Zemplén County Hospital and University Teaching Hospital, Miskolc	13
University of Szeged Surgical Clinic	7
Petz Aladár County Teaching Hospital, Győr	5

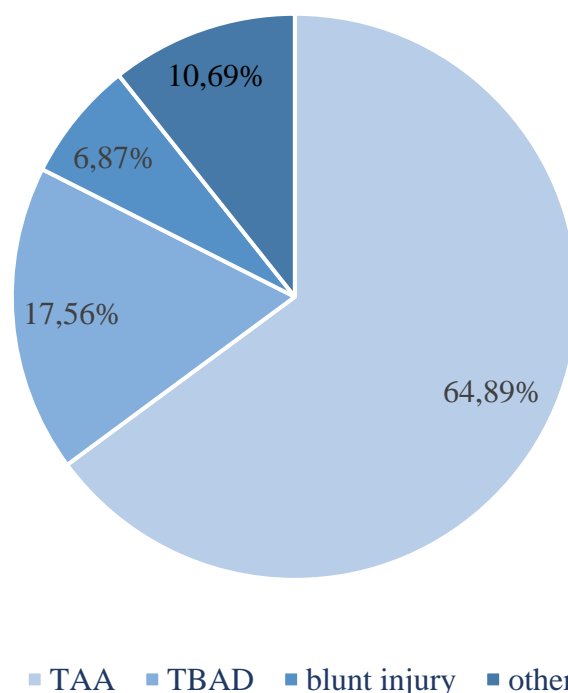
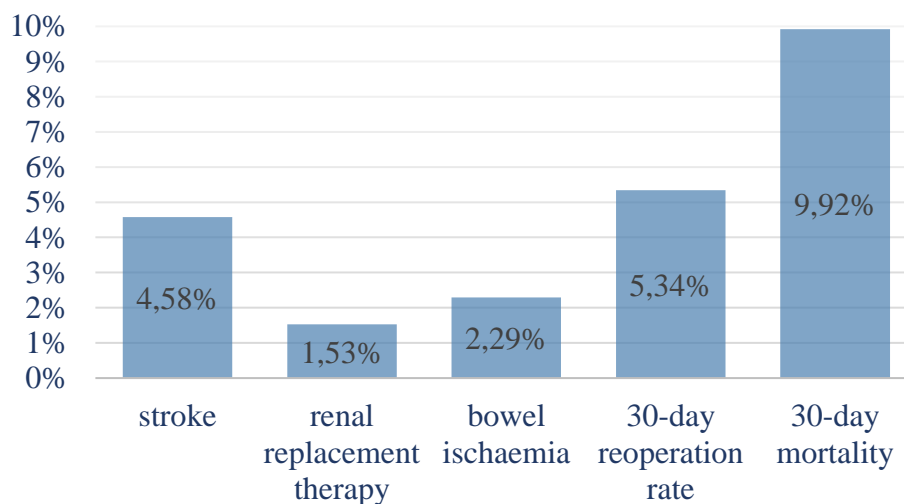


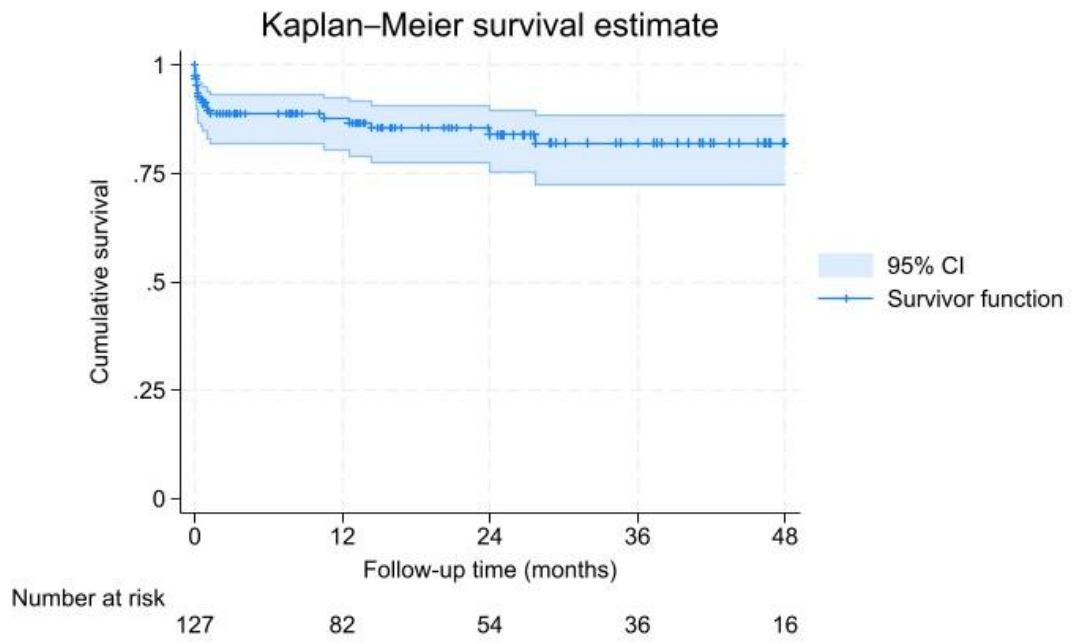
Figure 14: Indications for TEVAR in Hungary between 2012 and 2016.

The mean age of the patients undergoing the procedure was  $62.80 \pm 15.3$  years. 67.18% of the patients were male. The percentage of diabetic patients was 13.74%. The TEVAR was performed in an acute setting in 25.19% of cases, while it was elective in 74.81% of cases. Regarding the indications, TAA was the most common among the conditions requiring TEVAR, accounting for 64.89% of the procedures. TAA rupture was present in 16.47% of cases. TBAD was the second most common disease, which indicated 17.56% of TEVAR surgeries. Within the TBAD repairs, the proportion of acute interventions was 73.91%. In 6.87% of all cases, the indication for implantation was blunt thoracic aortic injury, while in the remaining 10.69%, TEVAR was required for other reasons (postoperative endoleak, IMH, PAU) [Figure 14]. Debranching surgery on the supra-aortic branches was performed in 26.72% of the endograft implantations.

In the early postoperative period, stroke occurred in 4.58% of cases, temporary renal replacement therapy was required in 1.53% of cases during postoperative intensive therapy, and bowel ischemia developed in 2.29%. Within 30 days after TEVAR, reoperation was needed in 5.34% of patients. Mortality within 30 days was 9.92% [Figure 15]. In the examined 5-year follow-up period, long-term mortality was 16.03% [Figure 16].



*Figure 15: Rate of postoperative complications after TEVAR in Hungary between 2012 and 2016.*



*Figure 16: Kaplan-Meier curve demonstrating long-term mortality after TEVAR.*

## 5. Discussion

Through our retrospective studies focusing on preoperative planning and the status quo of specific endovascular aortic repair in Hungary, we have identified noteworthy findings that hold potential regarding future advancements in the management of aortic diseases.

The extent of aortic pulsatile motion though the cardiac cycle was determined in patients with AAAs, resulting in a maximal absolute pulsatility of 1 mm and relative pulsatility not reaching 5%. Moreover, no correlation was found between aortic pulsatility and the growth rate of the aneurysms. Concerning the current state of endovascular aortic repair in our country, a comprehensive analysis was conducted on EVAR with adjunct endoanchors performed at Semmelweis University Heart and Vascular Centre. Furthermore, detailed data was obtained on TEVAR performed in all major aortic centres in Hungary between 2012 and 2016.

Pulsatile motion of the aorta causing potential issues regarding pre-operative planning has been a subject of several publications in the past decade. Parodi et al. observed notable differences between systolic and diastolic diameters at various points along the descending aorta (56). This finding suggested the preferential use of systolic phase CTA images for accurate sizing of stent grafts. It has been assumed that planning based solely on diastolic images could potentially result in endograft undersizing, which increases the risk of complications like type Ia endoleaks or distal migration (62). This finding carries particular importance as diastolic phase CTA images are routinely relied upon in pre-operative planning for EVAR and TEVAR, as they are less affected by pulsation artifacts (63).

Our previous investigations have demonstrated that pulsatility is not significant in both elderly individuals without relevant aortic disease and younger patients measured on the thoracic aorta. The elderly, atherosclerotic cohort we analyzed did not have AAAs. Aortic pulsatility was not clinically significant in this population, with the highest values observed in Z3 (58). Considering the study's suggestion that younger individuals might be at higher risk of undersizing, our subsequent research focused on younger patients. We found increased pulsatile motion in this group compared to the elderly population.

However, the extent of pulsatility in the descending aorta was still not relevant in relation to endograft sizing (57).

Patients followed and treated with AAA exhibited similarly low aortic pulsatility compared to the non-aneurysmatic population, with pulsatility rarely exceeding 1 mm. It is worth mentioning that the aneurysmatic segment of the aorta did not exhibit any significant changes compared to other segments. Notably, the highest absolute and relative pulsatility measurements were consistently observed in Z3, in every population involved in our investigations. Therefore, according to our measurements, pulsatile changes in the ascending aorta are lower than those observed in the proximal descending aorta. As endovascular repair of the aortic arch becomes more widely accepted and accessible (64-67), our data obtained on the proximal aortic zones may be relevant regarding arch stent graft sizing, suggesting that the standard oversizing of endografts should not be further increased in case of a Z0 proximal fixation zone.

It is important to note that the two major manufacturers of branched stent grafts for aortic arch repair have marginally different approaches to sizing the proximal landing zone. Terumo Aortic recommends a slightly higher oversize (15%-20%) in Z0 compared to other aortic segments, while Cook Medical generally recommends the same degree of oversize (15%-20%) through the whole course of the aorta (Niewijk E., Trompler J., written personal communication, 6.12.2021).

The prediction of AAA growth has been studied extensively, primarily because of the relationship between maximum diameter and the risk of rupture (68-71). Recognising the importance of this issue, our aim was to investigate the potential correlation between aortic pulsatility, as measured in subsequent follow-up CT studies, and the rate of expansion of AAA. Although we observed growth in each patient's AAA during the follow-up period, we did not find a statistically significant association between aortic pulsatility values and the rate of aneurysm growth.

EVAR for infrarenal AAAs with favorable proximal fixation zone has already been recommended in previous guidelines, however most cases with more challenging necks have been directed towards open surgery (72, 73). Due to recent advancements in endovascular treatment of complex AAs, procedures such as EVAR, TEVAR, FEVAR, BEVAR and the use of physician-modified endografts are increasingly considered as

feasible alternatives to open surgical repair in patients with more complex aneurysms (3-5, 14, 74).

Such complex cases include patients treated with juxtarenal AA. The treatment of infrarenal AAs with short proximal necks has been challenging from the beginning. In the early days, alternative methods such as parallel grafts and fenestrated endografts emerged as novel techniques (55, 75). The use of endoanchors is technically simpler, eliminating the need for selective catheterization of the renal arteries and the use of covered stents, which are typically required in the aforementioned approach. The effectiveness of this method was first reported in 2012 (76). Subsequently, numerous publications were written based on the data of the ANCHOR (Aneurysm Treatment Using the Heli-FX Aortic Securement System Global Registry) registry. Based on this dataset, it has been proposed that endoanchors may be protective against postoperative dilatation of the proximal neck, which is related to the diameter of the aorta and the degree of endograft oversizing (77).

In one of the first articles from the prospective, international registry sponsored by the manufacturer, a technical success rate of 96.6% and a similar freedom from type Ia endoleak (96.5%) were reported in cases where the use of endoanchors was prophylactic (60). In our own study, we achieved similar results. Fracture of the endoanchors has been reported as a very rare complication in a follow-up period averaging 14 months (3/1118, 0.3%) (59). In our own study with a significantly smaller cohort, this complication did not occur.

According to an analysis based on matched cohort comparison, it has been demonstrated that after EVAR supplemented with endoanchors, there is a larger proportionate aneurysm sac diameter decrease compared to the control group, and that the use of endoanchors may mitigate the adverse effect of wide infrarenal necks and neck thrombus (78).

Although the presented literature confirms the efficacy and safety of the method in the treatment of juxtarenal aneurysms, the current 2019 guidelines of the ESVS only recommend the use of the method in clinical trials for the time being due to the lack of sufficiently strong evidence (randomized trial or meta-analysis) (3). Nevertheless, more recent studies have been published on the subject, with promising results. A meta-analysis has been published in 2020 with a patient group treated with primary prophylactic

indication. In this population, the combined technical success rate was 98.4%, while the occurrence of proximal endoleak was 3.5% during the average follow-up period of 15 months. Total mortality was 0.8% (79). In our study with a low number of cases, we obtained similar results: we found a technical success rate above 90%, with a type Ia endoleak occurring in one case, which could be managed with conservative treatment alone, without significant complications and mortality.

A recent study, based on data from the largest international registry examining the use of the Heli-FX system (PERU registry), shows promising mid-term results in terms of technical success rate (95.5%) and freedom from type Ia endoleak (96%) (80). Our center also participates in the ongoing data collection for the PERU registry.

The collection of data on endovascular procedures conducted at our university is of utmost importance. However, systematically gathering and analyzing data from all major cardiovascular centers across Hungary assumes even greater significance in shaping the future perspectives and advancements in aortic disease management. In our study summarizing TEVAR procedures between 2012 and 2016, the primary objective was to obtain a comprehensive picture of short-term perioperative outcomes of thoracic stent graft implantations in Hungary and long-term procedural outcomes. Previously, there was no report on this topic.

In Hungary, during the examined time period, a total of 131 TEVARs were performed. The number of surgeries and the average age of our patients who underwent the procedure (62.80 years) is lower than the results of similar European studies (81). The average age of the patients in our study includes young patients who suffered blunt aortic trauma, explaining the lower value and wider standard deviation in our country. Our data correlate with the results of the Hungarian Society for Angiology and Vascular Surgery Vascular Registry in 2013: in addition to aortic repair, it also processed the data of carotid artery reconstructions and lower limb artery surgeries. In the registry, the age group most affected by vascular surgery was also between 60-70 (82).

An interesting piece of data is the proportion of diabetes in history, which does not exceed 13.74%. This might confirm that diabetes mellitus, which is known to inhibit the development and progression of AAAs, negatively affects the development of TAAs through the same molecular mechanism, resulting in the low proportion of diabetics in



our study (83). The rate of acute interventions was 25.19%. It is important to highlight that endovascular aortic repair requires personalized, precise preoperative planning, therefore it is necessary to have appropriate logistics available at all times in the centers performing emergent procedure. In almost two-thirds (64.89%) of the cases the indication for TEVAR was TAA. Our results show that most procedures performed to treat aneurysms were elective, and rupture was only present in 16.47% of cases, which represents a significantly higher risk state in terms of short-term mortality.

After TAA, the second most common indication for TEVAR was complicated TBAD. In this condition, the rate of acute interventions is much higher (73.91%), as AD localized on the descending aorta is a surgical indication if it presents acutely with complications, or in cases where a chronic, non-complicated AD becomes complicated by rapid progression. Blunt trauma of the thoracic aorta indicated 6.87% of the interventions in the examined period. This life-threatening rare condition, which mostly affects young people, is also primarily treated with TEVAR (4, 5, 11). In addition to the aforementioned conditions, in 10.69% of the cases, TEVAR was performed for miscellaneous reasons. In this group, the indication was mostly endoleak, which appeared as a long-term complication of previous stent graft implantations and required reoperation. It is important to note in this regard that the regular CT follow-up of patients undergoing TEVAR is of paramount importance for early detection and treatment of these complications (84).

In 26.72% of the interventions, additional debranching surgery was performed on the supra-aortic branches. In the case of elective interventions, the aim should be the most perfect revascularization possible, because even just the coverage of the origin of the left subclavian artery can lead to neurological complications (spinal cord ischemia, stroke) or upper limb ischemia. This is provided by debranching surgery performed intraoperatively or preoperatively in a separate session. or more recent endovascular procedures involving the arch gaining ground worldwide, which can avoid open surgical reconstruction and ensure the perfusion of supra-aortic branches (74, 85-88).

Comparing the incidence of perioperative stroke (4.58%) and 30-day mortality (9.92%) to the current ESVS guidelines (5), it can be observed on the one hand, that the postoperative stroke incidence was lower than the European average (5.4%), while short-

term mortality approaches the European average, which is 5.57% for TAA and between 2.6% and 9.8% for AD. On the other hand, it is notable that, according to European data, TEVAR is a more advantageous procedure in terms of both short-term mortality and postoperative stroke incidence than open thoracic aortic surgical procedures, for which the incidence of postoperative stroke reaches 14%, and short-term mortality is 16.5% for TAA and 25-50% for cases of AD. Domestic data comparing TEVAR with open surgical procedures are not yet available (5).

The 5-year mortality reached 16.03%. The occasional inaccuracy of follow-up and the sometimes-inadequate amount of long-term postoperative information available on patients limited the precision of our data collection. As a result, it cannot be precisely judged whether the existing aortic disease was the cause of death in the case of patients who died between the first 30 postoperative days and the end of follow-up.

### 5.1. Study Limitations

Regarding CT measurements, while CTA stands as the preferred imaging method for preoperative aortic assessment in AAA patients, it often presents limitations in directly visualizing the vessel wall. In cases where clear landmarks like atherosclerotic or thrombotic changes are absent, the contour of the contrast agent-filled lumen becomes the sole measurable boundary between the aorta and surrounding tissues. Consequently, accurately identifying the exact location along the aorta for diameter measurements in two phases within an R-R' cycle can pose challenges.

Nonetheless, the CT equipment's spatial (0.625 mm) and temporal (0.270 seconds) resolution ensures that two images captured at identical table positions but in different phases are highly likely to represent the same point along the aortic centerline. Furthermore, the reliability of the adopted image evaluation method is supported by the interobserver and intraobserver variabilities assessed during our previous studies, which demonstrated the excellent accuracy of the process.

It is important to note that these retrospective studies, conducted on relatively small cohorts, leave room for further investigations involving a larger number of patients to delve deeper into the subject.

## 6. Conclusions

Our research has provided important insights into the state-of-the-art planning of endovascular aortic interventions and the current status quo of this field in Hungary.

Aortic pulsatility is generally less than 1 mm (5%). Therefore, the commonly used 10-20% oversizing in EVAR planning may be sufficient and the use of systolic phase images instead of diastolic phase images for stent graft sizing is likely not necessary. The need for further oversizing for a landing zone on the ascending aorta is questionable. There is no apparent correlation between aortic pulsatility and the long-term expansion rate of aneurysms, suggesting that this parameter is unlikely to serve as a predictor of AAA growth.

We also confirmed the effectiveness of the national use of endoanchors during EVAR performed on patients with a hostile neck. We found high technical and clinical success rate during the early follow-up, and a low complication rate, without mortality related to the aorta. The method can be used successfully and safely for the endovascular treatment of juxtarenal aneurysms.

TEVAR is a reliable and successful method for the modern treatment of thoracic aortic diseases. National data support the advantages of endovascular intervention over open surgery. Multidisciplinary collaboration is needed to ensure that our patients can receive the highest level of care currently available.

## 7. Summary

Significant advancements have been made in the diagnosis and treatment of aortic disease over the past few decades. Advanced imaging techniques such as ECG-gated CTA have brought about a revolutionary shift in diagnostic capabilities, allowing for more accurate and detailed assessments of aortic pathologies. Endovascular aortic repair techniques, which were once regarded as a promising new procedure, have now emerged as the preferred and primary choice for treating aortic disease, including complex cases.

It has been discussed that pulsatile motion of the aorta might affect endograft sizing. Aortic pulsatility has not previously been evaluated in patients with AAA. Our results based on 31 patients show that systolo-diastolic changes in aortic diameter measured during the cardiac cycle are generally in a submillimetric range ( $< 5\%$ ), thus unlikely to affect endograft oversizing, which is already regularly used for preoperative planning. We found no correlation between pulsatility and aneurysm growth rate, suggesting that aortic pulsatility is not a good predictor of aneurysm progression.

Previous international data has indicated that TEVAR and EVAR with adjunct endoanchors yield favorable outcomes and are considered reliable procedures. However, up to now there has been no domestic data from Hungary on this subject. In our studies, we aimed to provide data specific to Hungary regarding the reliability and outcomes of the aforementioned procedures.

During the examined time periods, 131 TEVAR procedures were performed, while endoanchors were used in 14 cases. We confirmed that TEVAR and EVAR supplemented with endoanchors are indeed reliable procedures with favorable outcomes in Hungary, aligning with the international findings. Our studies contribute valuable domestic data to the existing body of evidence, reinforcing the validity and applicability of these procedures within the Hungarian healthcare context.

Our results hold significant importance for the future advancements in diagnostics and treatment of patients with aortic disease. By expanding the knowledge base and understanding of aortic disease, our findings contribute to ongoing efforts to improve patient care, optimize outcomes, and advance the field of aortic disease management.

## 8. References

1. Francois CJ, Skulborstad EP, Majdalany BS, Chandra A, Collins JD, Farsad K, et al. ACR Appropriateness Criteria(®) Abdominal Aortic Aneurysm: Interventional Planning and Follow-Up. *J Am Coll Radiol*. 2018;15(5s):S2-s12.
2. Contrella BN, Khaja MS, Majdalany BS, Kim CY, Kalva SP, Beck AW, et al. ACR Appropriateness Criteria® Thoracoabdominal Aortic Aneurysm or Dissection: Treatment Planning and Follow-Up. *J Am Coll Radiol*. 2023;20(5s):S265-s84.
3. Wanhainen A, Verzini F, Van Herzele I, Allaire E, Bown M, Cohnert T, et al. Editor's Choice - European Society for Vascular Surgery (ESVS) 2019 Clinical Practice Guidelines on the Management of Abdominal Aorto-iliac Artery Aneurysms. *Eur J Vasc Endovasc Surg*. 2019;57(1):8-93.
4. Czerny M, Schmidli J, Adler S, van den Berg JC, Bertoglio L, Carrel T, et al. Editor's Choice - Current Options and Recommendations for the Treatment of Thoracic Aortic Pathologies Involving the Aortic Arch: An Expert Consensus Document of the European Association for Cardio-Thoracic Surgery (EACTS) & the European Society for Vascular Surgery (ESVS). *Eur J Vasc Endovasc Surg*. 2019;57(2):165-98.
5. Riantbau V, Böckler D, Brunkwall J, Cao P, Chiesa R, Coppi G, et al. Editor's Choice - Management of Descending Thoracic Aorta Diseases: Clinical Practice Guidelines of the European Society for Vascular Surgery (ESVS). *Eur J Vasc Endovasc Surg*. 2017;53(1):4-52.
6. Townsend N, Wilson L, Bhatnagar P, Wickramasinghe K, Rayner M, Nichols M. Cardiovascular disease in Europe: epidemiological update 2016. *Eur Heart J*. 2016;37(42):3232-45.
7. Kesteloot H, Sans S, Kromhout D. Dynamics of cardiovascular and all-cause mortality in Western and Eastern Europe between 1970 and 2000. *Eur Heart J*. 2006;27(1):107-13.
8. Hungarian Central Statistical Office: Number and proportion of deaths by cause of death groups, 1949–2007; Retrieved 2023 Jun 21 [www.ksh.hu/docs/hun/xtabla/halalozasok/tablha07\\_01.html](http://www.ksh.hu/docs/hun/xtabla/halalozasok/tablha07_01.html) [

9. Sampson UK, Norman PE, Fowkes FG, Aboyans V, Yanna S, Harrell FE, Jr., et al. Global and regional burden of aortic dissection and aneurysms: mortality trends in 21 world regions, 1990 to 2010. *Glob Heart*. 2014;9(1):171-80.e10.
10. Cronenwett JL JK. *Rutherford's Vascular Surgery*. Eighth Edition ed. Philadelphia, USA: Elsevier Saunders; 2014.
11. Erbel R, Aboyans V, Boileau C, Bossone E, Bartolomeo RD, Eggebrecht H, et al. 2014 ESC Guidelines on the diagnosis and treatment of aortic diseases: Document covering acute and chronic aortic diseases of the thoracic and abdominal aorta of the adult. The Task Force for the Diagnosis and Treatment of Aortic Diseases of the European Society of Cardiology (ESC). *Eur Heart J*. 2014;35(41):2873-926.
12. Fillinger MF, Greenberg RK, McKinsey JF, Chaikof EL. Reporting standards for thoracic endovascular aortic repair (TEVAR). *J Vasc Surg*. 2010;52(4):1022-33, 33.e15.
13. Chaikof EL, Blankensteijn JD, Harris PL, White GH, Zarins CK, Bernhard VM, et al. Reporting standards for endovascular aortic aneurysm repair. *J Vasc Surg*. 2002;35(5):1048-60.
14. Oderich GS, Forbes TL, Chaer R, Davies MG, Lindsay TF, Mastracci T, et al. Reporting standards for endovascular aortic repair of aneurysms involving the renal-mesenteric arteries. *J Vasc Surg*. 2021;73(1s):4s-52s.
15. Kent KC, Zwolak RM, Egorova NN, Riles TS, Manganaro A, Moskowitz AJ, et al. Analysis of risk factors for abdominal aortic aneurysm in a cohort of more than 3 million individuals. *J Vasc Surg*. 2010;52(3):539-48.
16. Lederle FA, Johnson GR, Wilson SE, Chute EP, Hye RJ, Makaroun MS, et al. The aneurysm detection and management study screening program: validation cohort and final results. Aneurysm Detection and Management Veterans Affairs Cooperative Study Investigators. *Arch Intern Med*. 2000;160(10):1425-30.
17. Golledge J, Muller J, Daugherty A, Norman P. Abdominal aortic aneurysm: pathogenesis and implications for management. *Arterioscler Thromb Vasc Biol*. 2006;26(12):2605-13.

18. DeBakey ME, Henly WS, Cooley DA, Morris GC, Jr., Crawford ES, Beall AC, Jr. Surgical Management of Dissecting Aneurysms of the Aorta. *J Thorac Cardiovasc Surg.* 1965;49:130-49.
19. Daily PO, Trueblood HW, Stinson EB, Wuerflein RD, Shumway NE. Management of acute aortic dissections. *Ann Thorac Surg.* 1970;10(3):237-47.
20. Juraszek A, Czerny M, Rylski B. Update in aortic dissection. *Trends Cardiovasc Med.* 2022;32(7):456-61.
21. Sievers HH, Rylski B, Czerny M, Baier ALM, Kreibich M, Siepe M, Beyersdorf F. Aortic dissection reconsidered: type, entry site, malperfusion classification adding clarity and enabling outcome prediction. *Interact Cardiovasc Thorac Surg.* 2020;30(3):451-7.
22. Dake MD, Thompson M, van Sambeek M, Vermassen F, Morales JP. DISSECT: a new mnemonic-based approach to the categorization of aortic dissection. *Eur J Vasc Endovasc Surg.* 2013;46(2):175-90.
23. Lombardi JV, Hughes GC, Appoo JJ, Bavaria JE, Beck AW, Cambria RP, et al. Society for Vascular Surgery (SVS) and Society of Thoracic Surgeons (STS) reporting standards for type B aortic dissections. *J Vasc Surg.* 2020;71(3):723-47.
24. Hagan PG, Nienaber CA, Isselbacher EM, Bruckman D, Karavite DJ, Russman PL, et al. The International Registry of Acute Aortic Dissection (IRAD): new insights into an old disease. *Jama.* 2000;283(7):897-903.
25. Di Eusanio M, Trimarchi S, Patel HJ, Hutchison S, Suzuki T, Peterson MD, et al. Clinical presentation, management, and short-term outcome of patients with type A acute dissection complicated by mesenteric malperfusion: observations from the International Registry of Acute Aortic Dissection. *J Thorac Cardiovasc Surg.* 2013;145(2):385-90.e1.
26. Gilon D, Mehta RH, Oh JK, Januzzi JL, Jr., Bossone E, Cooper JV, et al. Characteristics and in-hospital outcomes of patients with cardiac tamponade complicating type A acute aortic dissection. *Am J Cardiol.* 2009;103(7):1029-31.

27. Januzzi JL, Eagle KA, Cooper JV, Fang J, Sechtem U, Myrmet T, et al. Acute aortic dissection presenting with congestive heart failure: results from the International Registry of Acute Aortic Dissection. *J Am Coll Cardiol*. 2005;46(4):733-5.
28. Rubano E, Mehta N, Caputo W, Paladino L, Sinert R. Systematic review: emergency department bedside ultrasonography for diagnosing suspected abdominal aortic aneurysm. *Acad Emerg Med*. 2013;20(2):128-38.
29. Dent B, Kendall RJ, Boyle AA, Atkinson PR. Emergency ultrasound of the abdominal aorta by UK emergency physicians: a prospective cohort study. *Emerg Med J*. 2007;24(8):547-9.
30. Lindholt JS, Vammen S, Juul S, Henneberg EW, Fasting H. The validity of ultrasonographic scanning as screening method for abdominal aortic aneurysm. *Eur J Vasc Endovasc Surg*. 1999;17(6):472-5.
31. Mirza TA, Karthikesalingam A, Jackson D, Walsh SR, Holt PJ, Hayes PD, Boyle JR. Duplex ultrasound and contrast-enhanced ultrasound versus computed tomography for the detection of endoleak after EVAR: systematic review and bivariate meta-analysis. *Eur J Vasc Endovasc Surg*. 2010;39(4):418-28.
32. Zaiem F, Almasri J, Tello M, Prokop LJ, Chaikof EL, Murad MH. A systematic review of surveillance after endovascular aortic repair. *J Vasc Surg*. 2018;67(1):320-31.e37.
33. Agarwal PP, Chughtai A, Matzinger FR, Kazerooni EA. Multidetector CT of thoracic aortic aneurysms. *Radiographics*. 2009;29(2):537-52.
34. Parker MV, O'Donnell SD, Chang AS, Johnson CA, Gillespie DL, Goff JM, et al. What imaging studies are necessary for abdominal aortic endograft sizing? A prospective blinded study using conventional computed tomography, aortography, and three-dimensional computed tomography. *J Vasc Surg*. 2005;41(2):199-205.
35. Murillo H, Molvin L, Chin AS, Fleischmann D. Aortic Dissection and Other Acute Aortic Syndromes: Diagnostic Imaging Findings from Acute to Chronic Longitudinal Progression. *Radiographics*. 2021;41(2):425-46.



36. Sun Z, Ng KH. Prospective versus retrospective ECG-gated multislice CT coronary angiography: a systematic review of radiation dose and diagnostic accuracy. *Eur J Radiol.* 2012;81(2):e94-100.
37. Berczeli M, Chinnadurai P, Osztrogonác P, Peden EK, Bavare CS, Sótónyi P, et al. Dynamic Computed Tomography Angiography is More Accurate in Diagnosing Endoleaks than Standard Triphasic Computed Tomography Angiography and Enables Targeted Embolization. *Ann Vasc Surg.* 2023;88:318-26.
38. Berczeli M, Lumsden AB, Chang SM, Bavare CS, Chinnadurai P. Dynamic, Time-Resolved Computed Tomography Angiography Technique to Characterize Aortic Endoleak Type, Inflow and Provide Guidance for Targeted Treatment. *J Endovasc Ther.* 2022;29(1):11-22.
39. Berczeli M, Chinnadurai P, Legeza P, Peden EK, Bavare CS, Chang SM, Lumsden AB. Dynamic, Time-Resolved CT Angiography After EVAR: A Quantitative Approach to Accurately Characterize Aortic Endoleak Type and Identify Inflow Vessels. *J Endovasc Ther.* 2023;30(1):123-31.
40. Higashigaito K, Mergen V, Eberhard M, Jungblut L, Hebeisen M, Rätzer S, et al. CT Angiography of the Aorta Using Photon-counting Detector CT with Reduced Contrast Media Volume. *Radiol Cardiothorac Imaging.* 2023;5(1):e220140.
41. Csöre J, Suhai FI, Gyánó M, Pataki Á A, Juhász G, Vecsey-Nagy M, et al. Quiescent-Interval Single-Shot Magnetic Resonance Angiography May Outperform Carbon-Dioxide Digital Subtraction Angiography in Chronic Lower Extremity Peripheral Arterial Disease. *J Clin Med.* 2022;11(15).
42. van Hout MJ, Scholte AJ, Juffermans JF, Westenberg JJ, Zhong L, Zhou X, et al. How to Measure the Aorta Using MRI: A Practical Guide. *J Magn Reson Imaging.* 2020;52(4):971-7.
43. Volodos NL, Karpovich IP, Shekhanin VE, Troian VI, Iakovenko LF. [A case of distant transfemoral endoprosthesis of the thoracic artery using a self-fixing synthetic prosthesis in traumatic aneurysm]. *Grudn Khir.* 1988(6):84-6.

44. Volodos NL. Historical perspective: The first steps in endovascular aortic repair: how it all began. *J Endovasc Ther.* 2013;20 Suppl 1:13-23.
45. Volodos NL, Shekhanin VE, Karpovich IP, Troian VI, Gur'ev Iu A. [A self-fixing synthetic blood vessel endoprosthesis]. *Vestn Khir Im I I Grek.* 1986;137(11):123-5.
46. Lilja F, Mani K, Wanhainen A. Editor's Choice - Trend-break in Abdominal Aortic Aneurysm Repair With Decreasing Surgical Workload. *Eur J Vasc Endovasc Surg.* 2017;53(6):811-9.
47. Najibi S, Terramani TT, Weiss VJ, Mac Donald MJ, Lin PH, Redd DC, et al. Endoluminal versus open treatment of descending thoracic aortic aneurysms. *J Vasc Surg.* 2002;36(4):732-7.
48. Charlton-Ouw KM, Ikeno Y, Bokamper M, Zakhary E, Smeds MR. Aortic endograft sizing and endoleak, reintervention, and mortality following endovascular aneurysm repair. *J Vasc Surg.* 2021;74(5):1519-26.e2.
49. Cao P, Verzini F, Zannetti S, De Rango P, Parlani G, Lupattelli L, Maselli A. Device migration after endoluminal abdominal aortic aneurysm repair: analysis of 113 cases with a minimum follow-up period of 2 years. *J Vasc Surg.* 2002;35(2):229-35.
50. Mohan IV, Laheij RJ, Harris PL. Risk factors for endoleak and the evidence for stent-graft oversizing in patients undergoing endovascular aneurysm repair. *Eur J Vasc Endovasc Surg.* 2001;21(4):344-9.
51. Ishimaru S. [Endovascular stent-graft repair for thoracic aortic aneurysm]. *Kyobu Geka.* 2006;59(8 Suppl):666-73.
52. Ishimaru S. Endografting of the aortic arch. *J Endovasc Ther.* 2004;11 Suppl 2:ii62-71.
53. Csobay-Novák C, Entz L, Banga P, Pólos M, Szabolcs Z, Csikós G, et al. [Fenestrated endovascular repair of a thoracoabdominal aortic aneurysm in chronic dissection]. *Orv Hetil.* 2021;162(31):1260-4.
54. Entz L, Nemes B, Szeberin Z, Szabó GV, Sótónyi P, Banga P, et al. [Fenestrated stent-graft implantation

in Hungary]. *Magy Seb.* 2015;68(3):88-93.

55. Greenberg RK, Haulon S, O'Neill S, Lyden S, Ouriel K. Primary endovascular repair of juxtarenal aneurysms with fenestrated endovascular grafting. *Eur J Vasc Endovasc Surg.* 2004;27(5):484-91.

56. Parodi J, Berguer R, Carrascosa P, Khanafer K, Capunay C, Wizauer E. Sources of error in the measurement of aortic diameter in computed tomography scans. *J Vasc Surg.* 2014;59(1):74-9.

57. Csobay-Novák C, Fontanini DM, Szilágyi B, Szeberin Z, Kolossváry M, Maurovich-Horvat P, et al. Thoracic Aortic Strain is Irrelevant Regarding Endograft Sizing in Most Young Patients. *Ann Vasc Surg.* 2017;38:227-32.

58. Csobay-Novák C, Fontanini DM, Szilágyi BR, Szeberin Z, Szilveszter BA, Maurovich-Horvat P, et al. Thoracic aortic strain can affect endograft sizing in young patients. *J Vasc Surg.* 2015;62(6):1479-84.

59. Jordan WD, Jr., de Vries JP, Ouriel K, Mehta M, Varnagy D, Moore WM, Jr., et al. Midterm outcome of EndoAnchors for the prevention of endoleak and stent-graft migration in patients with challenging proximal aortic neck anatomy. *J Endovasc Ther.* 2015;22(2):163-70.

60. Jordan WD, Jr., Mehta M, Varnagy D, Moore WM, Jr., Arko FR, Joye J, et al. Results of the ANCHOR prospective, multicenter registry of EndoAnchors for type Ia endoleaks and endograft migration in patients with challenging anatomy. *J Vasc Surg.* 2014;60(4):885-92.e2.

61. Hidi L, Pál D, Boros AM, Kováts T, Menyhei G, Szeberin Z. [Analysis of data from the National Vascular Registry on infrarenal aortic aneurysms (2010–2019)]. *Orv Hetil.* 2021;162(31):1233-43.

62. Tolenaar JL, Jonker FH, Moll FL, van Herwaarden J, Morasch MD, Makaroun MS, Trimarchi S. Influence of oversizing on outcome in thoracic endovascular aortic repair. *J Endovasc Ther.* 2013;20(6):738-45.

63. Morgan-Hughes GJ, Owens PE, Marshall AJ, Roobottom CA. Thoracic aorta at multi-detector row CT: motion artifact with various reconstruction windows. *Radiology*. 2003;228(2):583-8.
64. Maurel B, Mastracci TM, Spear R, Hertault A, Azzaoui R, Sobocinski J, Haulon S. Branched and fenestrated options to treat aortic arch aneurysms. *J Cardiovasc Surg (Torino)*. 2016;57(5):686-97.
65. Tsilimparis N, Debus ES, von Kodolitsch Y, Wipper S, Rohlfes F, Detter C, et al. Branched versus fenestrated endografts for endovascular repair of aortic arch lesions. *J Vasc Surg*. 2016;64(3):592-9.
66. Hongku K, Dias NV, Sonesson B, Resch TA. Total aortic endovascular repair. *J Cardiovasc Surg (Torino)*. 2016;57(6):784-805.
67. Inoue K, Hosokawa H, Iwase T, Sato M, Yoshida Y, Ueno K, et al. Aortic arch reconstruction by transluminally placed endovascular branched stent graft. *Circulation*. 1999;100(19 Suppl):Ii316-21.
68. Yu J, Liu S, Huang J, Wang W. Current Theories and Clinical Trial Evidence for Limiting Human Abdominal Aortic Aneurysm Growth. *Curr Drug Targets*. 2018;19(11):1302-8.
69. Raffort J, Adam C, Carrier M, Ballaith A, Coscas R, Jean-Baptiste E, et al. Artificial intelligence in abdominal aortic aneurysm. *J Vasc Surg*. 2020;72(1):321-33.e1.
70. Nana P, Dakis K, Brodis A, Spanos K, Kouvelos G. Circulating Biomarkers for the Prediction of Abdominal Aortic Aneurysm Growth. *J Clin Med*. 2021;10(8).
71. Lorenzen US, Eiberg JP, Hultgren R, Wanhainen A, Langenskiöld M, Sillesen HH, Bredahl KK. The Short-term Predictive Value of Vessel Wall Stiffness on Abdominal Aortic Aneurysm Growth. *Ann Vasc Surg*. 2021;77:187-94.
72. Moll FL, Powell JT, Fraedrich G, Verzini F, Haulon S, Waltham M, et al. Management of abdominal aortic aneurysms clinical practice guidelines of the European society for vascular surgery. *Eur J Vasc Endovasc Surg*. 2011;41 Suppl 1:S1-s58.

73. Chaikof EL, Brewster DC, Dalman RL, Makaroun MS, Illig KA, Sicard GA, et al. SVS practice guidelines for the care of patients with an abdominal aortic aneurysm: executive summary. *J Vasc Surg.* 2009;50(4):880-96.
74. Borzsák S, Péter C, Suhai F, Szeberin Z, Csobay-Novák C. [Initial experiences with physician-modified endo grafts]. *Orv Hetil.* 2022;163(3):109-15.
75. Ohrlander T, Sonesson B, Ivancev K, Resch T, Dias N, Malina M. The chimney graft: a technique for preserving or rescuing aortic branch vessels in stent-graft sealing zones. *J Endovasc Ther.* 2008;15(4):427-32.
76. Avci M, Vos JA, Kolvenbach RR, Verhoeven EL, Perdikides T, Resch TA, et al. The use of endoanchors in repair EVAR cases to improve proximal endograft fixation. *J Cardiovasc Surg (Torino).* 2012;53(4):419-26.
77. Tassiopoulos AK, Monastiriotis S, Jordan WD, Muhs BE, Ouriel K, De Vries JP. Predictors of early aortic neck dilatation after endovascular aneurysm repair with EndoAnchors. *J Vasc Surg.* 2017;66(1):45-52.
78. Muhs BE, Jordan W, Ouriel K, Rajaei S, de Vries JP. Matched cohort comparison of endovascular abdominal aortic aneurysm repair with and without EndoAnchors. *J Vasc Surg.* 2018;67(6):1699-707.
79. Qamhawi Z, Barge TF, Makris GC, Patel R, Wigham A, Anthony S, Uberoi R. Editor's Choice - Systematic Review of the Use of Endoanchors in Endovascular Aortic Aneurysm Repair. *Eur J Vasc Endovasc Surg.* 2020;59(5):748-56.
80. Reyes Valdivia A, Chaudhuri A, Milner R, Pratesi G, Reijnen MM, Tinelli G, et al. Endovascular aortic repair with EndoAnchors demonstrate good mid-term outcomes in physician-initiated multicenter analysis-The PERU registry. *Vascular.* 2022;30(1):27-37.
81. Olsson C, Thelin S, Ståhle E, Ekbom A, Granath F. Thoracic aortic aneurysm and dissection: increasing prevalence and improved outcomes reported in a nationwide population-based study of more than 14,000 cases from 1987 to 2002. *Circulation.* 2006;114(24):2611-8.

82. Szeberin Z, Hidi L, Kováts T, Menyhei G. [Report of the 2013 data of the Hungarian Vascular Registry]. *Magy Seb.* 2014;67(6):362-71.
83. Pafili K, Gouni-Berthold I, Papanas N, Mikhailidis DP. Abdominal aortic aneurysms and diabetes mellitus. *J Diabetes Complications.* 2015;29(8):1330-6.
84. Stavropoulos SW, Carpenter JP. Postoperative imaging surveillance and endoleak management after endovascular repair of thoracic aortic aneurysms. *J Vasc Surg.* 2006;43 Suppl A:89a-93a.
85. Csobay-Novák C, Pataki Á, Fontanini DM, Borzsák S, Banga P, Sótónyi P. [Branched endovascular aortic repair of a contained rupture in chronic aortic dissection]. *Orv Hetil.* 2022;163(22):886-90.
86. Szeberin Z, Nemes B, Csobay-Novák C, Mihály Z, Entz L. Proximal scalloped custom-made Relay® stent graft in chronic type B dissection: endovascular repair in a drug abuser patient. *Interv Med Appl Sci.* 2016;8(1):37-40.
87. Cooper DG, Walsh SR, Sadat U, Noorani A, Hayes PD, Boyle JR. Neurological complications after left subclavian artery coverage during thoracic endovascular aortic repair: a systematic review and meta-analysis. *J Vasc Surg.* 2009;49(6):1594-601.
88. Criado FJ, McKendrick C, Criado FR. Technical solutions for common problems in TEVAR: managing access and aortic branches. *J Endovasc Ther.* 2009;16 Suppl 1:163-79.

## 9. Bibliography of the candidate's publications

### 9.1. Publications related to the present thesis

1. Fontanini DM, Huber M, Vecsey-Nagy M, Borzsák S, Csőre J, Sótónyi P, et al. Pulsatile Changes of the Aortic Diameter May Be Irrelevant Regarding Endograft Sizing in Patients With Aortic Disease. *J Endovasc Ther.* 2023;15266028231172368. **IF: 2.6**
2. Fontanini DM, Borzsák S, Vecsey-Nagy M, Jokkel Z, Szeberin Z, Szentiványi A, et al. [Endoanchoring may be effective in the endovascular aortic repair of juxtarenal aneurysms]. *Orv Hetil.* 2022;163(16):631-6. **IF: 0.6**
3. Fontanini DM, Fazekas G, Vallus G, Juhász G, Váradi R, Kövesi Z, et al. [Thoracic aortic stentgraft implantations in Hungary from 2012 to 2016]. *Orv Hetil.* 2018;159(2):53-7. **IF: 0.564**

### 9.2. Publications not related to the present thesis

1. Borbély K, Balogh H, Kardos IB, Fontanini DM, Oláh L, Berényi E, et al. Cadasil syndrome: Long-term follow-up on MRI. *Imaging.* 2022;14(2):109–12. doi:10.1556/1647.2022.00059
2. Juhász G, Csőre J, Suhai FI, Gyánó M, Pataki Á, Vecsey-Nagy M, et al. [Diagnostic performance of non-contrast magnetic resonance angiography in patients with lower extremity arterial disease]. *Orv Hetil.* 2022;163(45):1782-8.
3. Borzsák S, Süvegh A, Szentiványi A, Fontanini DM, Vecsey-Nagy M, Banga P, et al. Midterm Results of Iliac Branch Devices in a Newly Established Aortic Center. *Life (Basel).* 2022;12(8).
4. Csőre J, Suhai FI, Gyánó M, Pataki Á A, Juhász G, Vecsey-Nagy M, et al. Quiescent-Interval Single-Shot Magnetic Resonance Angiography May Outperform Carbon-Dioxide Digital Subtraction Angiography in Chronic Lower Extremity Peripheral Arterial Disease. *J Clin Med.* 2022;11(15).

5. Vecsey-Nagy M, Jermendy Á L, Kolossváry M, Vattay B, Boussoussou M, Suhai FI, et al. Heart Rate-Dependent Degree of Motion Artifacts in Coronary CT Angiography Acquired by a Novel Purpose-Built Cardiac CT Scanner. *J Clin Med.* 2022;11(15).
6. Csobay-Novák C, Pataki Á, Fontanini DM, Borzsák S, Banga P, Sótonyi P. [Branched endovascular aortic repair of a contained rupture in chronic aortic dissection]. *Orv Hetil.* 2022;163(22):886-90.
7. Borzsák S, Szentiványi A, Süvegh A, Fontanini DM, Vecsey-Nagy M, Banga P, et al. Complex Aortic Interventions Can Be Safely Introduced to the Clinical Practice by Physicians Skilled in Basic Endovascular Techniques. *Life (Basel).* 2022;12(6).
8. Csobay-Novák C, Fontanini DM. Angiológia a háziorvosi gyakorlatban: Műszeres vizsgálatok: CT- és MR-diagnosztika az angiológiában. Farkas K, Kolossváry E. SpringMed, Budapest, Hungary, 2021. 57-67 p.
9. Vecsey-Nagy M, Jermendy ÁL, Suhai FI, Panajotu A, Csöre J, Borzsák S, et al. Model-based adaptive filter for a dedicated cardiovascular CT scanner: Assessment of image noise, sharpness and quality. *Eur J Radiol.* 2021;145:110032.
10. Csobay-Novák C, Entz L, Banga P, Pólos M, Szabolcs Z, Csikós G, et al. [Fenestrated endovascular repair of a thoracoabdominal aortic aneurysm in chronic dissection]. *Orv Hetil.* 2021;162(31):1260-4.
11. Mihály Z, Fontanini DM, Sándor Á D, Dósa E, Lovas G, Kolossváry E, et al. [Differences in guidelines for patients with carotid artery stenosis in some European countries]. *Orv Hetil.* 2020;161(51):2139-45.
12. Ferencz AB Bárczi G, Heltai K, Zima E, Kovács A, Molnár L, Fontanini DM, Szűcs A, Kiss AR, Gyánó M, Benke K, Németh E, Fazekas L, Szigyártó I, Becker D, Merkely B. An exceptional case of myocarditis: from non-specific symptoms to the ECMO. *Cardiologia Hungarica.* 2019;49: Suppl. B pp. B68-B68.
13. Csobay-Novák C, Fontanini DM. Vaszkuláris Medicína: Vaszkuláris CT és MR diagnosztika. Sótonyi P, Szeberin Z. Semmelweis; Budapest, Hungary, 2018. 25-8 p.
14. Mihály Z, Banga P, Szatai L, Simonffy Á, Fontanini DM, Béltéki J, et al. [Endovascular treatment of blunt thoracic aortic injuries]. *Magy Seb.* 2017;70(1):13-7.



15. Csobay-Novák C, Fontanini DM, Szilágyi B, Szeberin Z, Kolossváry M, Maurovich-Horvat P, et al. Thoracic Aortic Strain is Irrelevant Regarding Endograft Sizing in Most Young Patients. *Ann Vasc Surg.* 2017;38:227-32.
16. Csobay-Novák C, Fontanini DM, Szilágyi BR, Szeberin Z, Szilveszter BA, Maurovich-Horvat P, et al. Thoracic aortic strain can affect endograft sizing in young patients. *J Vasc Surg.* 2015;62(6):1479-84.

## 10. Acknowledgements

I would like to express my deepest gratitude for the invaluable contributions and support of numerous people who helped to make this thesis possible.

First and foremost, I would like to express my heartfelt admiration to my mentor **Csaba Csobay-Novák**, whose exceptional guidance and supervision have been instrumental throughout my clinical and academic journey. His unwavering support and expertise have profoundly shaped my work.



I am also indebted to **Professor Péter Sótonyi** and the late **Professor Kálmán Hüttl** for their early mentorship, which laid the foundation for my career development. Without their inspiration and encouragement, I would not have reached this point. I wish to express my sincere gratitude to **Professor Zoltán Szeberin** for mentoring me and supporting my research.

As both Rector of the Semmelweis University and the Chairman of the Heart and Vascular Centre, I am immensely grateful to **Professor Béla Merkely**. His visionary leadership and belief in my potential have been instrumental in making my studies and research possible.

I express my gratitude to **Anna Kelemenné Polgár** and **Zsófia Jokkel** for their exceptional illustrations. I extend my appreciation to **Máté Huber** and all my colleagues for their continuous support, collaboration, and valuable insights that have enriched my academic and professional growth.

My deepest appreciation goes to my family for their untiring support, understanding and patience. Their love, encouragement and sacrifices have been a constant source of motivation and inspiration.

# Pulsatile Changes of the Aortic Diameter May Be Irrelevant Regarding Endograft Sizing in Patients With Aortic Disease

Daniele Mariastefano Fontanini, MD<sup>1,2</sup> , Máté Huber, MD<sup>1</sup>,  
 Milán Vecsey-Nagy, MD<sup>2</sup>, Sarolta Borzsák, MD<sup>1,2</sup>, Judit Csöre, MD<sup>1</sup>,  
 Péter Sótónyi, MD, PhD<sup>2,3</sup>, and Csaba Csobay-Novák, MD, PhD<sup>1,2</sup> 

## Abstract

**Purpose:** Endovascular aortic repair has become the preferred elective treatment of infrarenal aortic aneurysms. Aortic pulsatility may pose problems regarding endograft sizing. The aims of this study are to determine the aortic pulsatility in patients with aortic disease and to evaluate the effect of pulsatility on the growth of aneurysms. **Materials and Methods:** In this retrospective study, analyses of computed tomography angiography (CTA) images of 31 patients under conservative treatment for small abdominal aortic aneurysms were performed. Reconstructions of the raw electrocardiography (ECG) gated dataset at 30% and 90% of the R-R cycle were used. After lumen segmentation, total aortic cross-sectional area was measured in diastole and systole in the following zones: Z0, Z3, Z5, Z6, Z8, and Z9. Effective diameters (EDs) were calculated from the systolic ( $ED_{sys}$ ) and diastolic ( $ED_{dia}$ ) cross-sectional areas to determine absolute ( $ED_{sys} - ED_{dia}$ , mm) and relative pulsatility [ $(ED_{sys} - ED_{dia}) / ED_{dia}$ , %]. Diameter of the aneurysms was measured on baseline images and the last preoperative follow-up study of each patient. **Results:** A total of 806 measurements were completed, 24 pulsatility and 2 growth measurements per patient. The mean pulsatility values at each point were as follows: Z0:  $0.7 \pm 0.8$  mm, Z3:  $1.0 \pm 0.6$  mm, Z5:  $1.0 \pm 0.6$  mm, Z6:  $0.8 \pm 0.7$  mm, Z8:  $0.7 \pm 1.0$  mm, Z9:  $0.9 \pm 0.9$  mm. Follow-up time was  $5.5 \pm 2.2$  years during which a growth of  $13.42 \pm 9.09$  mm ( $2.54 \pm 1.55$  mm yearly) was observed. No correlation was found between pulsatility values and growth rate of the aneurysms. **Conclusion:** The pulsatility of the aorta is in a submillimetric range for the vast majority of patients with aortic disease, thus probably not relevant regarding endograft sizing. Pulsatility of the ascending aorta is smaller than that of the descending segment, making an additional oversize of a Z0 implantation questionable.

## Clinical Impact

Endovascular aortic repair requires precise preoperative planning. Pulsatile changes of the aortic diameter may pose issues regarding endograft sizing. In our retrospective single-centre study, aortic pulsatility of patients with AAA was measured on ECG gated CTA images. Pulsatility values reached a maximum at the descending aorta, however absolute pulsatility values did not exceed 1 mm at any point along the aorta. Therefore, significance of aortic pulsatility regarding the sizing of EVAR prostheses is questionable. Correlation between pulsatility and AAA growth was not found.

## Keywords

aorta, aneurysm, abdominal aneurysm, computed tomography angiography, endovascular aneurysm repair, stent graft

## Introduction

In the past 2 decades, endovascular aneurysm repair (EVAR) has grown from a promising alternative to open surgical repair (OSR) to the preferred elective treatment modality in most patients with infrarenal aortic aneurysm. Due to its considerably lower 30-day mortality than in cases treated with OSR, EVAR is always considered in patients with suitable aortic and side branch anatomy and adequate

<sup>1</sup>Department of Interventional Radiology, Semmelweis University, Budapest, Hungary

<sup>2</sup>Semmelweis Aortic Center, Heart and Vascular Center, Semmelweis University, Budapest, Hungary

<sup>3</sup>Department of Vascular and Endovascular Surgery, Semmelweis University, Budapest, Hungary

### Corresponding Author:

Csaba Csobay-Novák, Department of Interventional Radiology, Semmelweis University, Határőr út 18, Budapest 1122, Hungary.  
 Email: csobay.csaba@semmelweis.hu

postoperative life expectancy.<sup>1-6</sup> Computed tomography angiography (CTA) imaging plays a crucial role in the diagnosis, preoperative assessment, and postoperative follow-up of patients with abdominal aortic aneurysm (AAA).<sup>7-10</sup>

Electrocardiography (ECG) gating is a widely used technique to minimize motion artifacts on CTA images caused by pulsation.<sup>11</sup> Moreover, retrospective ECG-gating also permits the comparison between systolic and diastolic images of the aorta. Several studies including our previous research reported considerable data about pulsatile changes of the non-aneurysmatic aorta.<sup>12-14</sup> However, aortic pulsatility in patients with aneurysms has not been assessed yet. Pulsatility of aortic segments commonly used as EVAR landing zones may be a concern for complications such as endograft migration or endoleaks. Furthermore, as thoracic endovascular aortic repair (TEVAR) tends to increasingly involve the ascending aorta as landing zone, the change of diameter in this segment might also be noteworthy.

In this study, our primary objective was to measure aortic pulsatility in a cohort of patients with aortic disease using retrospective ECG synchronized CTA images. Our secondary goal was to determine whether aortic pulsatility has any effect on the growth rates of AAAs.

## Materials and Methods

This is a single-center, investigator-driven retrospective study approved by the Semmelweis University Regional and Institutional Committee of Science and Research Ethics (95/2021). All procedures were carried out in accordance with the Declaration of Helsinki.

### Computed Tomography Imaging and Image Analysis

Readily available images were analyzed of consecutive patients who underwent systolic and diastolic phase CTA as part of routine AAA surveillance. The cohort selected for our study consisted of patients who underwent at least 2 aortic CTA examinations at least 4 years apart. The computed tomography (CT) scans used for the study were conducted in the time period between November 24, 2005, and June 12, 2020.

CTA examinations used for pulsatility measurements were performed with a 256 slice multidetector scanner (Philips Brilliance iCT; Koninklijke Philips N.V., Best, The Netherlands). Acquisitions of the whole aorta and ilio-femoral arteries were taken from the level of the thoracic inlet to the level of the symphysis (tube voltage 100 kV). Intravenous nonionic iodinated contrast agent (Iomeron 400, Bracco Ltd, Milan, Italy) was administered into an antecubital vein through a 18 g cannula using a dual-syringe power injector at a 4 to 5 mL/s flow rate. A retrospective ECG gated helical protocol was used for the scans, optimized for

multi-phase imaging of the aorta with the minimalization of motion artifacts due to the pulsatile movement of the aorta. This method allowed us to acquire a relatively motion-free image of the aorta in both systolic and diastolic phases. Iterative reconstructions (iDose, Koninklijke Philips N.V., Best, The Netherlands) were performed with a 1 mm slice thickness and 1 mm increments for every 10% of the cardiac cycle, providing us with 10 series of images per patient. The acquired image data were then transferred to a dedicated workstation for further analysis.

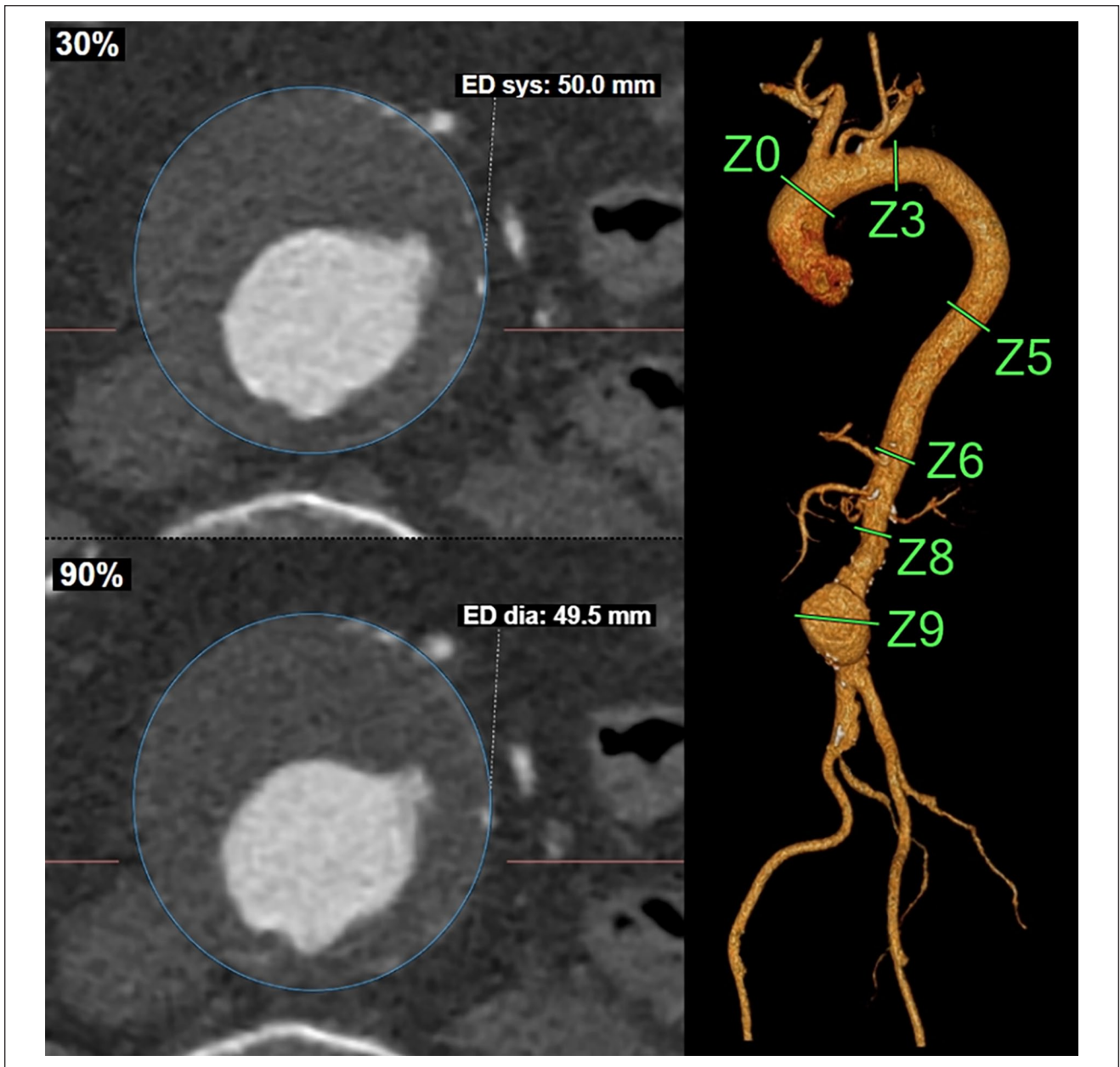
Vessel segmentation and cross-sectional area measurements were performed by a board-certified radiologist experienced in cardiovascular imaging (D.M.F.). 3mensio Vascular (Pie Medical Imaging BV, Maastricht, The Netherlands) software was used for the evaluation of the CTA series. Automatic lumen segmentation was conducted by placing markers into the aortic root, aortic bifurcation, and common femoral arteries. In the cross-sectional plane, an ellipsoid contour was drawn manually along the outer wall of the aorta. Effective aortic diameter was derived. Two measurements with a 1 cm distance from each other were accomplished in the following positions: Z0 (distal end of the ascending aorta 1 cm proximal to the brachiocephalic trunk orifice), Z3 (distal to the left subclavian artery origin), Z5 (10 cm proximally to celiac trunk orifice), Z6 (at the celiac trunk orifice), Z8 (distal to the renal orifices), and Z9 (the largest diameter of the infrarenal aneurysm). Every measurement was performed on a systolic series at 30% of the cardiac cycle and on a diastolic phase at 90% (Csobay-Novák, Fontanini and Szilágyi). Positions along the centerline were identical in both phases. Twenty-four measurements were accomplished on each patient resulting in a total of 744 regarding pulsatility (Figure 1).

Absolute pulsatility is defined as the difference between systolic and diastolic effective diameters (EDs) of the vessel (mm;  $ED_{sys} - ED_{dia}$ ). Relative pulsatility (%) is defined as the ratio of absolute pulsatility and diastolic ED [ $(ED_{sys} - ED_{dia}) / ED_{dia}$ ].

Expansion rate assessment of the AAAs was conducted on the patients' CTA studies performed independently from our research, including primary diagnostic and follow-up studies for AAA surveillance. Aneurysm diameter measurements were performed by a board-certified radiologist experienced in cardiovascular imaging (D.M.F.).

### Statistical Analysis

Continuous variables are expressed as mean  $\pm$  SD or median with interquartile ranges, and categorical variables are expressed as numbers and percentages. Normality of continuous parameters was tested with Kolmogorov-Smirnov test. Paired *t*-test was performed to compare systolic and diastolic measurements. Absolute and relative pulsatility values along the aorta were compared using 1-way,



**Figure 1.** Systolic (30%) and diastolic (90%) effective diameters (EDs) calculated from an ellipsoid placed onto the aortic contour. The image shows position Z9 at the widest point of the abdominal aortic aneurysm.

repeated-measure analysis of variances (ANOVA). Pearson correlation was performed to assess correlation between different continuous variables. A 2-sided  $p < 0.05$  was considered to be significant in all analyses. SPSS (IBM, Armonk, NY, USA version 27.0) was used for all calculations.

## Results

A total of 806 measurements on 31 patients (25 men, median age 73 years) were performed for pulsatility evaluation and

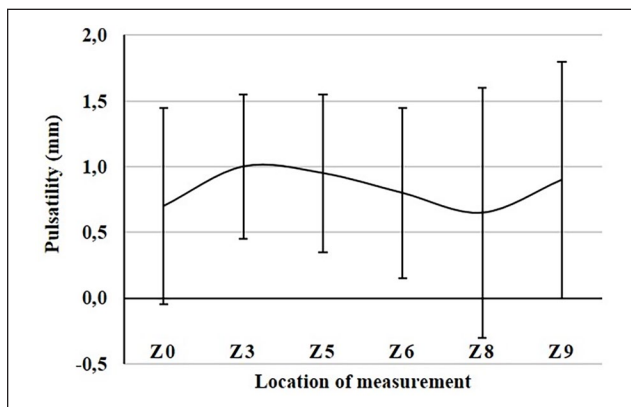
growth rate assessment. Patient demographics are displayed in Table 1.

Maximal systolic diameters proved to be significantly higher than diastolic measurements in all positions: Z0:  $34.82 \pm 2.96$  mm versus  $34.62 \pm 2.78$  mm, Z3:  $30.73 \pm 4.40$  mm versus  $30.31 \pm 3.27$  mm, Z5:  $28.53 \pm 2.97$  mm versus  $28.31 \pm 4.07$  mm, Z6:  $27.02 \pm 3.76$  mm versus  $27.00 \pm 3.22$  mm, Z8:  $23.97 \pm 4.61$  mm versus  $23.43 \pm 4.47$  mm, Z9:  $40.55 \pm 7.33$  mm versus  $39.90 \pm 7.33$  mm, respectively, all  $p < 0.001$ .

**Table 1.** Demographic Data.

Patient characteristics	N=31
Age, years	73 (70–77)
Male sex	25 (80.6)
Body mass index (kg/m <sup>2</sup> )	26.9 (24.7–29.8)
Actively smoking	9 (29.0)
Any smoking history	27 (87.1)
Hypertension	28 (90.3)
Hypercholesterolemia	24 (77.4)
Diabetes mellitus	8 (25.8)
Chronic obstructive pulmonary disease (COPD)	17 (54.8)
Coronary artery disease	22 (30.1)
Peripheral artery disease	8 (25.8)
Chronic kidney disease	13 (41.9)
History of malignancy	5 (16.1)

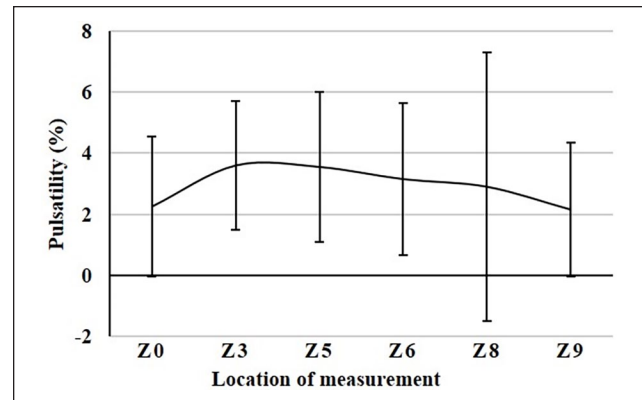
Continuous data are presented as median (interquartile range); categorical data are number (%).

**Figure 2.** Absolute pulsatility of the aorta in each measuring position.

Average absolute and relative pulsatility values were calculated from the dual measurements. Absolute pulsatility values did not differ significantly between the measured positions; their mean values were as follows: Z0:  $0.7 \pm 0.8$  mm, Z3:  $1.0 \pm 0.6$  mm, Z5:  $1.0 \pm 0.6$  mm, Z6:  $0.8 \pm 0.7$  mm, Z8:  $0.7 \pm 1.0$  mm, Z9:  $0.9 \pm 0.9$  mm,  $p=0.62$  (Figure 2).

Although relative pulsatility values displayed a tendency of decreasing along the descending and abdominal aorta, their difference along the aorta was not significant. The calculated values were Z0:  $2.3\% \pm 2.3\%$ , Z3:  $3.6\% \pm 2.1\%$ , Z5:  $3.6\% \pm 2.5\%$ , Z6:  $3.2\% \pm 2.5\%$ , Z8:  $2.9\% \pm 4.4\%$ , Z9:  $2.2\% \pm 2.2\%$ ,  $p=0.18$  (Figure 3). Both absolute and relative pulsatility of the aorta reached its maximum at Z3 (1.0 mm, 3.6%).

In the process of aneurysm growth rate evaluation, maximum diameters of the AAA were registered on the baseline

**Figure 3.** Relative pulsatility in each measuring position.

and latest preoperative follow-up images. The mean time elapsed between the 2 examinations was  $5.5 \pm 2.2$  years. During the time of follow-up, the maximum diameter of the aneurysm showed growth in every patient. The mean absolute diameter of the aneurysms has changed from  $41.6 \pm 7.3$  mm to  $52.8 \pm 11.3$  mm during the examined time interval. The mean extent of aneurysm growth was  $13.4 \pm 9.1$  mm amid the observed period, equivalent to a mean yearly growth rate of  $2.5 \pm 1.6$  mm, assuming a constant growth rate. When assessing the correlation of absolute aortic pulsatility values in each position and the growth rate of the aneurysms, no significant associations were found: Z0:  $r=-0.30$ ,  $p=0.90$ ; Z3:  $r=0.15$ ,  $p=0.50$ ; Z5:  $r=0.19$ ,  $p=0.39$ ; Z6:  $r=0.06$ ,  $p=0.81$ ; Z8:  $r=0.09$ ,  $p=0.69$ ; Z9:  $r=0.14$ ,  $p=0.54$ . Similar tendencies could be documented for relative pulsatility values: Z0:  $r=-0.02$ ,  $p=0.90$ ; Z3:  $r=0.18$ ,  $p=0.42$ ; Z5:  $r=0.20$ ,  $p=0.38$ ; Z6:  $r=0.05$ ,  $p=0.81$ ; Z8:  $r=0.08$ ,  $p=0.72$ ; Z9:  $r=0.17$ ,  $p=0.46$ .

## Discussion

In this study, systolic-diastolic differences of the aortic diameter were measured along the course of the vessel. Our results show that absolute aortic pulsatility is in a submillimetric range in most measuring points, thus relative pulsatility does not exceed 5% at any of the examined locations. The maximal extent of aortic pulsatility was detected at position Z3 on the proximal third of descending aorta. Furthermore, the study's results did not show correlation between pulsatile changes of the aortic diameter and the growth rate of the observed aneurysms.

Parodi et al<sup>14</sup> found that there was a significant difference between systolic and diastolic diameters on multiple points of the descending aorta, thus suggesting the use of systolic CTA images for stent graft sizing. Theoretically, planning based on diastolic images of the aorta could lead to undersizing of the stent grafts, which may pose the risk of

complications such as type Ia endoleaks or distal migration.<sup>15</sup> This is particularly important as diastolic phase images are routinely used for preoperative EVAR and TEVAR planning, being less compromised by motion artifacts.<sup>16</sup>

Our previous studies showed that pulsatility is significant neither in an elderly patient cohort with no relevant aortic disease nor in the thoracic aortic segment of younger patients.<sup>12,13</sup> The analyzed elderly cohort did not suffer from AAA; however, with a median age of 74 years, it was heavily affected with aortic wall atherosclerosis. Aortic pulsatility was not clinically considerable in this population, with the highest value in Z3.<sup>12</sup>

As our previous study suggested that younger individuals might have a higher risk of a potential undersize, our following research targeted a younger population. This study resulted in elevated aortic strain compared with the elderly atherosclerotic population; however, the extent of pulsatility on the descending aorta was also not relevant regarding TEVAR sizing.

Comparing our current results with our previously reported findings, patients treated with AAA show similarly low aortic pulsatility to the non-aneurysmatic population, rarely exceeding 1 mm. It is important to note that the highest absolute and relative pulsatility was measured in Z3 in both aneurysmatic and non-aneurysmatic patients.<sup>12,13</sup> This implies that pulsatile changes of the ascending aorta are lower than the values registered on the proximal descending aorta; thus, the regular endograft oversizing should not be further increased with a Z0 proximal fixation zone.<sup>15,17</sup> This is becoming increasingly important as the endovascular repair of the aortic arch is getting widely accepted and available. There is a slight difference between the approach of the 2 major manufacturers of such branched devices regarding the sizing for the proximal landing zone, with Terumo Aortic recommending a somewhat heavier oversize (15%–20%) in Z0 compared with other aortic segments, while Cook Medical generally recommends the same degree of oversize (15%–20%) throughout the aorta (Niewijk E., Trompler J., written personal communication, 6.12.2021). It is also worth mentioning that the dilated portion of the aorta did not show any relevant changes compared with other segments.

Prediction of AAA growth is a profoundly researched subject, mostly due to the well-established connection between the maximum aneurysm diameter and the odds ratio for rupture, which is a life-threatening complication of AAAs.<sup>3,6,18–21</sup> Knowing the significance of this matter, we attempted to reveal correspondence between aortic pulsatility measurable on consequent follow-up CTA studies and the expansion rate of the aneurysms. Although every patient's AAA showed growth during the examined follow-up period, no statistically significant association was found between aortic pulsatility values and the growth rate of an aneurysm.

## Study Limitations

Although CTA is the preferred imaging modality for preoperative assessment of the aorta in patients treated for AAA, direct visualization of the vessel wall itself can be oftentimes limited on CT images. Hence, in the absence of landmarks such as atherosclerotic or thrombotic changes, the contour of the contrast agent-filled lumen is the only measurable boundary between the aorta and adjacent tissues, therefore identification of the exact location along the aorta to measure the diameter in the same position in 2 phases within an R-R' cycle can be challenging. However, the spatial (0.625 mm) and temporal (0.270 seconds) resolution of the used CT equipment ensures that 2 images in identical table positions in different phases are more than likely to represent the same spot along the centerline. Moreover, the aforementioned Lin analysis of interobserver and intraobserver variabilities has proven the reliability of the method adopted for image evaluation.

It is also worth mentioning that the relatively small cohort on which this retrospective study was conducted gives room for further investigations on the subject involving a larger number of patients.

## Conclusion

This study demonstrates that aortic pulsatility in patients with aortic disease usually does not exceed 1 mm, with a resulting relative pulsatility value below 5%. This implies that the regularly used 10%–20% oversizing in EVAR planning may be sufficient and a possible application of systolic instead of diastolic phase images for stent graft sizing is most likely unnecessary. As pulsatility is the highest on the descending aorta, further increase in oversize for a Z0 landing zone may be questionable.

Aortic pulsatility does not appear to correlate with long-term growth rate of aneurysms; consequently, this parameter is not likely to become a predictor of AAA expansion.

## Acknowledgments

The author would like to thank Eric Niewijk from Terumo Aortic and Jürgen Trompler from Cook Medical for their help regarding this manuscript.

## Declaration of Conflicting Interests

The author(s) declared the following potential conflicts of interest with respect to the research, authorship, and/or publication of this article: Csaba Csobay-Novák—training, consultation, and proctoring for W. L. Gore & Associates, Cook Medical, Terumo Aortic, and Medtronic. Other authors have no competing interests.

## Funding

The author(s) disclosed receipt of the following financial support for the research, authorship, and/or publication of this article: Project no. NVKP\_16-1–2016-0017 (“National Heart Program”)

has been implemented with the support provided from the National Research, Development and Innovation Fund of Hungary, financed under the NVKP\_16 funding scheme. The research was financed by the Thematic Excellence Programme (2020-4.1.1.-TKP2020) of the Ministry for Innovation and Technology in Hungary, within the framework of the Therapeutic Development and Bioimaging thematic programmes of the Semmelweis University.

### ORCID iDs

Daniele Mariastefano Fontanini  <https://orcid.org/0000-0002-6364-4204>

Csaba Csobay-Novák  <https://orcid.org/0000-0003-0826-7888>

### References

- Budtz-Lilly J, Venermo M, Debus S, et al. Editor's choice—assessment of international outcomes of intact abdominal aortic aneurysm repair over 9 years. *Eur J Vasc Endovasc Surg.* 2017;54(1):13–20. doi:10.1016/j.ejvs.2017.03.003.
- Chaikof EL, Brewster DC, Dalman RL, et al. SVS practice guidelines for the care of patients with an abdominal aortic aneurysm: executive summary. *J Vasc Surg.* 2009;50(4):880–896. doi:10.1016/j.jvs.2009.07.001.
- Erbel R, Aboyans V, Boileau C, et al. 2014 ESC guidelines on the diagnosis and treatment of aortic diseases: document covering acute and chronic aortic diseases of the thoracic and abdominal aorta of the adult. The task force for the diagnosis and treatment of aortic diseases of the European Society of Cardiology (ESC). *Eur Heart J.* 2014;35(41):2873–2926. doi:10.1093/eurheartj/ehu281.
- Lilja F, Mani K, Wanhainen A. Editor's choice—trend-break in abdominal aortic aneurysm repair with decreasing surgical workload. *Eur J Vasc Endovasc Surg.* 2017;53(6):811–819. doi:10.1016/j.ejvs.2017.02.031.
- Najibi S, Terramani TT, Weiss VJ, et al. Endoluminal versus open treatment of descending thoracic aortic aneurysms. *J Vasc Surg.* 2002;36(4):732–737.
- Wanhainen A, Verzini F, Van Herzele I, et al. Editor's choice—European Society for Vascular Surgery (ESVS) 2019 clinical practice guidelines on the management of abdominal aorto-iliac artery aneurysms. *Eur J Vasc Endovasc Surg.* 2019;57(1):8–93. doi:10.1016/j.ejvs.2018.09.020.
- Cao P, Verzini F, Zannetti S, et al. Device migration after endoluminal abdominal aortic aneurysm repair: analysis of 113 cases with a minimum follow-up period of 2 years. *J Vasc Surg.* 2002;35(2):229–235. doi:10.1067/mva.2002.120045.
- Charlton-Ouw KM, Ikeno Y, Bokamper M, et al. Aortic endograft sizing and endoleak, reintervention, and mortality following endovascular aneurysm repair. *J Vasc Surg.* 2021;74(5):1519–1526.e2. doi:10.1016/j.jvs.2021.04.045.
- Mohan IV, Laheij RJ, Harris PL, et al. Risk factors for endoleak and the evidence for stent-graft oversizing in patients undergoing endovascular aneurysm repair. *Eur J Vasc Endovasc Surg.* 2001;21(4):344–349. doi:10.1053/ejvs.2000.1341.
- Parker MV, O'Donnell SD, Chang AS, et al. What imaging studies are necessary for abdominal aortic endograft sizing? A prospective blinded study using conventional computed tomography, aortography, and three-dimensional computed tomography. *J Vasc Surg.* 2005;41(2):199–205. doi:10.1016/j.jvs.2004.12.010.
- Agarwal PP, Chughtai A, Matzinger FR, et al. Multidetector CT of thoracic aortic aneurysms. *Radiographics.* 2009;29(2):537–552. doi:10.1148/rg.292075080.
- Csobay-Novák C, Fontanini DM, Szilágyi B, et al. Thoracic aortic strain is irrelevant regarding endograft sizing in most young patients. *Ann Vasc Surg.* 2017;38:227–232. doi:10.1016/j.avsg.2016.04.024.
- Csobay-Novák C, Fontanini DM, Szilágyi BR, et al. Thoracic aortic strain can affect endograft sizing in young patients. *J Vasc Surg.* 2015;62(6):1479–1484. doi:10.1016/j.jvs.2015.06.225.
- Parodi J, Berguer R, Carrascosa P, et al. Sources of error in the measurement of aortic diameter in computed tomography scans. *J Vasc Surg.* 2014;59(1):74–79. doi:10.1016/j.jvs.2013.07.005.
- Tolenaar JL, Jonker FH, Moll FL, et al. Influence of oversizing on outcome in thoracic endovascular aortic repair. *J Endovasc Ther.* 2013;20(6):738–745. doi:10.1583/13-4388mr.1.
- Morgan-Hughes GJ, Owens PE, Marshall AJ, et al. Thoracic aorta at multi-detector row CT: motion artifact with various reconstruction windows. *Radiology.* 2003;228(2):583–588. doi:10.1148/radiol.2282020873.
- Gomes VC, Silvestre GC, Queiroz A, et al. Biomechanical analysis of cadaveric thoracic aorta zones: the isthmus is the weakest region. *Ann Vasc Surg.* 2021;77:263–273. doi:10.1016/j.avsg.2021.06.004.
- Lorenzen US, Eiberg JP, Hultgren R, et al. The short-term predictive value of vessel wall stiffness on abdominal aortic aneurysm growth. *Ann Vasc Surg.* 2021;77:187–194. doi:10.1016/j.avsg.2021.05.051.
- Nana P, Dakis K, Brodis A, et al. Circulating biomarkers for the prediction of abdominal aortic aneurysm growth. *J Clin Med.* 2021;10(8):1718. doi:10.3390/jcm10081718.
- Raffort J, Adam C, Carrier M, et al. Artificial intelligence in abdominal aortic aneurysm. *J Vasc Surg.* 2020;72(1):321–333.e1. doi:10.1016/j.jvs.2019.12.026.
- Yu J, Liu S, Huang J, et al. Current theories and clinical trial evidence for limiting human abdominal aortic aneurysm growth. *Curr Drug Targets.* 2018;19(11):1302–1308. doi:10.2174/1389450118666171113114310.



# Az endocsavározás hatékony lehet a juxtarenalis aortaaneurysmák endovascularis kezelésében

Fontanini Daniele Mariastefano dr.<sup>1</sup> ■ Borzsák Sarolta dr.<sup>1</sup>  
 Vecsey-Nagy Milán dr.<sup>1</sup> ■ Jokkel Zsófia dr.<sup>1</sup>  
 Szeberin Zoltán dr.<sup>2,3</sup> ■ Szentiványi András<sup>4</sup> ■ Süvegh András<sup>4</sup>  
 Sótonyi Péter dr.<sup>2,3</sup> ■ Csobay-Novák Csaba dr.<sup>1,2</sup>

<sup>1</sup>Semmelweis Egyetem, Általános Orvostudományi Kar, Városmajori Szív- és Érgyógyászati Klinika, Intervenciós Radiológiai Tanszék, Budapest

<sup>2</sup>Semmelweis Egyetem, Általános Orvostudományi Kar, Városmajori Szív- és Érgyógyászati Klinika, Semmelweis Aortacentrum, Budapest

<sup>3</sup>Semmelweis Egyetem, Általános Orvostudományi Kar, Városmajori Szív- és Érgyógyászati Klinika, Érsebészeti és Endovaszkuláris Tanszék, Budapest

<sup>4</sup>Semmelweis Egyetem, Általános Orvostudományi Kar, Budapest

**Bevezetés:** Az infrarenalis aortaaneurysmák kezelésére alkalmazott endovascularis aortarekonstrukció (EVAR) hosszú távú sikerének egyik meghatározó tényezője a proximális rögzítés minősége. A proximális rögzítés minőségét rontó, ún. nehéz nyakkal rendelkező aneurysmák sikeres kezelésére fejlesztették ki az endocsavározást, melynek során apró fémspirálokkal rögzítjük a beültetett sztentgraftot az aorta falához.

**Célkitűzés:** Vizsgálatunk célja, hogy hazai beteganyagban elemezzük az endocsavározással kiegészített EVAR-műtétek perioperatív és középtávú kockázatát.

**Módszerek:** Retrospektív vizsgálatunk során a profilaktikus endocsavározással kiegészített EVAR-műtéten átesett betegek adatainak analizisét végeztük. Demográfiai és kórelőzményi adatok, a műtétek és a kontrollvizsgálatok, illetve a képalkotó vizsgálatok eredményeit vizsgáltuk.

**Eredmények:** 2019. január 1. és 2021. szeptember 30. között 14 esetben (11 férfi, átlagéletkor  $70,4 \pm 8,1$  év) végeztünk profilaktikus endocsavározással kiegészített EVAR-műtétet. Az esetek 86%-ában (12/14) nehéz nyak miatt történt az endocsavározás, átlagosan  $6,4 \pm 1,7$  csavar felhasználásával. Technikai szövődmény nem lépett fel. A  $7,0 \pm 9,9$  hónapos átlagos követési idő alatt mechanikai szövődményt, tartós Ia típusú endoleaket nem észleltünk. Reintervenció nem történt. A követés alatt egy beteget veszítettünk el aortával nem összefüggő betegségben, így a mortalitási arány 7% (1/14), a klinikai sikerarány 92,9% (13/14).

**Megbeszélés:** Az Európai Érsebészeti Társaság által 2019-ben kiadott irányelv az endocsavarok alkalmazását randomizált vizsgálat hiányában csak klinikai vizsgálat keretében javasolja. A közelmúltban megjelent metaanalízis, illetve nemzetközi regiszter adatain alapuló publikáció eredményeivel összhangban jelen vizsgálatunk során is 90% feletti technikai sikerarányt, alacsony komplikációs rátát és magas Ia endoleak mentességet találtunk.

**Következtetés:** Nagy kockázatú betegcsoporton igazoltuk a Medtronic Heli-FX rendszer hatékonyságát. A módszer sikeresen és biztonságosan alkalmazható nehéz nyakkal komplikált infrarenalis aneurysmák endovascularis kezelésére. Orv Hetil. 2022; 163(16): 632–637.

**Kulcsszavak:** endovascularis technikák, abdominalis aortaaneurysma, endoleak

## Endoanchoring may be effective in the endovascular aortic repair of juxtarenal aneurysms

**Introduction:** Endosuturing, which involves the use of metal screws to fix the implanted stent graft to the aortic wall, was developed as an adjunctive procedure of endovascular aortic repair (EVAR) to treat aneurysms with hostile neck.

**Objective:** The aim of our study was to analyse the perioperative and mid-term risk of EVAR surgery with endosuturing in a Hungarian patient population.

**Methods:** In our retrospective study, we analysed data from patients undergoing EVAR surgery augmented with prophylactic endosuturing. Demographic and anamnestic data, results of surgery and follow-up examinations and imaging studies were analyzed.

**Results:** Between January 1, 2019 and September 30, 2021, 14 cases (11 men, mean age  $70.4 \pm 8.1$  years) underwent EVAR surgery with prophylactic endosuturing. In 86% of cases (12/14), endosuturing was performed due to a hostile neck, using an average of  $6.4 \pm 1.7$  screws. No technical complications occurred. No mechanical complications or persistent Ia endoleak were observed during the mean follow-up of  $7.0 \pm 9.9$  months. Reintervention did not occur. One patient was lost during follow-up due to a disease unrelated to the aorta, resulting in a mortality rate of 7% (1/14) and a clinical success rate of 92.9% (13/14).

**Discussion:** In accordance with recent publications, we found a low complication rate and a technical success rate above 90%.

**Conclusion:** We demonstrated the efficacy of the Medtronic Heli-FX system in a high-risk patient population. The technique can be successfully and safely used for endovascular treatment of infrarenal aneurysms complicated with hostile neck.

**Keywords:** endovascular techniques; aortic aneurysm, abdominal, endoleak

Fontanini DM, Borzsák S, Vecsey-Nagy M, Jokkel Zs, Szeberin Z, Szentiványi A, Süvegh A, Sótonyi P, Csobay-Novák Cs. [Endoanchoring may be effective in the endovascular aortic repair of juxtarenal aneurysms]. *Orv Hetil.* 2022; 163(16): 632–637.

(Beérkezett: 2021. november 26.; elfogadva: 2021. december 10.)

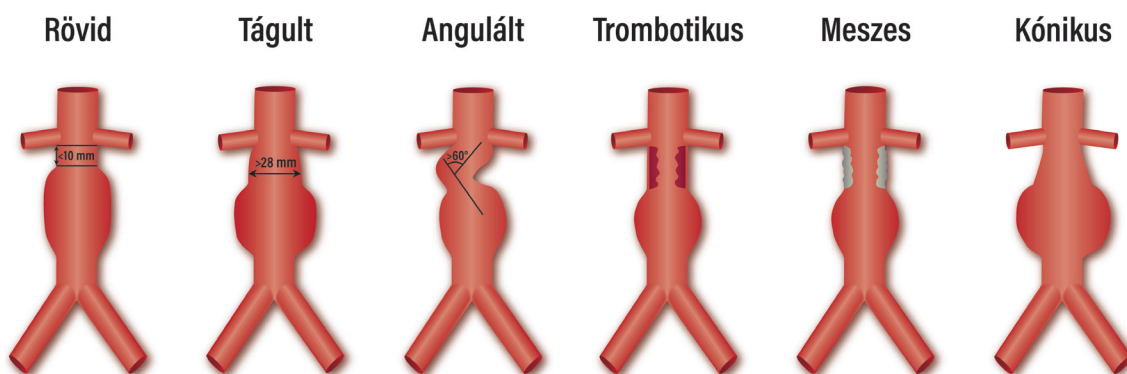
#### Rövidítések

ANCHOR = Aneurysm Treatment Using the Heli-FX Aortic Securement System Global Registry ; CTA = (computed tomography angiography) komputertomográfias angiográfia; EFOP = Emberi Erőforrás Fejlesztési Operatív Program; ESVS = (European Society of Vascular Surgery) Európai Érsebészeti Társaság; EVAR = endovascularis aortarekonstrukció; NVKP = Nemzeti Versenyképességi és Kiválósági Program; OTKA = Országos Tudományos Kutatási Alapprogramok; SD = standard deviáció; VEKOP = Versenyképes Közép-Magyarország Operatív Program

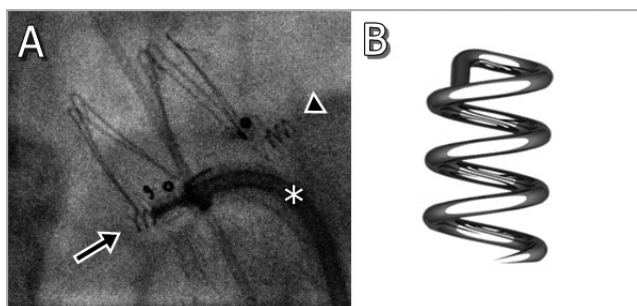
Az infrarenalis aortaaneurysma miatt végzett endovascularis aortarekonstrukció (EVAR) 1998. évi hazai bevezetése óta eltelt több mint két évtizedben ez a módszer hazánkban is a nyitott műtét biztonságos, sikeres és széles körben alkalmazott alternatívájává vált [1]. A sztentgraft-technológia fejlődésével az endovascularis aorta-

műtétek indikációs köre bővült, ma már fenesztrált és elágazó graftokkal tudjuk kezelni a visceralis aortaszegmenst, akár dissectio talaján kialakult tárgulatok esetén [2, 3]. Az EVAR-műtét sikerét alapvetően befolyásolja a sztentgraft proximális rögzítése. Nehéz nyak elnevezéssel foglaljuk össze az infrarenalis aorta kezdeti szakaszának mindazon anatómiai jellegzetességeit, amelyek a proximális rögzítést nehezítik (1. ábra).

A nehéz nyakkal rendelkező hasi aortaaneurysmák kezelése kihívást jelent. Ezen nehézségek leküzdésére, az EVAR-műtétek hatékonyságának növelésére fejlesztették ki az endocsavarozást (Medtronic Heli-FX; Medtronic, Dublin, Írország) [4]. Ennek során egy hajlítható vezetőkatéterrel az aorta falára merőleges irányból a proximális rögzítési zónában több ponton apró fémspirálokat, endocsavarokat hajtunk a sztentgrafton keresztül az aorta falába (2. ábra). Az endocsavarozást döntően primer profilaktikus indikációval, vagyis EVAR-műtéttel egy



1. ábra | A nehéz nyak változatai



2. ábra

A) Csavarbehajtás a graft proximális rögzítési zónájában. Hajlítható vezetőkatéter (\*) segítségével hajtjuk be a csavart a graft proximális rögzítési zónájában (nyíl). Az előző lépésben behajtott csavart nyílhegy jelöli. B) Az acél endocsavar képe (forrás: Medtronic Inc., Dublin, Írország – medtronic.com).

ülésben, mintegy adjuváns beavatkozásként végezzük, a proximális endoleak kialakulásának megelőzésére. A módszerrel kapcsolatban számos közleményben számoltak be biztató kezdeti eredményekről, randomizált tanulmány, illetve metaanalízis hiányában azonban a vonatkozó irányelvek jelenleg csak tanulmányok keretében javasolják a használatát [5].

### Célkitűzés

Célunk volt, hogy hazai beteganyagon is elemezzük az endocsavarozással kiegészített EVAR-műtétek perioperatív és középtávú kockázatát, sikerességét, valamint megvizsgáljuk a szükséges reintervenciók arányát.

### Módszerek

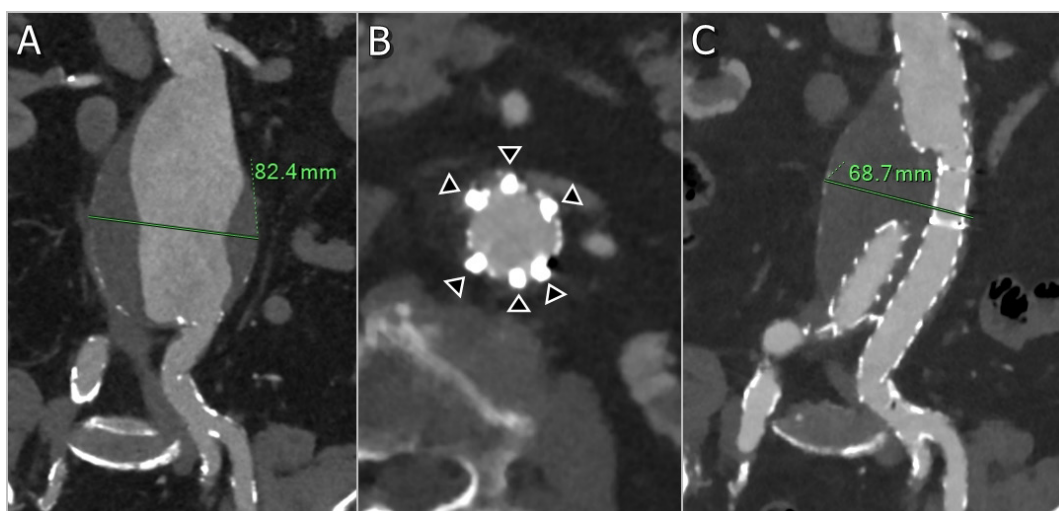
Retrospektív vizsgálatunk során a Semmelweis Aorta-centrumban nehéz nyakú hasi aortaaneurysma miatt endocsavarozással kiegészített EVAR-műtéten átesett bete-

gek adatainak analízisét végeztük. A klinika elektronikus és papíralapú dokumentációjából az alábbi adatokat gyűjtöttük ki: demográfiai és kórelőzményi adatok, az indexbeavatkozás és a kontrollvizsgálatok, illetve a képalkotó vizsgálatok eredményei.

Indexbeavatkozásnak az EVAR-műtétet tekintettük, melynek során a Heli-FX (Medtronic, Dublin, Írország) endocsavarozó rendszerét alkalmaztuk primer profilaktikus indikációval. Primer felhasználásnak tekintettük azt az esetet, amikor a bifurkációs sztentgraft-implantációval egy ülésben történt az eszköz felhasználása. Profilaktikus az indikáció, amikor a tervezés során azonosított ún. nehéz nyak (juxtarenalis aneurysma, trombotikus, meszes és/vagy táguló nyak, megtört nyak, tágult nyak) miatt, a proximális endoleak rövid és hosszú távú kockázatának csökkentésére, előre megfontoltan alkalmaztuk az endocsavarozást.

Kónikus nyaknak tekintettünk minden olyan esetet, amelynél az infrarenalis aorta átmérője az aorta renalisok szájadékától caudalisan 10 mm-en belül legalább 10%-kal nőtt. Trombotikusnak, illetve meszesnek tekintettük a proximális nyakat az ér kerületének legalább 50%-os érintettsége esetén. A nyak angulációját fokban mértük, az infrarenalis nyak és az aorta terminális szakaszának tengelye közötti szög számításával. Nehéz nyaknak tekintettünk minden olyan esetet, melyben a nyak hossza legfeljebb 10 mm volt, vagy átmérője elérte a 28 mm-t (tágult nyak), vagy angulációja meghaladta a 60°-ot, továbbá a trombotikus, illetve meszes nyakat, illetve ha a nyak alakja kónikus volt.

A kimeneteli paraméterek vonatkozásában az *Oderich és mtsai* által 2021-ben publikált definíciókat követtük [6]. Technikai sikernek tekintettük, ha az operátor által szükségesnek ítélt számú csavar elhelyezése sikeres volt, azok penetrációja elégségesnek bizonyult, nem történt



3. ábra

A) Preoperatív CT-vizsgálat kanyarodó multiplanaris rekonstrukciója egy 82 mm átmérőjű juxtarenalis aneurysmáról. B) Posztoperatív CTA-vizsgálat során ábrázolódik a műtét során behelyezett hat endocsavar (nyílhegyek). C) Posztoperatív CTA-vizsgálat kanyarodó multiplanaris rekonstrukciója. A zsugorodó aneurysmazsák a terápia sikerét jelzi.

CT = komputertomográfia; CTA = komputertomográfias angiográfia

technikai szövődmény, és a 30 napos kontroll képalkotó vizsgálaton I. és III. típusú endoleak sem ábrázolódt. Klinikai sikernek tekintettük azt az élő beteget, akinél nem lépett fel aortával összefüggő (ruptura nem történt, a zsák átmérője nem növekedett, képalkotó vizsgálaton I. és III. típusú endoleak nem ábrázolódt) vagy aortától független (stroke, szívinfarktus, veseelégtelenség) major szövődmény.

A sztentgraft-implantációt követő kontrollvizsgálatokat az aktuális irányelveknek megfelelően végeztük: 30 napos kontroll komputertomográfias angiográfia (CTA) eredményétől függően CTA- vagy ultrahangvizsgálatok történtek évente vagy szövődmény gyanúja esetén gyakrabban. Az aneurysmazsákot változatlanak tekintettük, ha legfeljebb 5 mm változás volt mérhető a kiindulási értékhez képest. Növekedésnek az aortaátmérő 5 mm-nél nagyobb tágulását, zsugorodásnak az 5 mm-nél nagyobb csökkenését tekintettük [5].

A kategorikus változókat esetszám (százalék), a folytonos változókat átlag  $\pm$  SD formában tüntettük fel.

Kutatásunkat a Semmelweis Egyetem Regionális, Intézményi Tudományos és Kutatásügyi Bizottságának előzetesen kiadott engedélyével (93/2021) végeztük.

## Eredmények

2019. január 1. és 2021. szeptember 30. között összesen 14 esetben (11 férfi, átlagéletkor:  $70,4 \pm 8,1$  év) végeztünk profilaktikus endocsavarozással kiegészített EVAR-műtétet (3. ábra). Ez idő alatt összesen 214 EVAR-t végeztünk (Heli-FX EVAR: 6,5%). Vizsgálati csoportunk demográfiai adatait az 1. táblázat, az anatómiai és műtéti paramétereit a 2. táblázat tartalmazza.

A beavatkozások során technikai szövődmény egyetlen esetben sem lépett fel. Egy esetben a 30 napos képalkotó vizsgálat során Ia típusú endoleak igazolódt, mely azonban konzervatív kezelés (a gyógyszeres kezelés módosítása: a trombocitaaggregáció-gátló kezelés átmeneti elhagyása) hatására a 3 hónapos kontroll képalkotó vizsgálaton már megszűnt. Így a technikai sikerarány 92,9%-nak adódott (13/14).

2. táblázat | Anatómiai és műtéti paraméterek

	n = 14
Az aneurysma átmérője (mm)	64,9 $\pm$ 10,8
A proximális nyak hossza (mm)	12,2 $\pm$ 6,0
A proximális nyak átmérője (mm)	24,0 $\pm$ 4,1
Nehéz nyak, n (%)	12 (86,0)
Rövid nyak, n (%)	7 (50,0)
Tágult nyak, n (%)	2 (14,0)
Kónikus nyak, n (%)	4 (29,0)
Nagyfokú angulatio, n (%)	3 (21,0)
Trombotikus nyak, n (%)	1 (7,0)
Meszes nyak, n (%)	0 (0,0)
A graft típusa	
Cook Zenith, n (%)	4 (29,0)
Gore Excluder, n (%)	1 (7,0)
Medtronic Endurant, n (%)	7 (50,0)
Terumo Treo, n (%)	2 (14,0)
A graft átmérője (mm)	28,1 $\pm$ 4,2
A graft túlméretezése (%)	17,7 $\pm$ 4,9
A felhasznált endocsavarok száma (n)	6,4 $\pm$ 1,7

A 64,9  $\pm$  10,8 mm átlagos kiindulási aneurysmazsák-átmérő a 7,0  $\pm$  9,9 hónapos követési idő végére 60,6  $\pm$  11,8 mm-re csökkent, az átlagos átmérő szignifikáns mértékben nem változott. Három esetben (21,4%) figyeltünk meg szignifikáns mértékű zsugorodást. A többi esetben az aneurysmazsák stabil volt (11/14, 78,6%), növekedés nem fordult elő (0/14, 0%). Mechanikai szövődményt (csavar törése, migrációja) a követési idő alatt nem észleltünk. Az esetek közel felében (6/14, 42,9%) észleltünk II-es típusú endoleakot a követés során. Mivel ezen esetek egyike sem társult a zsák növekedésével, konzervatív kezelést végeztünk. Reintervenció nem történt (0/14, 0%). A követés során egy beteget veszítettünk el aortával nem összefüggő szövődményben (a műtét utáni 8. hónapban; halál: szívinfarktus), így mortalitási arányunk 7% (1/14), klinikai sikerarányunk 92,9% (13/14).

A 64,9  $\pm$  10,8 mm átlagos kiindulási aneurysmazsák-átmérő a 7,0  $\pm$  9,9 hónapos követési idő végére 60,6  $\pm$  11,8 mm-re csökkent, az átlagos átmérő szignifikáns mértékben nem változott. Három esetben (21,4%) figyeltünk meg szignifikáns mértékű zsugorodást. A többi esetben az aneurysmazsák stabil volt (11/14, 78,6%), növekedés nem fordult elő (0/14, 0%). Mechanikai szövődményt (csavar törése, migrációja) a követési idő alatt nem észleltünk. Az esetek közel felében (6/14, 42,9%) észleltünk II-es típusú endoleakot a követés során. Mivel ezen esetek egyike sem társult a zsák növekedésével, konzervatív kezelést végeztünk. Reintervenció nem történt (0/14, 0%). A követés során egy beteget veszítettünk el aortával nem összefüggő szövődményben (a műtét utáni 8. hónapban; halál: szívinfarktus), így mortalitási arányunk 7% (1/14), klinikai sikerarányunk 92,9% (13/14).

## Megbeszélés

Az endovascularis aortaműtétek 1998. évi hazai bevezetése óta a rendelkezésre álló bifurkációs sztentgraftok proximális rögzítési elve számottevően nem változott. Az egyes gyártók között vannak ugyan eltérések a supra-renal corona, illetve a fixálást biztosító horgok meg-

1. táblázat | Demográfiai adatok

	n = 14
Átlagéletkor (év)	70,4 $\pm$ 8,1
Férfinem, n (%)	11 (78,6)
Társbetegségek	
Hypertonia, n (%)	14 (100,0)
Cukorbetegség, n (%)	0 (0,0)
Koszorúér-betegség, n (%)	3 (21,0)
COPD, n (%)	6 (43,0)
Dohányzás, n (%)	8 (57,0)
Veseelégtelenség, n (%)	2 (14,0)
Műtéti kockázat	
ASA II., n (%)	3 (21,0)
ASA III., n (%)	8 (57,0)
ASA IV., n (%)	3 (21,0)

ASA = az Amerikai Aneszteziológusok Társaságának pontrendszere; COPD = krónikus obstruktív tüdőbetegség

létében vagy hiányában, valamint a proximális graftrész szerkezetének pontos kialakításában, ezek a különbségek azonban alig tükröződnek az eszközök alkalmazási előirataiban: a különböző sztentgraftok indikációs köre igen hasonló. A rövid proximális nyakkal rendelkező juxtarenalis aortaaneurysmák kezelése kezdettől fogva kihívást jelent. Hatékonyabb kezelések már korán megjelentek alternatív módszerek, mint a párhuzamos graftok és a fenesztrált graftok [7, 8]. Az utóbbi módszerek esetében technikailag egyszerűbb az endocsavarozás, melynek során az előbbiekkal ellentétben nincs szükség a veseartériák szelektív katéterezésére és – jellemzően borított – sztenttel történő biztosítására. A módszer hatékonyságáról először 2012-ben jelent meg közlemény [4]. Ezt követően számos közlemény született az ún. ANCHOR (Aneurysm Treatment Using the Heli-FX Aortic Securement System Global Registry) regiszter adataiból [9]. A prospektív, nemzetközi, a gyártó által szponzorált regiszter adatain alapuló egyik első közleményben primer profilaktikus indikáció esetén 96,6%-os technikai sikerarányt és hasonló arányú Ia endoleak mentességet (96,5%) írtak le [9]. Kizárólag primer profilaktikus indikációjú alkalmazással saját vizsgálatunkban hasonló eredményre jutottunk. Ugyanez a munkacsoport középtávú – átlagosan 14 hónapos – követési vizsgálatában igen ritka szövődményként írta le a csavarok törését (3/1118, 0,3%) [10]. Lényegesen kisebb esetszámú saját anyagunkban ez a ritka szövődmény nem fordult elő.

Az ANCHOR regiszter betegpopulációjának elemzése alapján tudjuk azt is, hogy az endocsavarozás a proximális nyak posztoperatív tágulásával szemben protektív faktor lehet [11]. Amennyiben ezt randomizált vizsgálatban, hosszú távon is sikerülne igazolni, lényegesen tudnánk javítani az EVAR hosszú távú hatékonyságát. A módszer egyik gyenge pontja éppen az infrarenalis nyak progresszív dilatációja, és ezáltal proximális szövődmény (Ia típusú endoleak, illetve graftmigráció) kialakulása, mely összefüggést mutat az aorta átmérőjével és a túlméretezés mértékével is [11].

*Muhs és mtsai* ún. „propensity” analízisben igazolták, hogy az endocsavarozással kiegészített EVAR után az aneurysmazsák átmérőjének nagyobb arányú csökkenése következik be a kontrollcsoporthoz képest, továbbá azt, hogy az endocsavarozás csökkentheti a tágult és trombotikus nyak kockázatnövelő szerepét [12].

Bár a bemutatott tudományos munkák a módszer hatékonyságát és biztonságosságát igazolják a juxtarenalis aneurysmák kezelésével kapcsolatban, az Európai Érsebészeti Társaság (ESVS) aktuális, 2019. évi irányelve kellő erősségű bizonyíték (randomizált tanulmány, illetve metaanalízis) híján a módszer alkalmazását egyelőre csak klinikai tanulmányok keretében javasolja [5].

*Qamhavi és mtsai* 2020-ban megjelent munkájukban éppen az előbbi irányelv által hiányolt metaanalízist vé-

gezték el [13]. A primer profilaktikus indikációval kezelt betegcsoport (n = 455) esetén az összesített technikai sikerarány 98,4% volt, míg 3,5% volt a proximális endoleak előfordulása a 15 hónapos átlagos követési idő alatt. A teljes mortalitás 0,8% volt. Alacsony esetszámú vizsgálatunkban hasonló eredményre jutottunk: 90% feletti technikai sikerarányt találtunk, egy esetben előforduló, konzervatív kezeléssel uralható, Ia típusú endoleakkal, számottevő komplikáció és mortalitás nélkül.

A Heli-FX rendszer használatát vizsgáló legnagyobb nemzetközi regiszter (PERU regiszter) adatain alapuló, közelmúltban megjelent tanulmány szerint a módszer középtávon is biztató eredményt mutat a technikai sikerarány (95,5%) és az Ia endoleak mentesség (96%) vonatkozásában is [14]. A PERU regiszter számára történő adatgyűjtésben centrumunk is részt vesz, hosszú távú eredményeink elemzése jövőre várható.

## Következtetés

Retrospektív vizsgálatunkkal hazai viszonylatban is igazoltuk a Medtronic Heli-FX endocsavarozó rendszer hatékonyságát nehéz nyakkal komplikált EVAR-műtétek során. A műtéttechnikai szempontból nagy kockázatú betegcsoportunkban magas technikai sikerarányt, a középtávú követés során magas klinikai sikerarányt és alacsony szövődményráta-találást találtunk, aortához köthető halálozás nélkül. A módszer sikeresen és biztonságosan alkalmazható nehéz nyakkal komplikált infrarenalis aneurysmák endovascularis kezelésére.

*Anyagi támogatás:* A jelen tanulmány megjelenését a Nemzeti Kutatási, Fejlesztési és Innovációs Hivatal támogatta a Nemzeti Szívprogram (NVKP\_16-1-2016-0017), a Befektetés a Jövőbe (2020-1.1.6-JÖVŐ-2021-00013) és az OTKA (K135076 to B.M.) pályázatok keretében. A kutatást továbbá az Innovációs és Technológiai Minisztérium Tématerületi Kiválósági Programja (2020-4.1.1.-TKP2020) finanszírozta, a Semmelweis Egyetem Terápiás fejlesztés és Bioimaging tématerületi programjának keretében. A kutatás „az orvos-, egészség-tudományi és gyógyszerészképzés tudományos műhelyeinek fejlesztése” című (EFOP-3.6.3-VEKOP-16-2017-00009) pályázat támogatásával valósult meg.

*Szerzői munkamegosztás:* F. D. M., B. S., V.-N. M., J. Zs., Sz. A., S. A., Cs.-N. Cs. a vizsgálat lefolytatásában, a kézirat megírásában és a betegek követésében vett részt. Sz. Z., S. P. a cikk javításában és a végleges verzió megalkotásában tevékenykedett. A cikk végleges változatát valamennyi szerző elolvasta és jóváhagyta.

*Érdekeltségek:* A szerzőknek nincsenek érdekeltségeik.

## Irodalom

- [1] Hidi L, Pál D, Boros AM et al. Analysis of data from the National Vascular Registry on infrarenal aortic aneurysms (2010–2019). [Infrarenalis aortaaneurysma-műtétek országos eredményeinek elemzése a Nemzeti Érsebészeti Regiszter alapján (2010–2019).] *Orv Hetil.* 2021; 162: 1233–1243. [Hungarian]
- [2] Csobay-Novák C, Entz L, Banga P, et al. Fenestrated endovascular repair of a thoracoabdominal aortic aneurysm in chronic dissection. [Krónikus aortadissectio talaján kialakult thoracoabdominalis aneurysma endovasculáris kezelése fenesztált sztentgrafttal.] *Orv Hetil.* 2021; 162: 1260–1264. [Hungarian]
- [3] Entz L, Nemes B, Szeberin Z, et al. Fenestrated stent-graft implantation in Hungary. [Fenestált stent-graft beültetés Magyarországon.] *Magy Seb.* 2015; 68: 88–93. [Hungarian]
- [4] Avci M, Vos JA, Kolvenbach RR, et al. The use of endoanchors in repair EVAR cases to improve proximal endograft fixation. *J Cardiovasc Surg (Torino)* 2012; 53: 419–426.
- [5] Wanhainen A, Verzini F, Van Herzele I, et al. Editor's choice – European Society for Vascular Surgery (ESVS) 2019 clinical practice guidelines on the management of abdominal aorto-iliac artery aneurysms. *Eur J Vasc Endovasc Surg.* 2019; 57: 8–93. Erratum: *Eur J Vasc Endovasc Surg.* 2020; 59: 494.
- [6] Oderich GS, Forbes TL, Chaer R, et al. Reporting standards for endovascular aortic repair of aneurysms involving the renal-mesenteric arteries. *J Vasc Surg.* 2021; 73: 4S–52S.
- [7] Greenberg RK, Haulon S, O'Neill S, et al. Primary endovascular repair of juxtarenal aneurysms with fenestrated endovascular grafting. *Eur J Vasc Endovasc Surg.* 2004; 27: 484–491.
- [8] Ohrlander T, Sonesson B, Ivancev K, et al. The chimney graft: a technique for preserving or rescuing aortic branch vessels in stent-graft sealing zones. *J Endovasc Ther.* 2008; 15: 427–432.
- [9] Jordan WD Jr., Mehta M, Varnagy D, et al. Results of the ANCHOR prospective, multicenter registry of EndoAnchors for type Ia endoleaks and endograft migration in patients with challenging anatomy. *J Vasc Surg.* 2014; 60: 885–892.e2.
- [10] Jordan WD Jr., de Vries JP, Ouriel K, et al. Midterm outcome of EndoAnchors for the prevention of endoleak and stent-graft migration in patients with challenging proximal aortic neck anatomy. *J Endovasc Ther.* 2015; 22: 163–170.
- [11] Tassiopoulos AK, Monastiriotis S, Jordan WD, et al. Predictors of early aortic neck dilatation after endovascular aneurysm repair with EndoAnchors. *J Vasc Surg.* 2017; 66: 45–52.
- [12] Muhs BE, Jordan W, Ouriel K, et al. Matched cohort comparison of endovascular abdominal aortic aneurysm repair with and without EndoAnchors. *J Vasc Surg.* 2018; 67: 1699–1707.
- [13] Qamhawi Z, Barge TF, Makris GC, et al. Editor's choice – systematic review of the use of Endoanchors in endovascular aortic aneurysm repair. *Eur J Vasc Endovasc Surg.* 2020; 59: 748–756.
- [14] Reyes Valdivia A, Chaudhuri A, Milner R, et al. Endovascular aortic repair with EndoAnchors demonstrate good mid-term outcomes in physician-initiated multicenter analysis – the PERU registry. *Vascular* 2022; 30: 27–37.

(Csobay-Novák Csaba dr.,  
Budapest, Határőr út 18., 1122  
e-mail: csobay.csaba@med.semmelweis-univ.hu)

# Mellkasiaortastentgraft-beültetések Magyarországon 2012 és 2016 között

Fontanini Daniele Mariastefano dr.<sup>1</sup> ■ Fazekas Gábor dr.<sup>2</sup>  
Vallus Gábor dr.<sup>3</sup> ■ Juhász György dr.<sup>4</sup> ■ Váradi Rita dr.<sup>5</sup>  
Kövesi Zsolt dr.<sup>6</sup> ■ Kolossváry Márton dr.<sup>1</sup> ■ Szeberin Zoltán dr.<sup>1</sup>

<sup>1</sup>Semmelweis Egyetem, Általános Orvostudományi Kar, Városmajori Szív- és Érgyógyászati Klinika, Érsebészeti Tanszék, Budapest

<sup>2</sup>Pécsi Tudományegyetem, Érsebészeti Klinika, Pécs

<sup>3</sup>Magyar Honvédség Egészségügyi Központ, Budapest

<sup>4</sup>Borsod-Abaúj-Zemplén Megyei Kórház és Egyetemi Oktató Kórház, Miskolc

<sup>5</sup>Szegedi Tudományegyetem, Általános Orvostudományi Kar, Sebészeti Klinika, Szeged

<sup>6</sup>Petz Aladár Megyei Oktató Kórház, Győr

Napjainkban a világszerte elterjedt mellkasiaortastentgraft-beültetés hazánkban is egyre nagyobb teret nyer. Eddig a hazai tapasztalatokról átfogó beszámoló nem jelent meg. A módszer elterjedése folyamatban van, az eddigi eredmények elemzése a további kezelési stratégia optimális meghatározása céljából indokolt. A magyar mellkasi stentgraft-műtétek perioperatív eredményeit elemeztük 5 év tapasztalatai alapján. Retrospektív, multicentrikus tanulmányunk keretében adatokat gyűjtöttünk Magyarország minden mellkasi stentgraft-implantációt végző intézményéből. Az adatok jelentése önkéntes volt, 5 év mellkasi aortát érintő stentgraftbeültetési adatait összesítettük. Magyarországon 2012 és 2016 között 131 mellkasiaortastentgraft-beültetést végeztek. A férfiak aránya 67,18%, a betegek átlagéletkora 62,80 év volt. Az elvégzett beavatkozás az esetek 25,19%-ában volt sürgető. A betegek kórelőzményében 13,74%-ban szerepelt cukorbetegség. A beavatkozást az esetek 64,89%-ában aneurysma, 17,56%-ában dissectio, 6,87%-ban traumás aortasérülés és 10,69%-ában egyéb betegség indikálta. Az aortadissectiók esetek 73,91%-ban akutak voltak. Aneurysma miatt 16,47%-ban történt akut beavatkozás ruptura miatt. A stentgraftbeültetések 26,72%-ában végeztek kiegészítő revascularisatiós műtétet a supraaorticus ágakon (debranching). A posztoperatív időszakban az esetek 4,58%-ában alakult ki stroke, 1,53%-ában volt szükség átmeneti vesepótló kezelésre, és 2,29%-ában alakult ki bélischaemia. Harminc napon belüli reoperációra 5,34%-ban volt szükség. A műtétek 30 napos mortalitása 9,92% volt, az 5 éves utánkövetés során bekövetkezett hosszú távú halálozás 16,03%-ot ért el. A mellkasi aorta stentgrafttal történő endovascularis helyreállító műtétje hatékony eljárás, előnyei egyértelműek a hazai adatok alapján is a nyitott mellkasi műtétekkel szemben. További hazai elterjedése a centralizált érsebészeti ellátás kialakításának és a megfelelő finanszírozásnak a függvénye. Az optimális kezelés biztosításához elengedhetetlen a társszakmák jelenléte és a megfelelő logisztika biztosítása.

Orv Hetil. 2018; 159(2): 53–57.

**Kulcsszavak:** mellkasi aorta, endovascularis, stentgraft, adatbázis

## Thoracic aortic stentgraft implantations in Hungary from 2012 to 2016

Thoracic aortic endograft implantation has become a widespread procedure in recent years, yet no report is available about Hungarian outcomes. Examination of our results is crucial to define further treatment strategies. Analysis of perioperative data from Hungarian thoracic endograft implantations based on the experience of 5 years is presented. Our retrospective, multicentric study analysed voluntarily reported data from all Hungarian institutions where thoracic endograft implantations are performed. Information was collected from every procedure performed in 5 years. Between 2012 and 2016, 131 thoracic stent graft implantations were performed in Hungary (67.18% male, mean age 62.80 years). 25.19% of the procedures were acute. 13.74% of the patients were diabetic. Indications for the procedure were aneurysm (64.89%), dissection (17.56%), aortic trauma (6.87%) and other conditions (10.69%). 73.91% of the dissection cases were acute. 16.47% of repaired aneurysms were ruptured. Additional preoperative revascularization (debranching) was performed in 26.72% of the cases. Postoperative stroke occurred in 4.58%, temporary hemodialysis was needed in 1.53%, bowel ischaemia was present in 2.29% and reoperation within 30 days was

needed in 5.34% of all cases. Thirty-day mortality of the procedure was 9.92%, 5-year long-term mortality reached 16.03%. Endovascular repair of the thoracic aorta is an effective procedure and our national data confirmed its advantages compared to open thoracic surgery. Further use of the procedure in Hungary depends on the centralised care in vascular surgery and financial matters. Multidisciplinary cooperation and proper logistics are needed to provide patients with optimal treatment.

**Keywords:** thoracic aorta, endovascular, stent graft, database

Fontanini DM, Fazekas G, Vallus G, Juhász Gy, Váradi R, Kövesi Zs, Kolossváry M, Szeberin Z. [Thoracic aortic stentgraft implantations in Hungary from 2012 to 2016]. *Orv Hetil.* 2018; 159(2): 53–57.

(Beérkezett: 2017. október 9.; elfogadva: 2017. november 9.)

### Rövidítések

ESVS = European Society for Vascular Surgery (Európai Érsebészeti Társaság); MAÉT = Magyar Angiológiai és Érsebészeti Társaság; PTE = Pécsi Tudományegyetem; SD = standard deviáció; SZTE = Szegedi Tudományegyetem; TEVAR = thoracic endovascular aortic repair (mellkasi endovascularis aorta-rekonstrukció); ThAA = thoracic aortic aneurysm (mellkasi aorta-aneurysma)

A mellkasi aorta stentgrafttal történő helyreállító műtétje (thoracic endovascular aortic repair, TEVAR) világszerte elterjedőben lévő eljárás, mely a kifejlesztése óta új távlatokat nyitott a mellkasi aorta betegségeinek korszerű kezelésében [1, 2]. A betegellátás invazivitását minimálisra csökkentő módszer lehetővé teszi, hogy az aorta műtéti helyreállítása megoldást jelentsen olyan esetekben is, amelyekben a nyitott sebészi beavatkozás kivitelezhetetlen volna [3]. Ennek fényében a TEVAR Magyarországon is egyre szélesebb körben alkalmazott eljárás, a módszer alkalmazásával szerzett hazai tapasztalatokról azonban mindeddig nem jelent meg átfogó beszámoló. A Magyar Angiológiai és Érsebészeti Társaság (MAÉT) Érsebészeti Regisztere alapján készült, 2015-ben az *Orvosi Hetilap* hasábjain publikált tanulmány beszámolt az infrarenalis aortaaneurysmák magyarországi ellátásának részleteiről [4, 5]. Célkitűzésünk az volt, hogy ehhez hasonlóan a hazánkban végzett TEVAR-műtétek 5 éves perioperatív adatait felhasználva országos adatbázist hozzunk létre, mely tapasztalatok összessége a jövőben lehetővé teszi a betegek kezelésének optimalizálását.

### Módszer

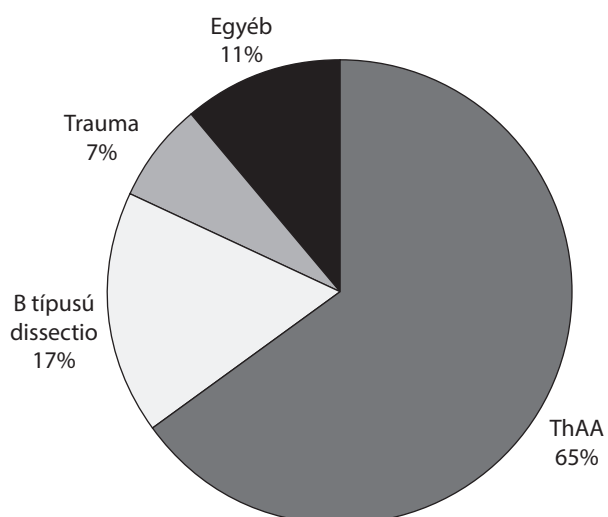
Retrospektív, multicentrikus tanulmányunk során adatgyűjtést végeztünk minden olyan magyarországi intézményt bevonva, ahol 2012. 01. 01. és 2016. 12. 31. között mellkasiaortastentgraft-beültetést végeztek. A Semmelweis Egyetem Városmajori Szív- és Érgyógyászati Klinikájának összegyűjtött és rendszerezett adatait ezáltal a budapesti Magyar Honvédség Egészségügyi Központ, a PTE Érsebészeti Klinika, az SZTE Sebészeti Klinika, a miskolci Borsod-Abaúj-Zemplén Megyei Kór-

ház és Egyetemi Oktató Kórház, valamint a győri Petz Aladár Megyei Oktató Kórház által önkéntesen szolgáltatott adatok felhasználásával országos adatbázissá alakítottuk, amelyben szerepel az említett 5 éves időintervallumban hazánkban végzett összes mellkasi stentgraftbeültetés. Statisztikai elemzésünk során Kaplan–Meier-próbát alkalmaztunk IBM SPSS Statistics 23.0 szoftver felhasználásával (IBM Corporation, Armonk, NY, USA). Vizsgálatunkat a személyes adatok védelméről és közérdekű adatok nyilvánosságáról szóló hatályos törvények figyelembevételével, a Semmelweis Egyetem Regionális, Intézményi Tudományos és Kutatásetikai Bizottsága által rendelkezésünkre bocsátott, 92/2017. számú etikai engedély birtokában vittük véghez. Személyazonosításra alkalmas egészségügyi adatok nem kerültek feldolgozásra.

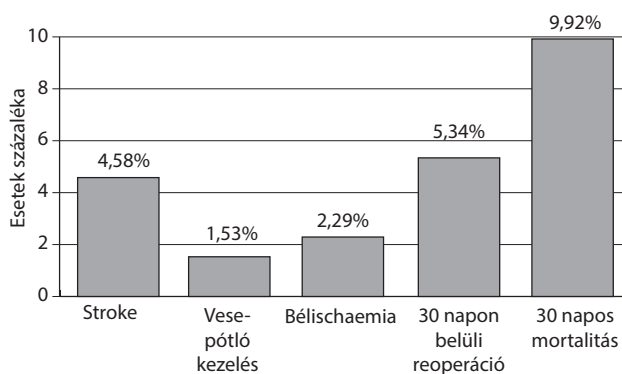
### Eredmények

Hazánkban 2012. 01. 01. és 2016. 12. 31. között összesen 131 esetben végeztek mellkasi stentgraftbeültetést. A Semmelweis Egyetem Városmajori Szív- és Érgyógyászati Klinikáján 57, a PTE Érsebészeti Klinikán 25, a Magyar Honvédség Egészségügyi Központban 24, a miskolci Borsod-Abaúj-Zemplén Megyei Kórház és Egyetemi Oktató Kórházban 13, az SZTE Sebészeti Klinikán 7, a győri Petz Aladár Megyei Oktató Kórházban 5 műtétet végeztek. A beavatkozásokon átesett betegek átlagos életkora 62,80 ( $\pm 15,3$  SD) év volt. Nemek szerinti eloszlás: az esetek 67,18%-ában férfi betegen végezték az implantációt. A cukorbeteg aránya 13,74% volt. A TEVAR az esetek 25,19%-ában akut, míg 74,81%-ában elektív intervenció volt. A beavatkozások javallata tekintetében a TEVAR-t igénylő kórképek között a mellkasi aorta-aneurysma (ThAA) volt a leggyakoribb: 64,89%. A TEVAR-ral kezelt ThAA-k közül az esetek 16,47%-ában az aneurysma rupturája állt fent. A Stanford B típusú aortadissectio volt a második leggyakoribb betegség, mely a TEVAR-műtétek 17,56%-át indikálta. Ennél a kórképnél az akut beavatkozások aránya 73,91% volt. Az összes eset 6,87%-ában az implantáció javallata tompa mellkasiaorta-sérülés volt, míg a maradék 10,69%-ban egyéb okból volt szükség mellkasiaortastentgraft-beülte-

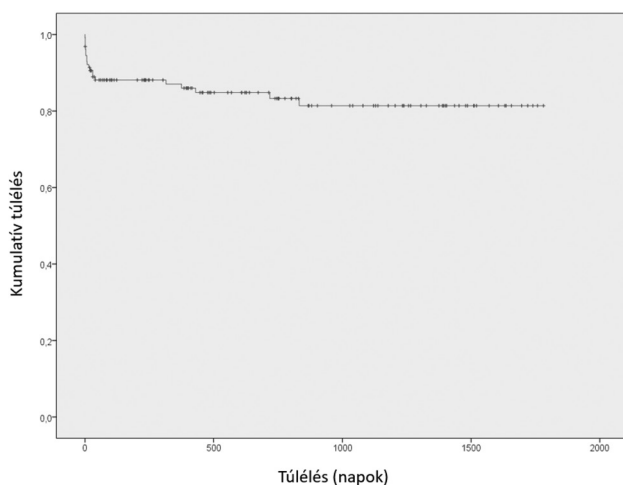




1. ábra | A hazai mellkasi aortastentgraft-implantációk indikáció szerinti megoszlása 2012 és 2016 között



2. ábra | Posztoperatív szövődmények



3. ábra | A hosszú távú halálozás 5 év utánkövetés során

tésre (posztoperatív endoleak, plakkruptura, intramuralis haematoma) (1. ábra). A stentgraftbeültetések 26,72%-ában végeztek kiegészítő műtétet a supraaorticus ágakon (debranching). A korai posztoperatív időszakban TEVAR

után 4,58%-ban következett be stroke, a posztoperatív intenzív terápia során átmeneti vesepótló kezelés az esetek 1,53%-ában vált szükségessé, valamint 2,29%-ban alakult ki a belek ischaemiája. A vizsgált időszakban bekövetkezett posztoperatív szövődmények aránya a 2. ábrán látható. Az elvégzett mellkasi stentgraft-implantációkat követően 30 napon belül 5,34%-ban vált szükségessé a betegek reoperációja. A 30 napon belül bekövetkezett halálozások aránya 9,92% volt. A rövid távú mortalitásnak az indikáció, valamint sürgősség szerinti eloszlását az 1. táblázat szemlélteti részletesen. A vizsgált 5 éves időintervallumban, mely alatt a betegek szoros utánkövetés alatt álltak, 16,03%-os volt a hosszú távú mortalitás (3. ábra).

1. táblázat | A 30 napos mortalitás eloszlása a beavatkozás indikációja és sürgőssége szerint

	ThAA	B típusú dissectio	Trauma	Egyéb
Akut	3 (33,33%)	3 (18,75%)	2 (28,57%)	0 (0%)
Elektív	4 (5,26%)	0 (0%)	0 (0%)	1 (7,69%)

ThAA = thoracic aortic aneurysm (mellkasi aorta-aneurysma)

## Megbeszélés

Tanulmányunk során elsődleges célkitűzésünk az volt, hogy átfogó képet kapjunk a Magyarországon végzett mellkasi stentgraftbeültetések rövid távú perioperatív adatairól, valamint az eljárás hosszú távú eredményeiről. Az adatok beküldése folyamatos kommunikációt igényelt a hazánkban TEVAR-t végző intézmények munkatársaival, akik az intézmények belső adatbázisaiból tettek szert a szükséges információkra. A 2002-ben üzembe helyezett Érsebészeti Regiszter országszerte történő egységes használatával lehetőség nyílik a vizsgálatunkhoz hasonló jövőbeli kutatások hatékony kivitelezésére, ezért javasolt, hogy a Regiszterbe történő rendszeres adatbevitel a centrumokban történő érsebészeti ellátás mindennapi részét képezze [4, 5].

Hazánkban a vizsgált időintervallum alatt összesen 131 alkalommal került sor mellkasi stentgraft-implantációra. A műtétek száma és a beavatkozásokon átesett betegek átlagéletkora (62,80 év) alacsonyabb, mint a hasonló európai vizsgálatok eredményei. Egy, Svédország érsebészeti regisztereinek 1987 és 2002 között jelentett, több mint 14 000 esetből származó adatait feldolgozó tanulmány során a mellkasi aorta-aneurysmában vagy -dissectióban szenvedő betegek átlagéletkora 70 ( $\pm 12$  SD) év volt [6]. A vizsgálatunkban szereplő betegek átlagéletkora a fiatal, traumás aortasérüléseken átesett betegek életkorát is magában foglalja, ez magyarázza hazánkban az alacsonyabb értéket és a szélesebb szórást. Adataink korrelációt mutatnak a MAÉT Érsebészeti Regiszter 2013-as eredményeivel: ez az aortaműtétek mellett a nyaki verőérműtétek és az alsó végtagi verőérműtétek adatait is feldol-

gozta, s az akkor vizsgált érműtétekben szintén a 60–70 éves korcsoport volt a leginkább érintett [7].

Figyelemre méltó adat a betegek anamnézisében szereplő cukorbetegség aránya, mely nem haladja meg a 13,74%-ot. Az érték alátámasztja, hogy a hasi aortaaneurysmák kialakulását és progresszióját ismertén gátló diabetes mellitus ugyanazon molekuláris patobiokémiai mechanizmussal a mellkasiaorta-aneurysmák kialakulását is negatívan befolyásolja, ez eredményezheti a tanulmányunkban szereplő cukorbetegség alacsony arányát [8].

Az akut beavatkozások aránya 25,19% volt, azaz minden negyedik, Magyarországon elvégzett TEVAR akut indikációval történt. Fontos kiemelni, hogy az aorta endovascularis helyreállítása sürgető eseteknél is személyre szabott, precíz preoperatív tervezést igényel [9, 10], ezért az eljárást végző centrumokban szükség van az ezt megalapozó, akut esetekben is mindenkor elérhető logisztikai háttérre.

A TEVAR alkalmazásának javallatai tekintetében szembetűnő, hogy hazánkban a beavatkozást igénylő betegek majdnem kétharmada (64,89%) mellkasiaorta-aneurysma (ThAA) miatt került műtetre. Az adatok mutatják, hogy az aneurysma miatt végzett mellkasi stentgraftbeültetések legnagyobb részében a műtét elektív volt, és csak az esetek 16,47%-ában állt fenn az aorta rupturája, mely a rövid távú halálozás szempontjából lényegesen magasabb rizikójú állapotot jelent.

A ThAA után a második leggyakoribb, TEVAR-t indokló betegség a komplikált Stanford B típusú aortadissectio. Szembetűnő, hogy e kórkép esetén jóval magasabb az akut beavatkozások aránya (73,91%), mivel a deszcendens aortára lokalizálódó aortadissectio akkor képez műtéti indikációt, ha az akutan, komplikációkkal jelentkezik, vagy olyan esetben, amikor egy krónikus, nem komplikált aortadissectio hevenyen progrediálva szövődményessé válik [3, 11–13].

A mellkasi aorta tompa traumája a beavatkozások 6,87%-át indikálta a vizsgált időszakban. E ritka, ám fiatalokat is érintő és gyakran életveszélyes állapotot okozó kórkép első választandó terápiája a TEVAR, éppúgy, mint a fent említett ThAA és komplikált B típusú aortadissectio esetében [13–15].

Az eddig említett kórképek mellett a vizsgált esetek 10,69%-ában egyéb ok indikálta a mellkasi stentgraftbeültetést. Az indikáció ebben a csoportban a legtöbb esetben a korábbi stentgraftbeültetések hosszú távú szövődményeként megjelent endoleak volt, mely reoperációt igényelt. Fontos ennek kapcsán megjegyezni, hogy a TEVAR-on átesett betegek utánkövetése, rendszeres posztoperatív kontrollja CT-angiográfia alkalmazásával kiemelt fontosságú e szövődmények korai észlelésének és kezelésének érdekében [16].

A beavatkozások 26,72%-ában kiegészítő revascularisatiós műtétet végeztek a supraaorticus ágakon (debranching). Erre azért van szükség, mert például ThAA miatt végzett TEVAR során a morfológia következtében egy vagy több supraaorticus ág lefedése válhat szükséges-

sé. A leggyakrabban a bal arteria subclavia érintett, és számos esetben lefedésre kerül, mert akut beavatkozásoknál a legtöbbször nincs lehetőség revascularisatióra. Elektív beavatkozások végzésekor viszont törekedni kell a lehető legtökéletesebb revascularisatióra, mert csupán a bal arteria subclavia eredésének lefedése is neurológiai szövődményekhez (gerincvelői ischaemia) vagy felső végtagi ischaemiához vezethet. Erre lehetőséget biztosít a preoperatív, külön ülésben elvégzett debranching műtét vagy a nyitott sebészi beavatkozást elkerülhetővé tevő, világszerte egyre nagyobb teret nyerő új endovascularis eljárások, melyek biztosítják a lefedett supraaorticus ágak perfúzióját (például fenesztrált stentgraftok, chimney technika, scallop technika) [17–19].

A műtétek kapcsán elszenvedett stroke (4,58%) és a rövid távú, 30 napos mortalitás (9,92%) értékeit összehasonlítva a European Society for Vascular Surgery (ESVS) 2017-es guideline-jával megfigyelhető egyrészt, hogy a posztoperatív stroke incidenciája az európai átlagnál (5,4%) alacsonyabb volt, míg a rövid távú mortalitás megközelíti az európai átlagot, mely ThAA-nál 5,57%, aortadissectiónál pedig 2,6–9,8% közé tehető. Másrészt szembetűnik, hogy európai adatok szerint a TEVAR mind a rövid távú halálozás, mind a posztoperatív stroke incidenciája szempontjából előnyösebb eljárásnak mondható, mint a nyitott mellkasiaorta-sebészeti eljárások, melyek esetén a posztoperatív stroke incidenciája eléri a 14%-ot, a rövid távú mortalitás pedig ThAA-nál 16,5%, míg aortadissectió esetekben 25–50% [13]. A TEVAR-t a nyitott sebészi eljárásokkal összehasonlító hazai adatok jelenleg még nem állnak rendelkezésünkre.

A perioperatív szakban bekövetkezett bélischaemia (2,29%), illetve a szükségessé vált vesepótló kezelés (1,53%) alacsony incidenciája arra vezethető vissza, hogy a vizsgált időszakban történt beavatkozások során nem került sor a zsigeri ágak, illetve a veseartériák stentgrafttal történő lefedésére. Azon ritka esetekben, amikor primer és szekunder beavatkozások során szükségessé vált a thoracoabdominalis átmenet rövid szakaszú lefedése, a truncus coeliacus perfúzióját fedett stentimplantációval, illetve scalloped stentgraft alkalmazásával sikerült fenntartani. Veseartériák eszközös lefedésére nem volt példa mellkasi beavatkozások során. Az említett szövődmények tehát nem a műtétek következményei, hanem a beavatkozást indikáló kórképek következményei voltak (malperfúziós szindróma B típusú dissectióban). Hazai adataink hasonló arányokat mutatnak az elérhető nemzetközi irodalomban leírtakhoz, ahol e két ritka szövődmény előfordulása 5% alatti [20, 21].

Az 5 éves halálozás 16,03%-ot ért el. Az utánkövetés esetenkénti pontatlansága, illetve a betegekről rendelkezésre álló korlátozott mennyiségű hosszú távú posztoperatív információ limitálta adatgyűjtésünk precizitását. Ennek következtében nem ítéhető meg pontosan, hogy az első 30 posztoperatív nap és az utánkövetés vége között elhunyt betegek esetében a fennálló aortabetegség volt-e a halál oka.

## Következtetések

Az endovascularis stentgraftbeültetés megbízható, eredményes módja a mellkasi aorta-betegségek korszerű kezelésének. Az eljárás hatékonyságát bizonyító, nagy számban megjelent nemzetközi eredmények mellett hazai adatok is alátámasztják az endovascularis intervenció előnyeit a hagyományosan alkalmazott nyitott sebészeti eljárásokkal szemben.

A módszer további elterjedésének alapjára lenne az aortabetegségek magyarországi érsebészeti ellátásának magas progresszivitási szintű centrumokba történő átszervezése. Emellett a költséges műtéti eljárás finanszírozásának optimalizálására van szükség, mely költség azonban bőségesen megtérül a rövidebb intenzív osztályos és kórházi ápolási időnek és a betegek korábbi munkába állásának köszönhetően.

A sokszor akutan végzett beavatkozások kivitelezése összehangolt logisztikai feladatot jelent, emellett multidiszciplináris együttműködésre van szükség az érsebészet és társszakmái között annak érdekében, hogy betegekink a jelenleg elérhető legmagasabb szintű ellátásban részesülhessenek.

*Anyagi támogatás:* A közlemény megírása, illetve a kapcsolódó kutatómunka anyagi támogatásban nem részesült.

*Szerzői munkamegosztás:* F. D. M., Sz. Z.: A vizsgálat és a közlemény felépítésének kidolgozása, az irodalmi háttér áttekintése, az adatok feldolgozása és rendszerezése, a statisztikai számítások értékelése, a cikk szövegének megfogalmazása. F. G., V. G., J. Gy., V. R., K. Zs.: Adatok gyűjtése, feldolgozása és jelentése. K. M.: Statisztikai elemzés. A közlemény végleges változatát valamennyi szerző elolvasta és jóváhagyta.

*Érdekeltségek:* A szerzőknek nincsenek érdekeltségeik.

## Irodalom

- [1] Dake MD, Miller DC, Semba CP, et al. Transluminal placement of endovascular stent-grafts for the treatment of descending thoracic aortic aneurysms. *N Engl J Med.* 1994; 331: 1729–1734.
- [2] Volodos NL, Shekhanin VE, Karpovich IP, et al. A self-fixing synthetic blood vessel endoprosthesis. *Vestn Khir Im I I Grek.* 1986; 137: 123–125.
- [3] Grabenwöger M, Alfonso F, Bachet J, et al. Thoracic Endovascular Aortic Repair (TEVAR) for the treatment of aortic diseases: a position statement from the European Association for Cardio-Thoracic Surgery (EACTS) and the European Society of Cardiology (ESC), in collaboration with the European Association of Percutaneous Cardiovascular Interventions (EAPCI). *Eur J Cardiothorac Surg.* 2012; 42: 17–24.
- [4] Hidi L, Menyhei G, Kováts T, et al. Report of the Hungarian Vascular Registry's data of infrarenal aortic aneurysms (2010–2014). [Magyarországon végzett infrarenalis aortaaneuryszműtétek eredményei az Érsebészeti Regiszter adatai alapján (2010–2014).] *Orv Hetil.* 2015; 156: 1991–2002. [Hungarian]
- [5] Menyhei G, Simó G, Szeberin Z, et al. Establishment and functioning of the Vascular Registry in Hungary. [Az Érsebészeti Regiszter működtetése során szerzett tapasztalatok.] *Orv Hetil.* 2014; 155: 755–760. [Hungarian]
- [6] Olsson C, Thelin S, Ståhle E. Thoracic aortic aneurysm and dissection: increasing prevalence and improved outcomes reported in a nationwide population-based study of more than 14,000 cases from 1987 to 2002. *Circulation* 2006; 114: 2611–2618.
- [7] Szeberin Z, Hidi L, Kováts T, et al. Report of the 2013 data of the Hungarian Vascular Registry. [Az Érsebészeti Regiszter 2013-as adatainak elemzése.] *Magy Seb.* 2014; 67: 362–371. [Hungarian]
- [8] Pafli K, Gouni-Berthold I, Papanas N, et al. Abdominal aortic aneurysms and diabetes mellitus. *J Diabetes Complications* 2015; 29: 1330–1336.
- [9] Csobay-Novák Cs, Fontanini DM, Szilágyi BR, et al. Thoracic aortic strain can affect endograft sizing in young patients. *J Vasc Surg.* 2015; 62: 1479–1484.
- [10] Parodi J, Berguer R, Carrascosa P, et al. Sources of error in the measurement of aortic diameter in computed tomography scans. *J Vasc Surg.* 2014; 59: 74–79.
- [11] Dake MD, Kato N, Mitchell RS, et al. Endovascular stent-graft placement for the treatment of acute aortic dissection. *N Engl J Med.* 1999; 340: 1546–1552.
- [12] Erbel R, Aboyans V, Boileau C, et al. 2014 ESC Guidelines on the diagnosis and treatment of aortic diseases: Document covering acute and chronic aortic diseases of the thoracic and abdominal aorta of the adult. The Task Force for the Diagnosis and Treatment of Aortic Diseases of the European Society of Cardiology (ESC). *Eur Heart J.* 2014; 35: 2873–2926.
- [13] Rimbau V, Böckler D, Brunkwall J, et al. Editor's Choice – Management of Descending Thoracic Aorta Diseases – Clinical Practice Guidelines of the European Society for Vascular Surgery (ESVS). *Eur J Vasc Endovasc Surg.* 2017; 53: 4–52.
- [14] Mihály Zs, Banga P, Szatai L, et al. Endovascular treatment of blunt thoracic aortic injuries. [Tompai trauma okozta mellkasi aortasérülések endovascularis ellátása.] *Magy Seb.* 2017; 70: 13–17. [Hungarian]
- [15] Dzsini Cs, Zsíros L, Vallus G et al. Blunt trauma of the thoracic aorta – treatment options, results. [A mellkasi aorta tompai sérülése – kezelési taktika, eredmények.] *Magy Seb.* 2015; 68: 155–166.
- [16] Stavropoulos SW, Carpenter JP. Postoperative imaging surveillance and endoleak management after endovascular repair of thoracic aortic aneurysms. *J Vasc Surg.* 2006; 43(Suppl): A89–A93.
- [17] Cooper DG, Walsh SR, Sadat U. Neurological complications after left subclavian artery coverage during thoracic endovascular aortic repair: a systematic review and meta-analysis. *J Vasc Surg.* 2009; 49: 1594–1601.
- [18] Criado FJ, McKendrick C, Criado FR. Technical solutions for common problems in TEVAR: managing access and aortic branches. *J Endovasc Ther.* 2009; 16(Suppl 1): 63–79.
- [19] Szeberin Z, Nemes B, Csobay-Novák Cs, et al. Proximal scalloped custom-made Relay® stent graft in chronic type B dissection: endovascular repair in a drug abuser patient. *Interv Med Appl Sci.* 2016; 8: 37–40.
- [20] Abraham CZ, Chuter TA, Reilly LM, et al. Abdominal aortic aneurysm repair with the Zenith stent graft: short to midterm results. *J Vasc Surg.* 2002; 36: 217–224.
- [21] Szeto WY, McGarvey M, Pochettino A. Results of a new surgical paradigm: endovascular repair for acute complicated type B aortic dissection. *Ann Thorac Surg.* 2008; 86: 87–94.

(Fontanini Daniele Mariastefano dr.,  
Budapest, Mészáros u. 60/C, 1016  
e-mail: fontanini.med@gmail.com)