

SEMMELWEIS EGYETEM
DOKTORI ISKOLA

Ph.D. értekezések

3090.

FERENCZ BENCE

Légzőszervi megbetegedések
című program

Programvezető: Dr. Müller Veronika, egyetemi tanár

Témavezető: Dr. Megyesfalvi Zsolt, tudományos munkatárs

The immunologic landscape of intermediate- and high-grade neuroendocrine lung tumors

Ph.D. thesis

Bence Ferencz, MD

Rácz Károly Conservative Medicine Division
Doctoral College of Semmelweis University



Supervisor: Zsolt Megyesfalvi, MD, Ph.D.

Official reviewers: Gertrud Fórika, MD, Ph.D.
Zsuzsanna Csoma, MD, Ph.D.

Head of the Complex Examination Committee: József Tímár MD, D.Sc.

Members of the Complex Examination Committee: Anna Sebestyén, D.Sc.
Imre Barta, Ph.D

Budapest

2024

Table of contents

List of Abbreviations	3
1. Introduction	5
<i>1.1. Epidemiology.....</i>	<i>5</i>
<i>1.3. Current clinical management.....</i>	<i>8</i>
<i>1.4. Immunotherapy and immune checkpoint inhibitors</i>	<i>10</i>
2. Objectives	12
3. Methods	13
<i>3.1 Study population and treatment</i>	<i>13</i>
<i>3.2 Immunohistochemistry</i>	<i>13</i>
<i>3.3 Statistical analyses</i>	<i>17</i>
4. Results.....	19
<i>4.1. Patient and sample characteristics</i>	<i>19</i>
<i>4.2. The expression pattern of the investigated markers by tumor cells</i>	<i>22</i>
<i>4.3. Unsupervised hierarchical clustering of LNEN according to the expression patterns of immune-related and immunotherapeutic target markers by tumor cells.....</i>	<i>28</i>
<i>4.4. The expression pattern of markers defined by immune cells varies across LNEN subtypes.....</i>	<i>31</i>
<i>4.5. Unsupervised hierarchical clustering of samples according to the immune cell-based TIM</i>	<i>33</i>
<i>4.6. Overall immunological phenotype distinguishes LNEN tumors</i>	<i>35</i>
<i>4.7. Multinomial penalized linear regression model predicts the LNENs' histological subtype.....</i>	<i>36</i>
5. Discussion	39
6. Conclusions	47
7. Summary.....	48
8. References.....	49
9. Bibliography of the candidate's publications	69
<i>9.1. List of publications that served as a basis for the current thesis</i>	<i>69</i>
<i>9.2. Other publications.....</i>	<i>70</i>
10. Acknowledgments	73

List of Abbreviations

AC, Atypical carcinoid
APC, Antigen presenting cell
ASCO, American Society of Clinical Oncology
ASCL1, Achaete-Scute Homologue 1
CHT, Chemotherapy
COPD, Chronic obstructive pulmonary disease
CTLA4, Cytotoxic T-lymphocyte associated protein 4
DAB, 3-3'-diaminobenzidine
ECS, Ectopic Cushing's syndrome
FFPE, Formalin-fixed, paraffin-embadded
GITR, Glucocorticoid-induced TNF receptor
H&E, Hematoxylin and eosin
ICOS, Inducible T-cell costimulator
ICI, Immune checkpoint inhibitors
IC, Immune cell
IDO, Indolamine 2,3-dioxygenase
IHC, Immunohistochemistry
KEAP1, Kelch-like ECH-associated protein
KRAS, Kirsten rat sarcoma virus
LAG3, Lymphocyte-activation gene 3
LCNEC, Large cell neuroendocrine carcinoma
LEMS, Lambert-Eaton myasthenic syndrome
LNEC, Lung neuroendocrine carcinoma
LNEN, Lung neuroendocrine neoplasm
LNET, Lung neuroendocrine tumor
MEN1, Multiple endocrine neoplasia 1
NeuroD1, Neurogenic differentiation factor 1
NCCN, National Comprehensive Cancer Network
NET, Neuroendocrine tumor
NK, Natural killer
NKG2A, CD94/NK Group 2 Member A

NSCLC, Non-small cell lung cancer
OS, Overall survival
OTP, Orthopedia homeobox protein
PCA, Principal component analysis
PCI, Prophylactic cranial irradiation
PD-1, Programmed cell death protein 1
PD-L1, Programmed death-ligand 1
PFS, Progression-free survival
PNECH, Pulmonary neuroendocrine cell hyperplasia
PNS, Paraneoplastic syndromes
POU2F3, POU class 2 homeobox 3
RB1, Retinoblastoma protein 1
RT, Radiotherapy
SCLC, Small cell lung cancer
SIADH, Syndrome of inappropriate antidiuretic-hormone
STAS, Spread through air spaces
STK11, Serine/threonine kinase 11
TMB, Tumor mutation burden
TC, Typical carcinoid
TIM, Tumor immune microenvironment
TIM3, T cell immunoglobulin and mucin domain 3
TP53, Tumor protein 53
VISTA, V-domain Ig suppressor of T cell activation
WHO, World Health Organization
YAP1, Yes-associated protein 1

1. Introduction

1.1. Epidemiology

Lung cancer is one of the most common malignancies and the leading cause of cancer-related deaths worldwide. According to the 2018 GLOBOCAN estimates, around 2,094,000 new cases are diagnosed each year. In 2018, lung cancer accounted for an estimated 1,761,000 deaths (18.4% of all cancer-related deaths worldwide).(1-5) In 2012, the prevalence of lung cancer in Hungary among men and women was 109.3 and 46.5 per 100,000 people, respectively. Notably, this number increased to 111.6 and 58.7 per 100,000 people (men and women, respectively) in 2018.(6)

Lung neuroendocrine neoplasms (LNENs) are a heterogeneous group of tumors that mostly originate from the neuroendocrine cells or also known as Kultchisky cells of the lung. They account for approximately 20% of primary lung cancer.(2, 7-11) According to the current World Health Organization (WHO) classification 4 histological types are distinguished. Typical carcinoids (TC) are well differentiated tumors, that account for 1.8% of pulmonary malignancies.(12) In contrast, atypical carcinoids (AC) are moderately differentiated lung tumors comprising 0.2% of all lung cancers.(13, 14) Carcinoids usually appear between the 4th and 6th decade of life, with a median age of 45 years. However, these tumors represent the most common primary lung neoplasms in children and adolescents.(15) Other histological types of LNENs (as per WHO definition) include large cell neuroendocrine lung cancer (LCNEC) and small cell lung cancer (SCLC). LCNEC account for 3% of lung cancers and represent poorly differentiated, high-grade tumors with complex biological features that share many similarities to SCLC.(16) SCLC is a heterogeneous malignancy characterized mainly by genetic instability, early metastasis and high proliferative activity. These tumors are frequently detected at an advanced stage, after several metastases have developed, making surgical treatment rarely feasible.(17, 18)

Smoking is the main risk factor for LCNECs and SCLCs. Almost all of SCLC patients are heavy smokers; the number of never-smoker patients is estimated to be only around 2%.(18) In contrast, our knowledge about risk factors in case of carcinoids is scarce as – unlike high-grade neuroendocrine tumors (NETs) – an unambiguous association with smoking or tobacco-related genetic alteration has not yet been proven. Interestingly, there is a higher incidence reported in never-smokers compared to smokers from several

sources. Based on literature findings the vast majority of carcinoids are sporadic malignancies.(19-22)

According to our current knowledge, carcinoid tumors and more commonly typical carcinoids might be preceded by the hyperplasia of pulmonary neuroendocrine cells (PNECH) in distal airways.(23-26) The most widely accepted theory is that neuroendocrine cell hyperplasia and diffuse form of PNECH (DIPNECH) are a reactive lesion, that develops in response to certain environmental noxious stimuli or stressors. These causes can be underlying lung diseases, chronic inflammation, and toxic lung injuries.(27) In contrast, no obvious precancerous lesion has been identified in either LCNEC or SCLC to date. Although it should be emphasized that the rapid growth of these tumors makes their identification extremely difficult.(10, 18, 28, 29)

1.2. Diagnosis

Main clinical manifestations of LNENs include cough, hemoptysis, dyspnea, chest pain and weight loss; yet it should be highlighted that these symptoms are not specific for LNENs and are the same as in other types of lung cancer.(30) Regarding their localization, 85% of TCs and the majority of SCLCs are centrally located. These centrally located lesions are usually associated with obstructive symptoms related to the tumor mass, such as coughing, wheezing, hemoptysis, dyspnea, chest pain and recurrent lung infections. The appearance of ACs and LCNECs are much more common (80-90%) in the periphery. Peripheral tumors are often asymptomatic and are mainly detected incidentally. (11, 18, 31-34) Paraneoplastic syndromes (PNS) may have of diagnostic value in these diseases, since none of the symptoms listed above are specific for LNEN. These syndromes are often associated with neuroendocrine tumors and may occur in a significant proportion of patients.(35) Endocrine PNS are caused by the ectopic production of biologically active peptides (like serotonin, histamine, tachykinins, kallikrein, and prostaglandins) by the tumor cells, causing different symptoms, such as the syndrome of inappropriate antidiuretic-hormone (SIADH) and ectopic Cushing's syndrome (ECS). Also, neurological syndromes can be present by antibodies against neuronal proteins, for example Lambert-Eaton myasthenic syndrome (LEMS), which is the most commonly diagnosed PNS, especially in patients with SCLC. (36-39)

In terms of their degree of differentiation and metastatic potential, carcinoids are at the less aggressive end of the LNEN spectrum. These tumors are typically well differentiated and slow growing lesions. The metastatic rate (including lymph node metastases) for TCs is around 5-20%, while for ACs it can reach up to 50%. It is typical that metastasis is discovered up to decades after the primary tumor has appeared. Although metastases in ACs occur in half of cases, due to their slow growth, the vast majority of carcinoids can be treated very well surgically.(28, 34, 40) The highly aggressive LCNEC and SCLC are localized on the other side of the scale, and they are characterized by aggressive, rapid growth and a high propensity to metastasize (reaching up to 80% in case of SCLC). In LNENs the most common sites of metastasis are liver, brain, bone and adrenal gland.(18, 34)

After evaluating the various signs and symptoms, it is the wide range of radiological imaging techniques that really contribute to the primary diagnosis. Around 40% of LNENs are diagnosed accidentally during routine chest X-rays.(39) Radiological findings in LNENs are typically similar to those in other types of lung cancer. Nevertheless, it is important to emphasize that in SCLC and LCNEC, these tumors are often in an advanced stage with distant metastases at the time of diagnosis.(18, 41, 42) An important diagnostic method is bronchoscopy, especially for centrally located tumors. Meanwhile, the main sampling option peripherally located lesions is CT-guided transthoracic biopsy.(39)

Subsequently, the final diagnosis relies on the characteristic classic light microscopic features of the tumor. Under the microscope, TC and AC cells are usually uniform, with smooth nuclear membranes, moderate eosinophilic cytoplasm, finely granular cytoplasm and “salt and pepper” nuclear chromatin. Cells vary in size from small to intermediate, in shape they are typically cuboidal, sometimes polygonal, or even fusiform. Tumor cells can show palisading, trabecular, spindle cell, rosette-like, papillary, glandular sclerosing, and even follicular patterns. The key difference between TC and AC is practically the number of mitoses and the presence of necrosis. In TCs, there is no necrosis and the number of mitoses does not exceed 2 per 2 mm². Meanwhile, ACs have punctate necrotic areas and the mitotic rate is between 2 and 10 per 2 mm². LCNECs typically exhibit neuroendocrine morphology, have large cell size, polygonal, moderate to abundant cytoplasm, coarse to vesicular nuclear chromatin and frequent nucleoli. SCLCs consists of small tumor cells that are round to spindle shaped, with small amount of cytoplasm,

fine-grained chromatin, and unremarkable or absent nuclei. These tumors used to be called oat cell carcinoma. Crush artifacts are fairly common, especially in small biopsy samples. Necrosis is as well common and often extensive. The mitotic count is typically very high, averaging 80 mitoses per 2 mm² or more. In terms of immunohistochemistry (IHC) all 4 tumor types typically show positivity for neuroendocrine markers (CD56, chromogranin A and synaptophysin) and TTF-1.(8, 28)

1.3. Current clinical management

Given the well-differentiated morphology and low metastatic potential of TCs, the 5-year overall survival (OS) rate can reach 95%. Therefore, this tumor type is the one that we focus on the least in our research. ACs, which are much more likely to metastasize, have a 5-year OS of around 50%. TCs and ACs, on the other hand, are a particularly aggressive tumor types with a high malignancy potential. About 40% of LCNEC patients and a much higher proportion of SCLC patients usually have multiple organ metastases at the time of diagnosis. For patients diagnosed with LCNEC, the 5-year OS is around 20%, while for SCLC patients, this value does not exceed 7%. Despite the appalling survival records, the treatment of these malignancies has changed minimally in the last 30 years, partly due to their rarity and biological complexity.(18, 28, 43)

First of all, the treatment procedures for typical and atypical carcinoids are broadly the same. These types of tumors can be treated very well surgically. Accordingly, if there are no distant metastases, surgical removal of the primary tumor is the last resort in the vast majority of cases. This may be a wedge resection, but in advanced cases, segmentectomy, lobectomy or even pneumonectomy may be considered.(44, 45) Radiotherapy is mainly used to relieve the pain of bone metastases and to treat brain metastases; however rarely it is also offered as a complementary treatment option after incomplete surgical resection or as palliative treatment for inoperable cases. In patients with metastatic carcinoid, several chemotherapy regimens have shown limited response rates. These patients are usually treated based on the classic SCLC treatment guidelines, specifically, with the combination of cisplatin or carboplatin and etoposide or temozolomide alone. Further potential therapeutic agents are the somatostatin analogues including octreotide and lanreotide, which have previously shown antitumor activity in gastrointestinal and pancreatic neuroendocrine tumors. Later it was found that these therapeutic agents slow

tumor progression and control the symptoms of carcinoid syndrome mainly in typical carcinoids.(46, 47) The current National Comprehensive Cancer Network (NCCN) guideline does not recommend the use of immunotherapeutic agents even in advanced stages. Although immunotherapy has shown very promising results in many tumor types, its applicability in carcinoids was so far investigated only in a few studies of very limited number and value. (40, 48, 49)

Regrettably, the situation is significantly more ambiguous in case of LCNEC. As these tumors are rare and only few randomized trials have been conducted so far, treatment guidelines are still highly controversial. According to the current NCCN guidelines, LCNECs can be treated either according to non-small cell lung cancer (NSCLC) treatment protocols (i.e. cisplatin or carboplatin), or according to SCLC therapeutic guidelines given that both LCNEC and SCLC are high-grade neuroendocrine tumors with a similar clinical course.(50) For early-stage LCNEC, surgical resection is usually recommended.(51) Another controversial issue is radiotherapy and prophylactic cranial irradiation (PCI) in early stage. Despite the worse prognosis, the available evidence supports the use of radiotherapy according to NSCLC guidelines. Meanwhile the low incidence of spontaneous brain metastases (about 25%) does not justify routine PCI as in SCLC.(52) In contrast, SCLC regimens are more frequently used in advanced stage LCNEC, based on limited retrospective analyses and the 2015 American Society of Clinical Oncology (ASCO) recommendations.(53-57) For LCNEC, there is no clear NCCN guideline to date, so the immunotherapeutic approaches for this disease are still rather chaotic, with only a few clinical studies on their applicability.

SCLC is a highly aggressive disease, with nearly two-thirds of patients showing metastatic spread outside the chest at diagnosis.(41, 58) Consequently, surgery is rarely performed, with about 80%-85% of patients receiving systemic therapy.(59) In rare, early-stage cases, lobectomy with extended lymph node dissection is preferred, often followed by adjuvant chemotherapy (CHT), radiation therapy (RT), and/or brain radiation to eliminate potential micrometastases or residual tumor cells.(60, 61) Although no prospective randomized trials confirm surgery's efficacy in SCLC, observational studies suggest that patients with more advanced stages might also benefit from curative-intent surgery.(62) However, these findings are debatable, and choosing between surgical and non-surgical approaches remains challenging for clinicians. Systemic therapy primarily

involves platinum-based CHT (cisplatin or carboplatin) combined with etoposide and/or RT. Unlike NSCLC, which is often resistant to CHT, SCLC initially responds well to DNA-damaging agents, with a response rate nearly double that of NSCLC.(63, 64) However, resistance development is almost always inevitable, and response rates to second-line therapy is significantly lower due to cross-resistance. Given that immune infiltration is often high in SCLC tumors, it is a legitimate assumption to treat patients with immunotherapeutic drugs. Conversely, although the addition of anti-PD-L1 monoclonal antibodies to the standard platinum-etoposide baseline improved both progression-free (PFS) and OS, the response rates remained below that expected.(65-67)

1.4. Immunotherapy and immune checkpoint inhibitors

The integration of immunotherapy into clinical practice in recent years has significantly improved survival outcomes for patients with NSCLC.(68) However, progress in the clinical management of LNENs lags far behind that seen in NSCLC.(58, 69) Recently, there has been increasing interest in utilizing immunotherapeutic agents for advanced or metastatic lung carcinoids, with ongoing clinical trials exploring the efficacy of immune checkpoint blockade in these subtypes.(70) For other LNENs, although adding immune checkpoint inhibitors to standard platinum-based systemic therapy has improved survival outcomes for subsets of SCLC and LCNEC patients, the response rates have been lower than expected.(66, 71, 72) The reasons for these disappointing results are debated, but the tumor immune microenvironment (TIM) may play a crucial role in the effectiveness of immune checkpoint inhibitors.(73) Previous efforts to characterize the TIM have highlighted its role in cancer development and progression.(66) Moreover, a high density of tumor-infiltrating lymphocytes is directly associated with the benefits of immunotherapy in NSCLC patients and serves as a predictor of clinical outcomes.(73, 74) The situation is much worse for LNENs, where there are very few clinical trials and most of the time they are grouped with other rare solid tumors. Accordingly, our knowledge of the impact of immunotherapy in LNENs is still very limited.

In addition to the well-known immune checkpoint molecules like programmed cell death protein 1 (PD-1), programmed cell death-ligand 1 (PD-L1), and cytotoxic T lymphocyte-associated protein 4 (CTLA-4), other molecules involved in antitumor immunity are worth investigating.(66, 75-77) One of the four investigated molecule in our study is V-

domain Ig suppressor of T cell activation (VISTA), a transmembrane protein that inhibits T cell effector function. VISTA is typically highly expressed in tumor-infiltrating lymphocytes, resulting in a reduced anti-tumoral immune response. High VISTA expression has been observed in various cancers, including melanoma, NSCLC, and pleural mesothelioma.(78-80) OX40L (CD252), the ligand for the OX40 (CD134) receptor, is generally expressed by antigen-presenting cells such as dendritic cells or macrophages and activated CD4 and CD8 positive T cells. Notably, studies have shown that agonists of OX40 and OX40L can enhance antitumoral immunity.(81, 82) The glucocorticoid-induced TNF receptor (GITR) is another transmembrane protein crucial for regulating effector T cells, and its activation can promote an antitumoral immune response.(83, 84)TRX-518, a GITR agonist, is already investigated in phase 1 trials with promising results in solid tumors.(85) The last molecule investigated by our team, is the T-cell immunoglobulin and mucin domain 3 (TIM3). It is an immunoregulatory protein found on T lymphocytes, myeloid cells, and several tumor cells including those in melanoma, breast, and kidney cancer. Since TIM3 suppresses antitumoral immunity and promotes tumor development, blocking the TIM3 pathway could be a promising therapeutic strategy.(86, 87) The four markers mentioned above have been used in preclinical models, but their presence and expression patterns have not yet been investigated in LNEN patients.

2. Objectives

Intermediate- and high-grade neuroendocrine lung neoplasms, especially LCNEC and SCLC are aggressive tumors, with high metastatic potential and poor prognosis.(7, 8, 10) Due to the fact that they are relatively rare entities with complex biology, our knowledge is still very limited. Accordingly, the therapeutic arsenal has not changed significantly over the last 30 years.(13, 18) Although targeted therapies, and immunotherapy in particular, have gained ground in recent years for several malignancies, this remarkable progress has been somewhat lagging behind in the case of pulmonary neuroendocrine neoplasms.(59, 88-90) Since AC is less sensitive to currently used chemotherapeutic agents, while LCNEC and SCLC are sensitive but become resistant relatively quickly, implementing targeted- and immunotherapeutic approaches for these tumors would be crucial.(13, 14, 16, 18, 91) Therefore, investigating the immunological phenotypes and specific immune signatures, as well as the tumor immune microenvironment of surgically resected LNENs might be the first step to develop effective therapeutic approaches for these devastating diseases as soon as possible. As a result, it is expected that the efficacy of currently available immune checkpoint inhibitors (ICIs) will be improved and the use of these agents can be optimized based on TIM. In addition, our results would also contribute to the development of second-generation ICIs in the future.

We also investigated whether the immune marker expression signature of different tumors can be used to classify a tumor into its appropriate histological category. This has a particularly important relevance in case of small biopsy specimens, as sometimes there are serious diagnostic pitfalls in establishing the accurate diagnosis by using these small tissue samples. Finally, in order to also provide insights into the applicability of immunotherapy, we also aimed to examine the expression levels and distribution patterns of 4 novel immunotherapeutic markers (OX40L, VISTA, TIM3, GITR) of potential therapeutic relevance in SCLC, AC, and LCNEC patients.

These studies were conducted in accordance with the guidelines of the Helsinki Declaration of the World Medical Association and with the approval of the national-level Ethics Committee of each participating country (Hungarian Scientific and Research Ethics Committee of the Medical Research Council, ETT TUKEB 39249-2/2019/EKU and 52614-4/2013/EKU).

3. Methods

3.1 Study population and treatment

In our multicenter retrospective study, we have included 156 Caucasian patients with histologically confirmed LNENs who underwent surgical resection at one of the four below mentioned Central European centers between 1997 and 2021. The four centers were the National Korányi Institute of Pulmonology (Budapest, Hungary), the National Institute of Oncology (Budapest, Hungary), Medical University of Graz (Graz, Austria) and Palacky University Olomouc (Olomouc, Czech Republic). Of these, 26, 64, and 66 patients were diagnosed with AC, LCNEC and SCLC, respectively. Concerning the enrollment period, SCLC samples originated between 1997-2020, whereas LCNEC and AC formalin-fixed paraffin-embedded (FFPE) blocks were all created in 2016-2021 and 2008-2019, respectively. Clinicopathological data, including the age at the time of diagnosis, gender, comorbidities, and smoking history were retrospectively collected from the medical records of each center. Survival outcomes were provided by the National Health Insurance Office and Central Statistical Office. Only individuals with appropriate clinicopathological data and a sufficient amount of FFPE tumor tissue were included. Another important inclusion criterion was that only whole-tissue specimens were included to avoid bias due to intratumoral heterogeneity. Although not directly related to this study, as the boundary between TCs and ACs is sometimes very blurred, IHC staining was also performed in 10 TC cases, to compare them to ACs.

All patients underwent lung resection surgery (lobectomy or wedge resection surgery), and platinum-based adjuvant CHT was applied when necessary. Systemic therapy was administered in accordance with the contemporary NCCN guidelines.

3.2 Immunohistochemistry

All tumor tissue samples were obtained by surgical resection. First, each sample was examined as part of the routine pathological check-up to define the histopathological diagnosis for further therapy. This was performed by a board-certified pathologist of the host institute according to contemporary diagnostic guidelines, using specific IHC stains such as chromogranin A, synaptophysin, CD56, syntaxin, and Ki-67. Of note, a small proportion (4.9%) of our surgically resected tissue samples were older than 15 years. However, the majority of antigens are well preserved over time, sometimes decreased

nuclear immunosignal intensity might occur in case of older FFPE blocks. (92, 93) As for the antibodies used for quality check of the older (>15 years) samples, we found strong positivity with CD56 and moderate positivity (associated with reduction of immunosignal intensity) with Ki-67 (Figure 1).(94, 95) Notably, expression patterns of TIM3, VISTA, GITR, and OX40L did not differ statistically significantly between the older (>15 years) and newer (\leq 15 years) blocks. In addition, in order to ensure the correctness of the initial diagnosis and to exclude cases with mixed histology (i.e., combined SCLC-LCNEC/NSCLC), all hematoxylin and eosin (H&E)-stained slides were also reviewed by an independent pathologist prior to inclusion. In the next step, tissue sections were analyzed for the expression of the following 19 immunological markers: PD-L1, PD-1, CD3, CD4, CD8, CD27, CD47, indolamine 2,3-dioxygenase (IDO), inducible T-cell costimulator (ICOS), CD70, CD137, CD40, CD94/NK Group 2 Member A (NKG2A), lymphocyte-activation gene 3 (LAG3), OX40, OX40L, V-domain Ig suppressor of T cell activation (VISTA), glucocorticoid-induced TNF receptor (GITR) and T cell immunoglobulin and mucin domain 3 (TIM3). The expression patterns of the first 15 markers (PD-L1, PD-1, CD3, CD4, CD8, CD27, CD47, Indolamine 2,3-dioxygenase (IDO), inducible T-cell costimulator (ICOS), CD70, CD137, CD40, CD94/NK Group 2 Member A (NKG2A), LAG3, and OX40) were examined in 26 AC, 30 LCNEC, and 29 SCLC. In our second cohort, the expression patterns of OX40L, GITR, TIM3, and VISTA were examined in 26 AC 49 LCNEC and 66 SCLC. Unfortunately, due to low tissue sample size, in case of 21 SCLCs, only VISTA staining was performed. Totally, 75 cases were overlapping between the two cohorts. The specific antibodies directed against these markers are summarized in Table 1. IHC staining was performed according to the recommended staining protocols. Briefly, after deparaffinization and rehydration, sections were incubated in a 3% H₂O₂ solution for 20 min, in order to reduce nonspecific background staining. Next, tissue samples were heated to 98.0 °C in a 10 mM Citrate buffer (pH = 6.0) or 10 mM Tris-EDTA buffer (pH = 9.0) for 20 min based on the manufacturers' recommendation. Slides were incubated at room temperature with Ultra V Block (Ultravision LP detection system, Lab Vision Corporation, Thermo Fisher Scientific Inc., Pittsburgh, MA, USA) for 5 min, followed by primary antibody incubation overnight at 4 °C. Immunoreaction was detected by the UltraVision LP detection system (Lab Vision Corporation). Primary antibodies were visualized by 3-3'-diaminobenzidine (DAB) and

counterstained with hematoxylin. Of note, the staining protocol was validated by appropriate positive tissue controls. Expression of the given marker was examined blinded to clinical data by two experienced independent lung pathologists. All slides were digitally scanned using PANNORAMIC 250 Flash III (3DHISTECH Ltd., Budapest, Hungary); sections were examined and evaluated by using CaseViewer 2.4 (3DHISTECH Ltd., Budapest, Hungary). Therefore, during pathological evaluation, we determined the percentage of positive tumor cells in at least 20 randomly selected areas at 20x and 40x magnifications. Two experienced pulmonary pathologists performed the evaluation process, and if a discrepancy of more than 20% occurred in their results, a third pulmonary pathologist was also involved.

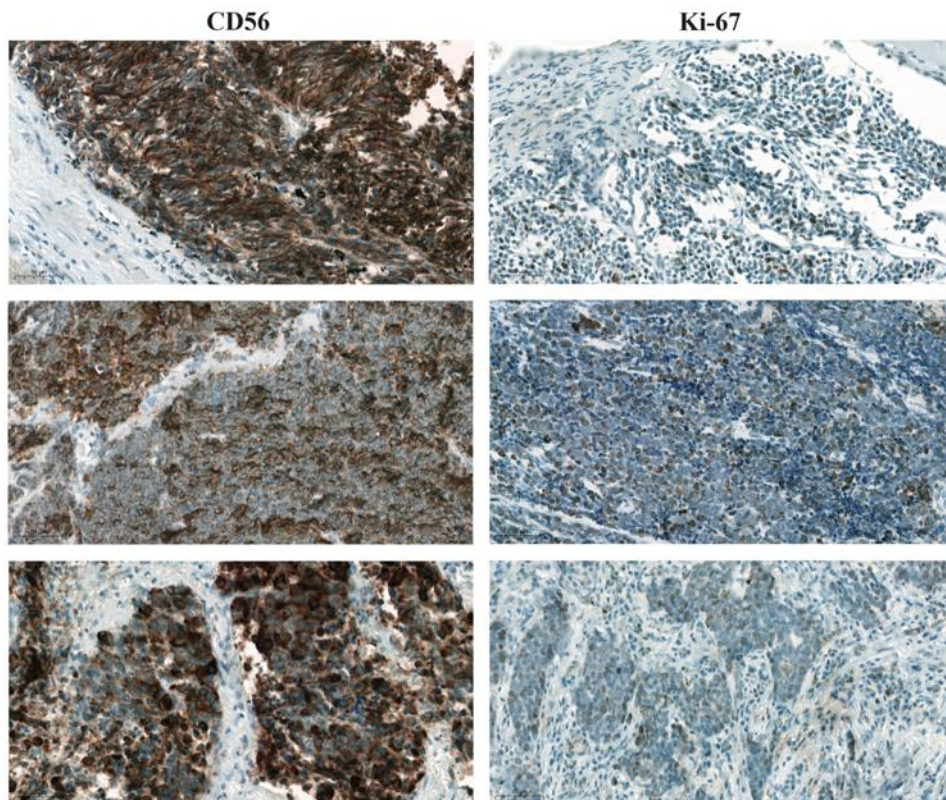


Figure 1. Representative images of the three oldest FFPE samples stained with CD56 and Ki-67. Images were captured with a 40x objective lens. The positive cells were visualized with 3-3'-diaminobenzidine (DAB), and the nuclei were labeled with hematoxylin.

Tumor cells were evaluated separately from immune cells. In the case of tumor cells, the ratio of positive cells to all tumor cells was also quantified. Similarly, the ratio of immune cells showing positive staining and the ratio of total immune infiltrates in a given sample was determined. It should be emphasized that manual analysis of each marker was preferred in this study since software-based evaluation still bears many limitations, even for antibodies used in routine diagnostics. Additionally, the training of AI-based algorithms requires a large number of „teaching” sets which were not available in our study.

Table 1. Antibodies used for immunohistochemistry (IHC).

Antibody	Company	Catalog nr.	Host	Dilution	Antigen retrieval
PD-1	Abcam, Cambridge, U.K.	ab52587 (NAT105)	Mouse	1:50	Citrate (pH=6.0)
PD-L1	Abcam, Cambridge, U.K.	ab205921 (28-8)	Rabbit	1:500	Citrate (pH=6.0)
CD3	Leica Biosystems, Chicago, IL, USA	PA0553 (LN10)	Mouse	Ready to use	Tris-EDTA (pH=9.0)
CD4	Roche, Basel, Switzerland	790-4426 (SP35)	Rabbit	Ready to use	AUTOMATED IHC
CD8	Dako – Agilent, Santa Clara, CA, USA	M7103 (C8/144B)	Mouse	1:100	Tris-EDTA (pH=9.0)
CD27	Abcam, Cambridge, U.K.	ab131254 (EPR8569)	Rabbit	1:500	Tris-EDTA (pH=9.0)
CD47	Sigma-Aldrich, Burlington, MA, USA	HPA044659	Rabbit	1:100	Tris-EDTA (pH=9.0)
IDO	Thermo-Fisher, Waltham, MA, USA	14-9750-82 (V1NC3IDO)	Mouse	1:500	Citrate (pH=6.0)
ICOS	Abcam, Cambridge, U.K.	ab224644 (EPR20560)	Rabbit	1:500	Tris-EDTA (pH=9.0)

CD70	Thermo-Fisher, Waltham, MA, USA	PA5-32701	Rabbit	1:50	Citrate (pH=6.0)
CD137	Abcam, Cambridge, U.K.	ab232990	Rabbit	1:25	Citrate (pH=6.0)
CD40	Abcam, Cambridge, U.K.	ab13545	Rabbit	1:500	Citrate (pH=6.0)
NKG2A	Thermo-Fisher, Waltham, MA, USA	PA5-72543	Rabbit	1:500	Citrate (pH=6.0)
LAG3	Abcam, Cambridge, U.K.	ab209236 (EPR20261)	Rabbit	1:1000	Tris-EDTA (pH=9.0)
OX40	Thermo-Fisher, Waltham, MA, USA	11-1347-42 (ACT35)	Mouse	1:100	Tris-EDTA (pH=9.0)
OX40L	Thermo Fisher Scientific, Waltham, MA, USA	11-1347- 42/ACT35	Rabbit	1:100	Citrate (pH=6.0)
TIM3	Abcam, Boston, USA	ab185703	Rabbit	1:100	Citrate (pH=6.0)
VISTA	Sino Biological, Beijing, China	13482-T24	Rabbit	1:500	Citrate (pH=6.0)
GITR	Thermo Fisher Scientific, Waltham, MA, USA	PA5-46810	Rabbit	1:100	Citrate (pH=6.0)

3.3 Statistical analyses

All statistical analyses were performed in R version 4.2.1 (R Foundation for Statistical Computing, Vienna, Austria).

Expression levels of immune markers of the tumor cells or and the amount of immune infiltration, dividing the patients into low and high categories for each marker was performed by using the median of the measured values (for the given marker) as a cutoff value. Patients with a measured level not larger than the median were categorized into the “low” group, while patients with a measured level higher than the median were included

in the “high” category. Expression levels of immune-related markers were compared between tumors of different histological types in a pairwise manner with Wilcoxon signed-rank tests and Bonferroni-correction was used to adjust for multiple testing. Whenever at least one of the three pairwise comparisons resulted in a corrected p-value of 0.05 or lower, the association was considered significant.

Hierarchical clustering of samples based on expression levels was performed with the Complex Heatmap R package (version 2.10.0) with the “ward.D2” clustering method using Euclidian-distance measure.(96) The distance matrix was calculated using Manhattan distance measure and the dendrograms were created using the ward:D clusterin method. The heatmap contains the covariates that had a non-zero coefficient value in at least one of the three logistic regression submodels of the fitted multinomial penalized linear regression model. Expression levels (x) were transformed with the log (1+ x) transformation to better differentiate between various color hues.

As an exploratory approach, we additionally built a multinomial penalized linear regression model using the glmnet R package (version 4.1-4) to predict histological type by observing all measured expression levels and the amount of immune infiltration.(97) Penalization was necessary to avoid over-fitting due to the relatively low number of samples and large number of covariates. The dataset was assigned to training and test sets by a random 60-40% split. Missing expression levels and data on immune infiltration were imputed with zeros. The model was trained on the training set and hyperparameter tuning was performed by the default 10-fold cross-validation technique of the cv.glmnet() function with the family = “multinomial” setting. Model performance was measured on both the training and test sets, the latter of which serves as a more reliable indicator of goodness-of-fit.

To investigate which expression levels of OX40L, TIM3, VISTA and GITR are most indicative of LNEN subtype, a principal component analysis (PCA) was performed (with the factoextra R package (version 1.0.7)) to find linear combinations („principal components”) of the measured variables (expression levels) that most effectively explain the variance in the data.

4. Results

4.1. Patient and sample characteristics

Clinicopathological features of included patients according to LNEN histological subtypes are summarized in Table 2. Most SCLC and LCNEC patients were smokers, whereas the majority of individuals diagnosed with AC were never-smokers. SCLC tumors tended to be centrally located contrasting the peripheral localization of LCNEC. Due to the availability of bronchoscopic findings in the majority of cases, the localization of the primary tumor was determined on the basis of bronchoscopical visualization.(98)

Table 2. Clinicopathological characteristics of the study population. COPD, Chronic obstructive pulmonary disease; N/A, not available; AC, atypical carcinoid; LCNEC, large cell neuroendocrine lung cancer; SCLC, small cell lung cancer.

Total number of patients		Total	AC	LCNEC	SCLC
		156	26	64	66
Gender	N/A	10 (6.41%)	0 (0%)	7 (10.94%)	3 (4.55%)
	Male	75 (48.08%)	11 (42.31%)	32 (50%)	32 (48.48%)
	Female	71 (45.51%)	15 (57.69%)	25 (39.06%)	31 (46.97%)
Age	N/A	11 (7.05%)	0 (0%)	8 (12.50%)	3 (4.55)
	Median (Range)	65 (33-79)	62.5 (33-79)	64 (41-78)	65 (44-78)
Smoking status	N/A	37 (23.71%)	2 (7.69%)	14 (21.88%)	21 (31.82%)
	Never	24 (15.38%)	14 (53.85%)	6 (9.38%)	4 (6.06%)
	Ex	52 (33.33%)	6 (23.08%)	23 (35.94%)	23 (34.85%)

	Current	43 (27.56%)	4 (15.38%)	21 (32.81%)	18 (27.27%)
COPD	N/A	13 (8.33%)	0 (0%)	8 (12.5%)	5 (7.58%)
	No	89 (57.05%)	22 (84.62%)	33 (51.56%)	34 (51.52%)
	Yes	54 (34.62%)	4 (15.38%)	23 (35.94%)	27 (40.91%)
Hypertension	N/A	13 (8.33%)	0 (0%)	8 (12.5%)	5 (7.58%)
	No	59 (37.82%)	10 (38.46%)	19 (29.69%)	30 (45.45%)
	Yes	84 (53.85%)	16 (61.54%)	37 (57.81%)	31 (46.97%)
Diabetes	N/A	13 (8.33%)	0 (0%)	8 (12.5%)	5 (7.58%)
	No	114 (73.08%)	22 (84.62%)	46 (71.88%)	46 (69.7%)
	Yes	29 (18.59%)	4 (15.48%)	10 (15.63%)	15 (22.73%)
Tumor localization (central/peripheral)	N/A	23 (14.74%)	0 (0%)	11 (17.19%)	12 (18.18%)
	Central	53 (33.97%)	13 (50.0%)	7 (10.94%)	33 (50.0%)
	Peripheral	80 (51.28%)	13 (50.0%)	46 (71.88%)	21 (31.82%)
Tumor localization (upper/lower lobe)	N/A	42 (26.92%)	0 (0%)	8 (12.5%)	34 (51.52%)
	Upper lobe	81 (51.92%)	15 (57.69%)	41 (64.06%)	25 (37.88%)
	Lower lobe	33 (21.15%)	11 (42.31%)	15 (23.44%)	7 (10.61%)

Necrosis	N/A	23 (14.74%)	10 (38.46%)	8 (12.5%)	5 (7.58%)
	No	45 (28.85%)	6 (23.08%)	13 (20.31%)	26 (39.39%)
	Yes	88 (56.41%)	10 (38.46%)	43 (67.19%)	35 (53.03%)
Vascular involvement	N/A	17 (10.90%)	1 (3.85%)	8 (12.5%)	8 (12.12%)
	No	84 (53.85%)	15 (57.69%)	35 (54.69%)	34 (51.52%)
	Yes	55 (35.26%)	10 (38.46%)	21 (32.81%)	24 (36.36%)
Peritumoral inflammation	N/A	85 (54.59%)	18 (69.23%)	16 (35.0%)	51 (77.27%)
	0	57 (36.54%)	5 (19.23%)	38 (59.38%)	14 (21.21%)
	1	9 (5.77%)	3 (11.54%)	5 (7.81%)	1 (1.52%)
	2	5 (3.21%)	0 (0.0%)	5 (7.81%)	0 (0.0%)
	3	0 (0.0%)	0 (0.0%)	0 (0.0%)	0 (0.0%)
T	N/A	18 (11.54%)	0 (0%)	11 (17.19%)	7 (10.61%)
	1	87 (55.77%)	13 (50.0%)	28 (43.75%)	46 (69.7%)
	2	27 (17.31%)	7 (26.92%)	13 (20.31%)	7 (10.61%)
	3	13 (8.33%)	2 (7.69%)	9 (14.06%)	2 (3.03%)
	4	11 (7.05%)	4 (15.38%)	3 (4.69%)	4 (6.06%)
N	N/A	46 (29.49%)	0 (0%)	11 (17.19%)	35 (53.03%)

	0	64 (41.03%)	12 (46.15%)	39 (60.94%)	13 (19.70%)
	1	19 (12.18%)	7 (26.92%)	7 (10.94%)	5 (7.58%)
	2	19 (12.18%)	6 (23.08%)	3 (4.69%)	10 (15.15%)
	x	8 (5.13%)	1 (3.85%)	4 (6.25%)	3 (4.55%)
M	N/A	94 (60.26%)	10 (38.46%)	37 (57.81%)	47 (71.21%)
	0	2 (1.28%)	0 (0.0%)	1 (1.56%)	1 (1.52%)
	1	1 (0.64%)	0 (0.0%)	0 (0.0%)	1 (1.52%)
	x	59 (37.82%)	16 (61.54%)	26 (40.63%)	17 (25.76%)

4.2. The expression pattern of the investigated markers by tumor cells

Representative IHC images of immune-related markers according to each LNEN subtype are shown in Figure 2, whereas images of the four novel immunotherapeutic targets are presented in Figure 3. First of all, in order to investigate the key differences of immune-related markers in their IHC expression, we evaluated markers with available expression levels in at least one of the LNEN subtypes for at least one patient. The following eight markers were included in the comparative analysis: PD-1, PD-L1, CD47, IDO, CD70, CD137, CD40, and NKG2A. Except for PD-L1, where expression levels were ubiquitously low and resulted in a similar expression pattern across all histological subgroups (only 5 positive cases were found in the LCNEC cohort, median: 0.0), the expression patterns and of the other markers showed a different distribution in at least one of the three groups (Figure 4A). Specifically, NKG2A and CD40 expressions were significantly higher ($p < 0.05$) in tumor cells of AC samples compared to the LCNEC and SCLC specimens (the median of NKG2A expressions were 0.015, 0.01, and 0.01 in AC,

LCNEC, and SCLC samples, respectively. The median CD40 expressions were 0.275, 0.1, and 0.1 in AC, LCNEC, and SCLC samples, respectively). CD47 expression was the highest in SCLC samples (vs. LCNEC and AC, medians were 0.25 vs. 0.035 vs. 0, respectively). LCNEC tumors expressed both PD-1, CD70, and CD137 at a significantly higher degree than tumors with other histological types ($p < 0.05$). We also evaluated the differences and similarities in case of the four immunotherapeutic markers (Figure 5A), and we found, that OX40L expression of AC tumor cells were significantly lower than in SCLC tumors ($p < 0.001$). Meanwhile, ACs tended to demonstrate significantly higher tumor cell GITR expression levels than SCLC or LCNEC tumors ($p < 0.001$). Of note, tumor cell GITR expression was also considerably higher in SCLC than in LCNEC ($p = 0.011$). As for TIM3, its TC expression was significantly higher in ACs (vs. LCNEC and SCLC tumors; $p = 0.047$ and $p < 0.001$, respectively). No significant differences were observed for VISTA expression.

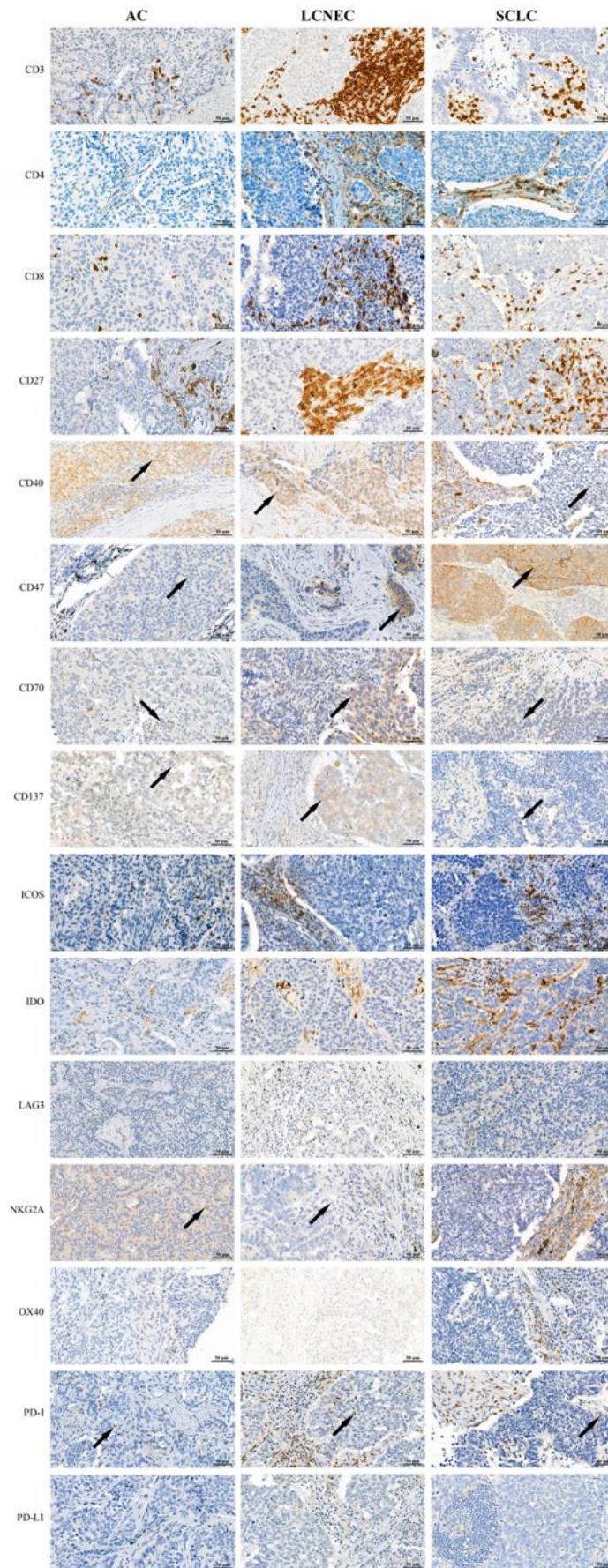


Figure 2. IHC staining of formalin-fixed, paraffin-embedded AC, LCNEC and SCLC samples with immune-related markers. The representative images were captured with a 40x objective lens. The positive cells were visualized with DAB and the nuclei were labeled with hematoxylin. Black arrows point at examples of positive tumor cells. AC, atypical carcinoid; DAB, 3-3'-diaminobenzidine; LCNEC, large cell neuroendocrine carcinoma; SCLC, small cell lung cancer.

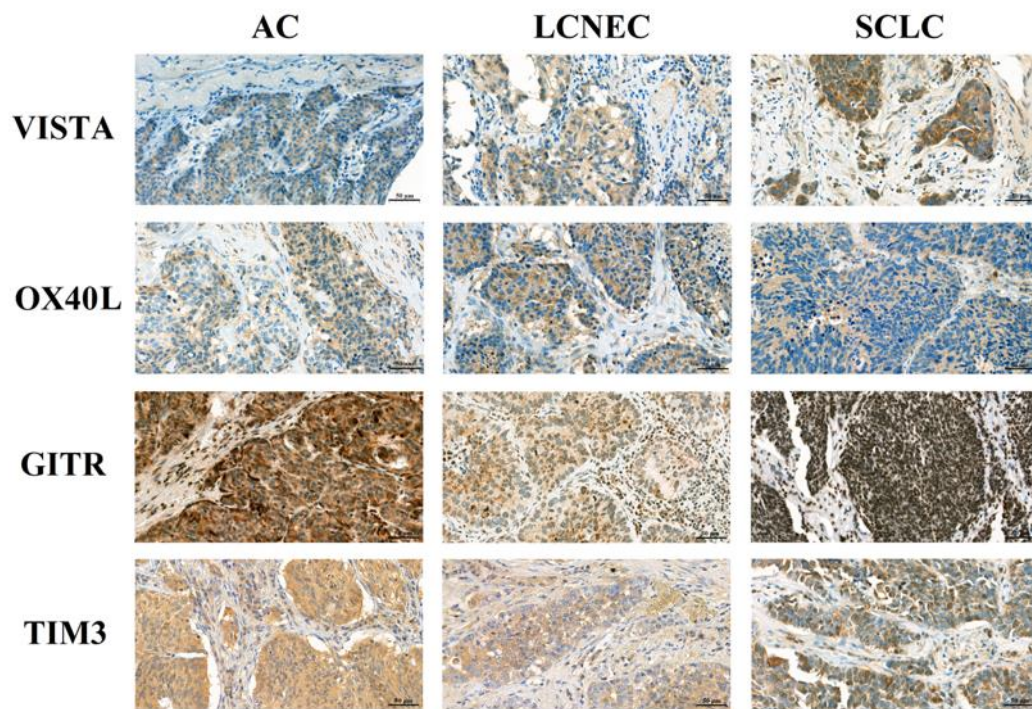
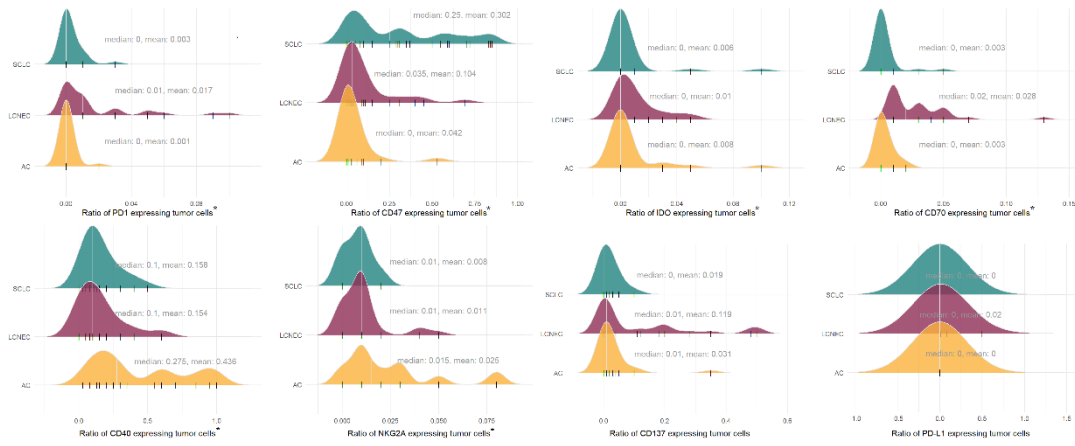


Figure 3. IHC staining of formalin-fixed, paraffin-embedded AC, LCNEC and SCLC samples with the four novel immunotherapeutic markers. Representative images for tumor cells with positive staining were captured with 40x objective lens. Positive cells were visualized with 3-3'-diaminobenzidine (DAB), and the nuclei were labeled with hematoxylin. Scale bar: 50 μ m. AC, atypical carcinoid; LCNEC, large cell neuroendocrine carcinoma; SCLC, small cell lung cancer.

A



B

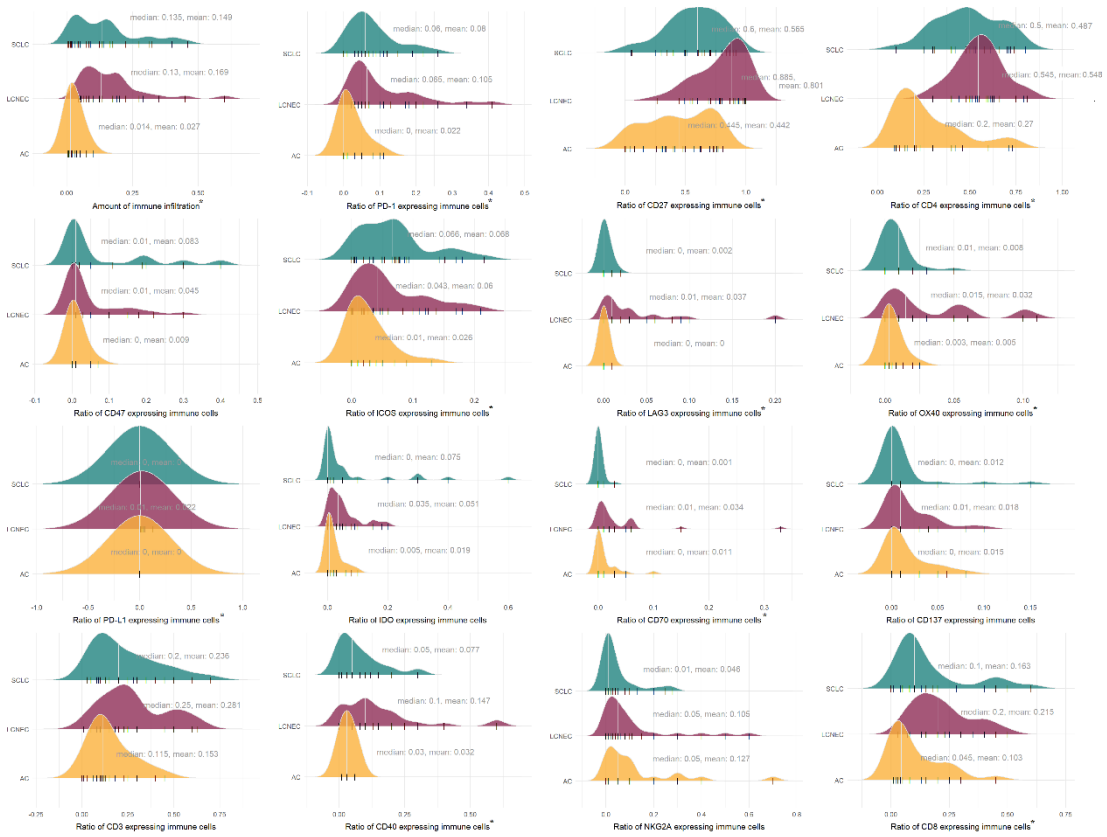

Figure 4. A) Expression levels of preselected immune-related markers by tumor cells in different LLEN subtypes. The color-filled curves show the estimated normalized probability density function of the data. Colors indicate the three LLEN subtypes, whereas the short vertical black lines mark the individual samples. We studied 8 markers among the 15 markers which had available expression levels in at least one of the LLEN subtypes for at least one patient. Green: SCLC, small cell lung cancer; red: LCNEC, large

cell neuroendocrine cancer; yellow: AC, atypical carcinoid. Bonferroni-adjusted significant differences are marked with an asterisk (*). **(B) Expression levels of different immune-related markers by immune cells according to the three LNEN subtypes.** The filled curves show the estimated normalized probability density function of the data. Colors indicate the three LNEN subtypes; the short vertical black lines mark the individual samples. The first graph represents the level of immune infiltration in general. Colors indicate different LNEN subtypes, short vertical black lines mark individual samples. Green: SCLC, small cell lung cancer; red: LCNEC, large cell neuroendocrine carcinoma; yellow: AC, atypical carcinoid. Bonferroni-adjusted significant differences are marked with an asterisk (*).

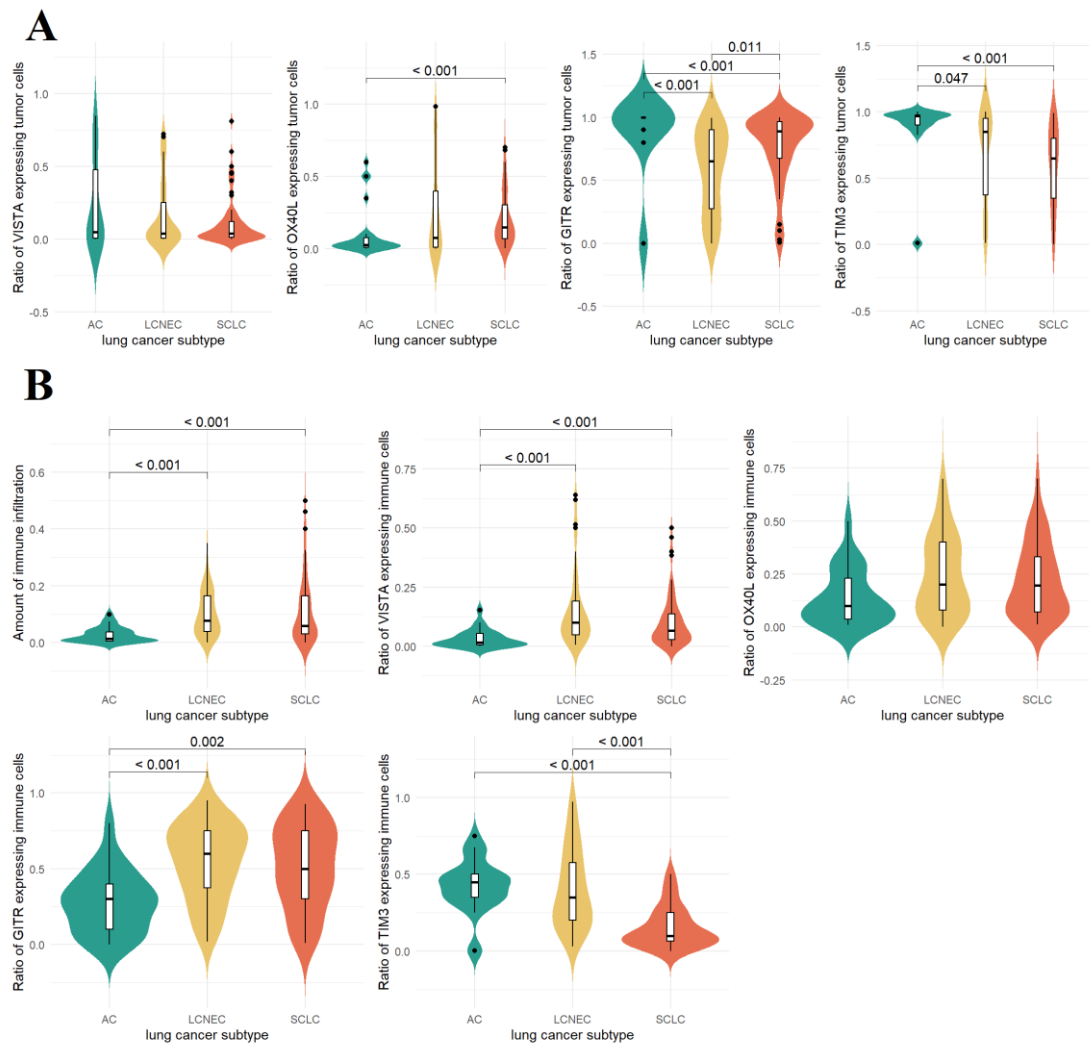


Figure 5. Expression levels of potential immunotherapy targets by tumor cells (A) and immune cells (B) in different LNEN subtypes. The color-filled curves show the estimated normalized probability density function of the data. Overlaid box plots demonstrate the same distributions, box edges represent the first (Q1) and third (Q3) quartiles, with the inner line showing the median value. Whiskers extend to 1.5-times the interquartile range ($IQR = Q3 - Q1$). Samples outside this range (outliers) are marked by black dots. Only significant p-values are shown. Colors indicate the three LNEN subtypes, Green: AC, atypical carcinoid; yellow: LCNEC, large cell neuroendocrine lung cancer; orange: SCLC, small cell lung cancer.

4.3. Unsupervised hierarchical clustering of LNEN according to the expression patterns of immune-related and immunotherapeutic target markers by tumor cells

As shown in Figure 6A, unsupervised hierarchical clustering based on the IHC expression of the immune-related markers of the TIM separated the samples of different histological subgroups fairly well. We found that tumor cell CD40 expression was generally higher in AC tumors (vs. LCNEC and SCLC specimens) whereas high CD47-expressing tumor cells were characteristic for SCLC. CD137 expression by tumor cells was the highest in LCNEC specimens. These results are in line with the above-discussed findings of pairwise comparisons.

We also examined, whether LNEN subtypes can be distinguished solely by their tumor cell VISTA, GITR, OX40L, or TIM3 expression. As shown in Figure 7A, although cluster analysis differentiated three distinct subgroups with divergent immunologic phenotypes, these clusters did not conclude with the histological subtypes.

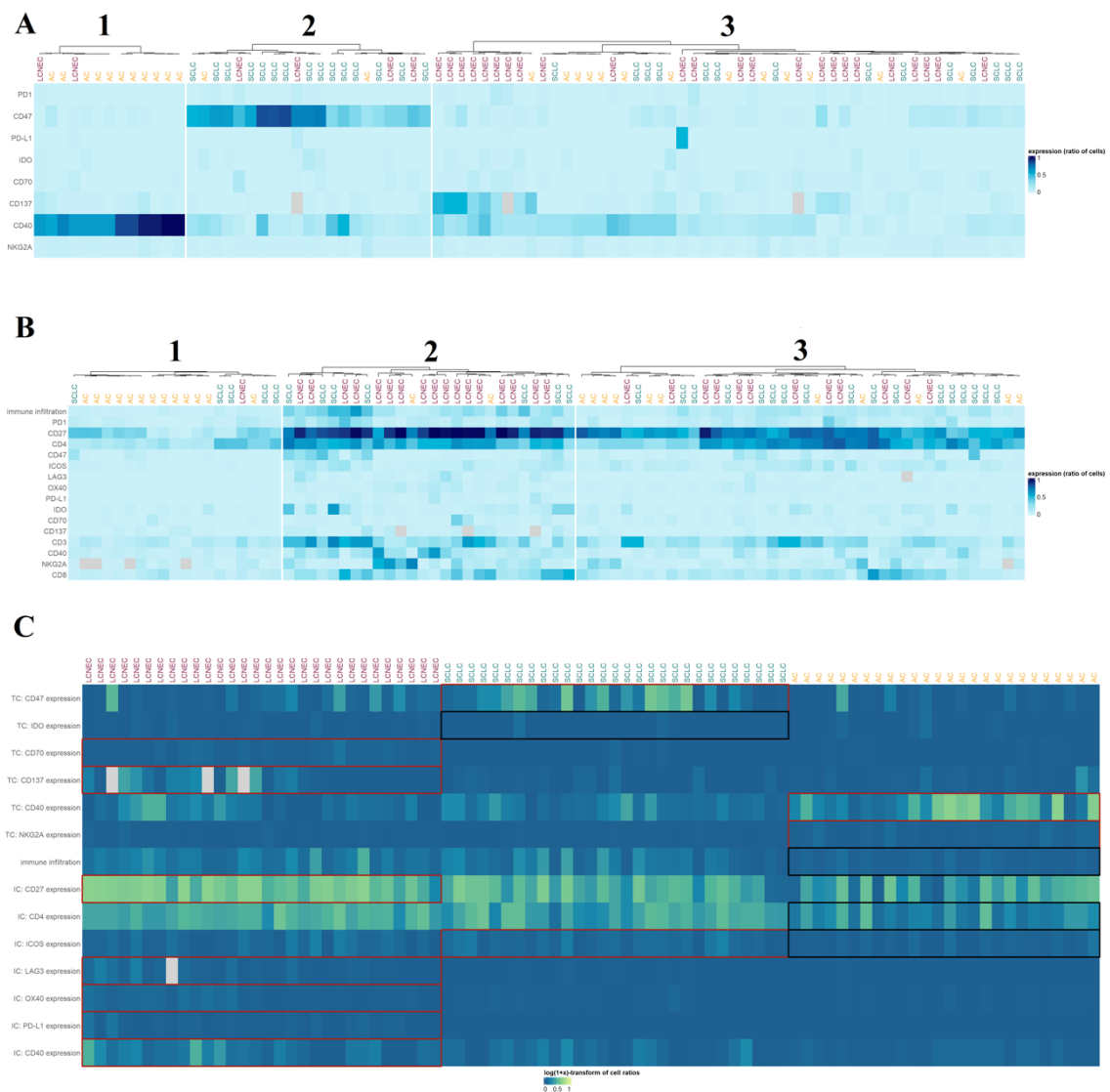


Figure 6. (A) Hierarchical clustering of LNENs based on the tumor cell expression of immune-related markers. The color bar scale indicates the expression levels of the selected markers (PD-1, CD47, PD-L1, IDO, CD70, CD137, CD40, NKG2A). LCNEC, large cell neuroendocrine lung cancer; SCLC, small cell lung cancer; AC, atypical carcinoid. **(B) Hierarchical clustering based on the expression pattern of immune-related markers defined by the immune cells.** The color bar scale indicates the expression levels of the selected markers. LCNEC, large cell neuroendocrine lung cancer; SCLC, small cell lung cancer; AC, atypical carcinoid. **(C) Heatmap of the expression levels of different markers in tumor and immune cells.** The heatmap contains the covariates that had a non-zero coefficient value in at least one of the three logistic regression submodels of the fitted multinomial penalized linear regression model.

Expression levels (x) were transformed with the log (1+ x) transformation to better differentiate between various color hues. Rectangles indicate the variables included in the model (red: positive coefficient, black: negative coefficient). LCNEC, large cell neuroendocrine carcinoma; SCLC, small cell lung cancer; AC, atypical carcinoid.

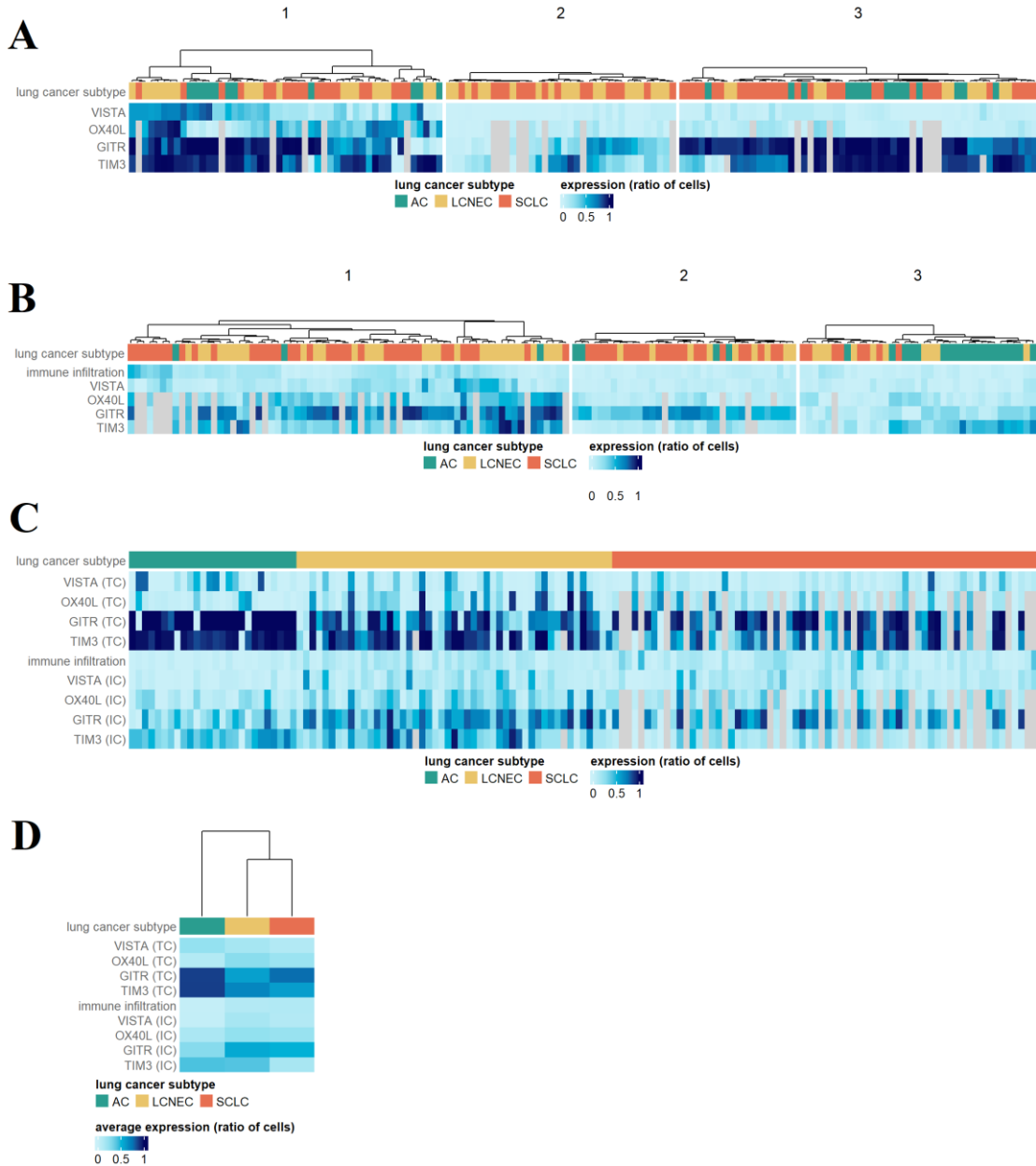


Figure 7. Hierarchical clustering of LLEN subtypes based on tumor cell (A) and immune cell (B) VISTA, OX40L, GITR and TIM3 expression. The color bar scale indicates the expression levels of the selected markers. (C) Heatmap of marker expression levels as defined by both tumor cells and immune cells. (D) Heatmap of

the average tumor cell and immune cell marker expression levels for each subtype. LCNEC, large cell neuroendocrine lung cancer; SCLC, small cell lung cancer; AC, atypical carcinoid.

4.4. The expression pattern of markers defined by immune cells varies across LNEN subtypes

First, in order to obtain a comprehensive overview of the TIM concerning each histological subtype, we compared the levels of immune infiltration (i.e., tumor-infiltrating lymphocytes) across the different subgroups (Figure 4B). The abundance of immune infiltrates was similar in SCLC and LCNEC samples, but notably lower in AC specimens ($p < 0.001$). Likewise, individual expressions of other immune-related markers such as PD-1, ICOS, CD27, CD4, and CD8 were also significantly lower in AC tumors (vs. SCLC and LCNEC specimens). Of note, immune cell expressions of CD27, LAG3, OX40, CD40, and CD8 were highest in LCNEC samples and only these tumors expressed PD-L1.

In case of therapeutic target markers ACs expressed significantly lower levels of immune cell VISTA ($p < 0.001$) and GITR ($p = 0.002$) than LCNEC or SCLC tumors (Figure 5B). Meanwhile, TIM3 expression by immune cells was significantly lower in SCLCs compared to ACs ($p < 0.001$) or LCNECs ($p < 0.001$).

To examine the immunologic landscape within different carcinoid tumor types, we performed immunohistochemical stainings on ten additional typical carcinoid samples. Figure 8 shows the representative images of immune-related markers in the case of typical carcinoid tumors compared to atypical carcinoids. Figure 9A shows the markers' expression levels by tumor cells in typical- vs. atypical carcinoids. Out of the 15 initial markers, we studied eight markers which had available expression levels in at least the typical or atypical carcinoid subtype of at least one patient. Based on the p-values of the Wilcoxon rank sum test after Bonferroni-correction, median expressions were significantly different between typical and atypical carcinoid cases in case of PD-1 ($p = 0.013$), PD-L1 ($p = 0$), IDO ($p = 0.00003$), CD70 ($p = 0.00014$), and NKG2A ($p = 0.00093$). Figure 9B shows the expression levels of the 15 markers by immune cells. We found a significant difference between typical- and atypical carcinoid cases in case of CD4 ($p = 0.00016$) and PD-L1 ($p = 0.00012$) expression levels.

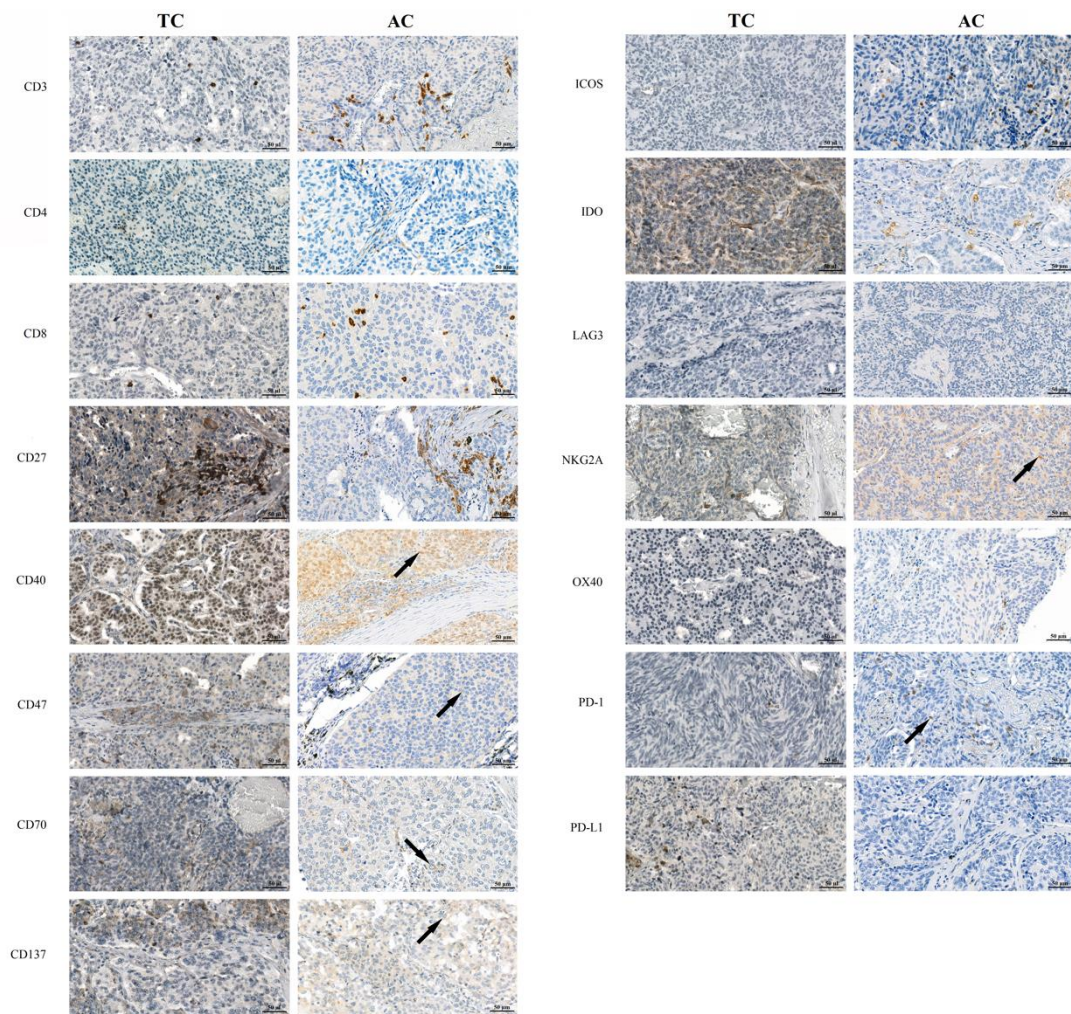


Figure 8. Immunohistochemical stainings of formalin-fixed paraffin-embedded typical carcinoid samples with immune-related markers compared to atypical carcinoids. The representative images show the immunohistochemical stainings of CD3, CD4, CD8, CD27, CD40, CD47, CD70, CD137, ICOS, IDO, LAG3, NKG2A, OX40, PD-1, and PD-L1. Images were captured with a 40x objective lens. The positive cells were visualized with DAB and nuclei were labeled with hematoxylin. Black arrows point at representative positive tumor cells. AC, atypical carcinoid; DAB, 3-3'-diaminobenzidine; TC, typical carcinoid

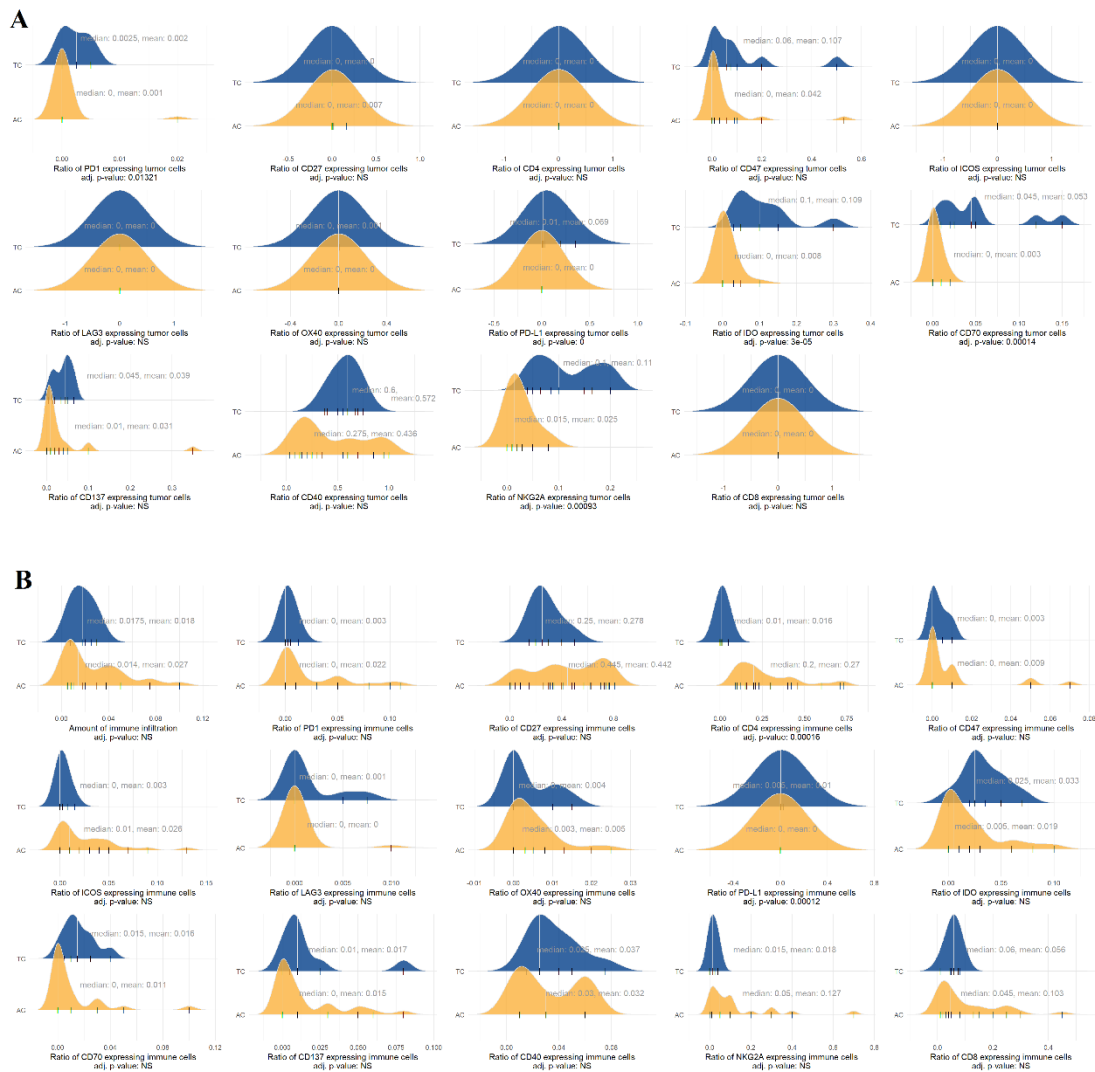


Figure 9. Expression levels of immune-related markers by tumor cells (A) and immune cells (B) in typical and atypical carcinoid samples. The color-filled curves show the estimated normalized probability density function of the data. Colors indicate the typical carcinoid and atypical carcinoid subtypes, whereas the short vertical black lines mark the individual samples. The figures also depict the p-values of Bonferroni-corrected Wilcoxon rank sum test. yellow: AC, atypical carcinoid; NS, not significant; Blue: TC, typical carcinoid

4.5. Unsupervised hierarchical clustering of samples according to the immune cell-based TIM

As shown in Figure 6B, LNEN samples can be separated fairly well based on the immune cell expression of the examined immune-related markers. AC tumors tended to be less

immunogenic than SCLC and LCNEC tumors and the expression levels of CD3, CD8, CD27, and CD4 were also significantly lower in this histological subtype. Differences concerning the immune cell-based expression levels compared to the immune-related marker expression pattern of the tumor cells were less evident between the other two histological subtypes (SCLC and LCNEC). Nevertheless, immune cell expressions of CD27 and CD40 were higher in LCNEC samples (vs. SCLC).

As an additional insight, we aimed to interpret model coefficients. Given that the multinomial model effectively consists of three separate penalized logistic regression submodels, their covariates can be used to differentiate between samples belonging to the given histological type and samples not belonging to that type. To this end, we plotted the expression and immune infiltration patterns of all samples in the dataset ordered by histological type (Figure 6C) and added a black or red border to covariates that had a negative or positive coefficient in the given submodel, respectively. These results imply that greater tumor cell CD70 and CD137 expression and higher immune cell CD27, LAG3, OX40, PD-L1, and CD40 expression were measured in our LCNEC samples compared to the AC and SCLC cohort. The SCLC cohort was characterized by high expression levels of CD47 and low levels of IDO in tumor cell as well as by a generally high expression level of ICOS in immune cells compared to the AC and LCNEC groups. The AC group showed small amounts of immune infiltrates, high expression levels of CD40 and NKG2A by tumor cells and low expression levels of CD4 and ICOS by immune cells compared to LCNEC and SCLC samples.

It has become clear, that based on a cluster analysis was not able to distinguish LNEN subtypes based solely on VISTA, GITR, OX40L, or TIM3 expression by immune cells (Figure 7B).

Finally, a principal component analysis was performed, which revealed, that ACs can be distinguished from both LCNEC and SCLC tumors based on their immune cell and tumor cell marker expression. In this context, ACs express high levels of tumor cell TIM3 and GITR, and low levels of immune cell GITR; both tumor cells and immune cells of SCLCs express high levels of GITR, and their immune cells express low levels of TIM3; and immune cells of LCNECs express high levels of GITR and TIM3. The trends for expression levels of each sample, grouped by their histologic subtype, are shown in Figure

7C. Figure 7D highlights the average expression pattern for each type, underlining previous observations of the most typical features.

4.6. Overall immunological phenotype distinguishes LNEN tumors

Over the course of our two projects, a total of 19 immune markers were investigated. Expression pattern of 15 immune-related markers (PD-1, CD27, CD4, CD47, ICOS, LAG3, OX40, PD-L1, IDO, CD70, CD137, CD3, CD40, NKG2A, CD8) and 4 novel immunotherapeutic targets (OX40L, GITR, TIM3, VISTA) was analyzed in a representative number of AC, LCNEC, and SCLC samples. Since 69 cases of the first patient cohort overlapped with the second cohort, the datasets were merged in order to examine whether the overall marker expression distinguishes LNEN subtypes. Unsupervised clustering revealed unique marker expression patterns in the different histological samples. Importantly, the results demonstrate that the applied immune-related cancer subtype markers are highly effective in classifying tumors into their respective subgroups (Figure 10A). Figure 10B demonstrates the average expression patterns of examined markers with regard to LNEN subtypes.

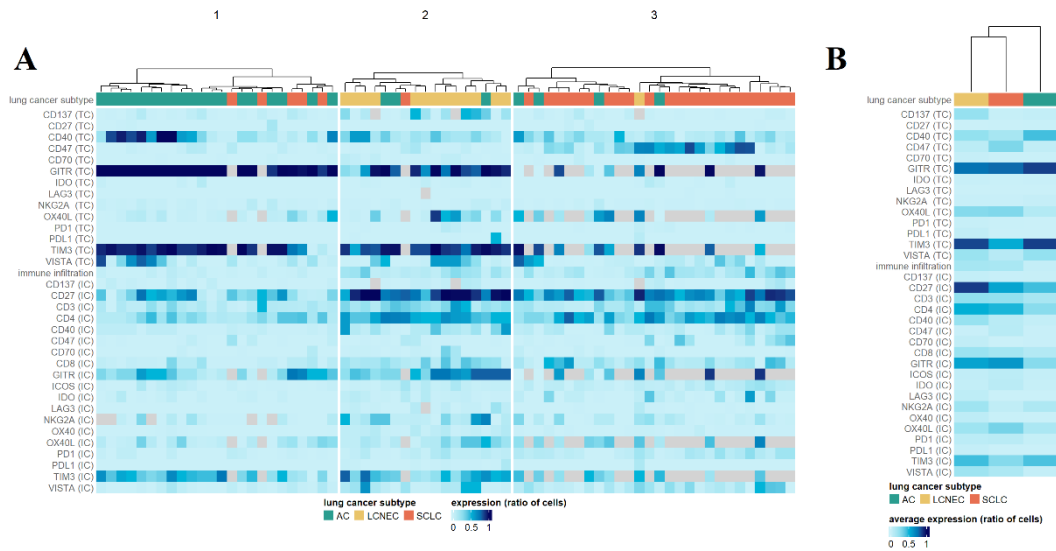


Figure 10. (A) Hierarchical clustering of LNENs based on the TC expression of immune-related markers. The color bar scale indicates the expression levels of CD137, CD27, CD3, CD4, CD40, CD47, CD70, CD8, GITR, ICOS, IDO, LAG3, NKG2A, OX40, OX40L, PD-1, PD-L1, TIM3, VISTA. **(B) Heatmap of the average TC**

expression levels of the selected immune-related markers. LCNEC, large cell neuroendocrine carcinoma; SCLC, small cell lung cancer; AC, atypical carcinoid

4.7. Multinomial penalized linear regression model predicts the LNENs' histological subtype

In order to evaluate whether the histological subtypes could be defined based on the TIM, a multinomial penalized linear regression model was used. The fitted model was able to predict the histological type of the LNEN with an overall accuracy of 90% in the training set and 77% overall accuracy in the test set. See Figure 11 for confusion matrices and additional performance metrics.

As an additional insight, we aimed to interpret model coefficients. Given that the multinomial model effectively consists of three separate penalized logistic regression submodels, their covariates can be used to differentiate between samples belonging to the given histological type and samples not belonging to that type. To this end, we plotted the expression and immune infiltration patterns of all samples in the dataset ordered by histological type (Figure 6C) and added a black or red border to covariates that had a negative or positive coefficient in the given submodel, respectively. These results imply that greater tumor cell CD70 and CD137 expression and higher immune cell CD27, LAG3, OX40, PD-L1, and CD40 expression were measured in our LCNEC samples compared to the AC and SCLC cohort. The SCLC cohort was characterized by high expression levels of CD47 and low levels of IDO in tumor cell as well as by a generally high expression level of ICOS in immune cells compared to the AC and LCNEC groups. The AC group showed small amounts of immune infiltrates, high expression levels of CD40 and NKG2A by tumor cells and low expression levels of CD4 and ICOS by immune cells compared to LCNEC and SCLC samples.

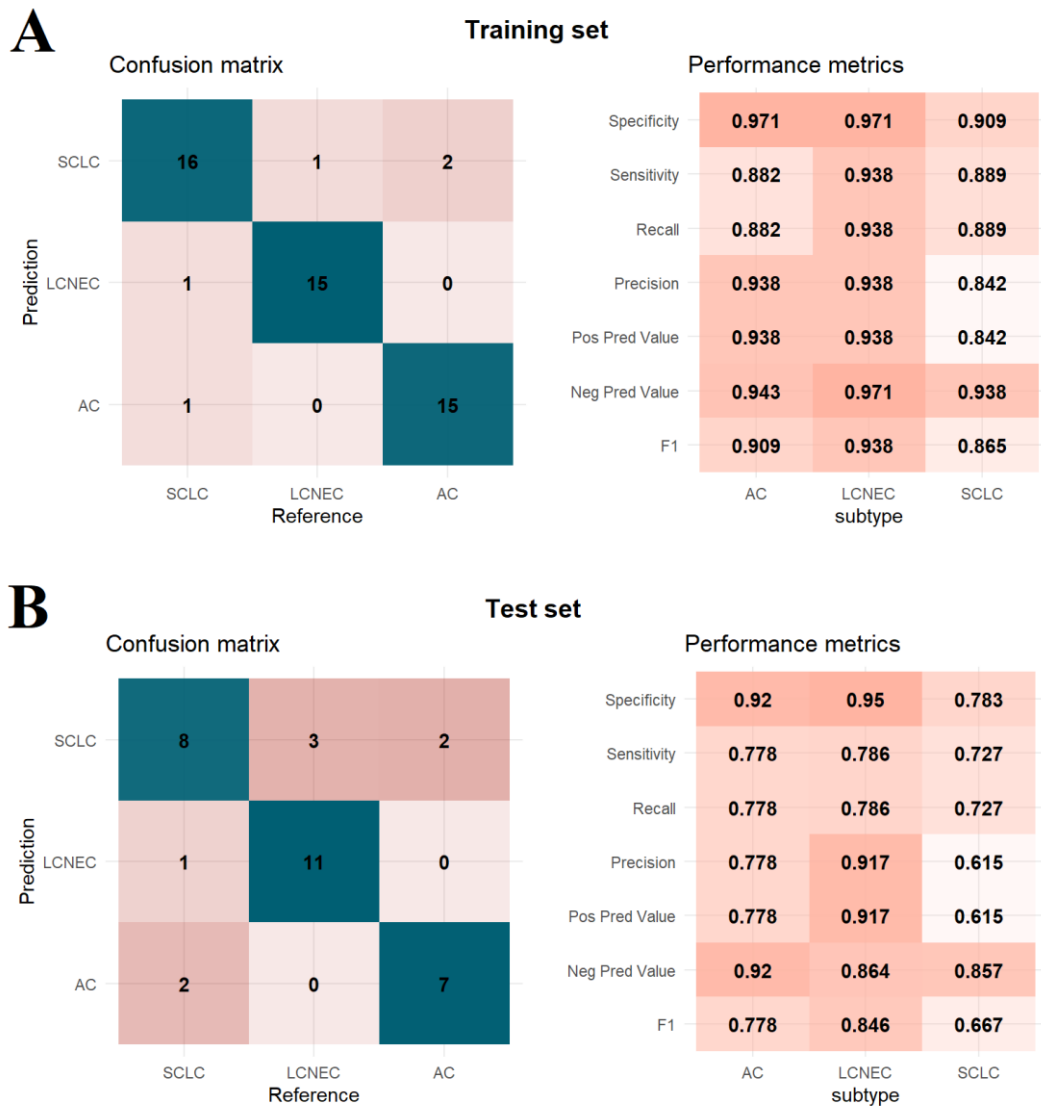


Figure 11. Performance metrics of the multinomial penalized linear regression model on the training (A) and test (B) sets. Confusion matrices show the number of samples having a given histological type (columns) that had been categorized to a specific type by the model (rows). Blue colors indicate correct predictions (diagonal elements), while shades of red show the number of misclassified samples (off-diagonal elements). Various performance metrics are shown for each histological subtype separately. Higher values along with darker shades of red indicate better performance. For all misclassified samples in the test set, the true histological type corresponded with the second-best option based on predicted probabilities and the maximum predicted probability was generally low in these cases, indicating that even though misclassification occurs, it is not done with high confidence. These results, although not exceptionally impressive from a

machine learning viewpoint, indicate that a larger available patient cohort could highly improve model performance and could provide a method for the accurate prediction of histological type based on expression levels, which signifies the presence of a distinctive relationship between histological type and expression levels of tumor samples.

5. Discussion

Over the last 20 years of lung cancer research, it has become clear that understanding the different aspects of TIM is of clinical importance, as immune cells can have a major impact on tumor fate at different stages of the disease.(99-101) A precise understanding and description of these mechanisms is essential to improve the efficacy of targeted therapies and immunotherapy. Immunotherapy represents an effective weapon in the treatment of NSCLC patients(102); however, its exact role and mechanism of action in LNENs is not yet fully understood. Accordingly, in order to gain insight into potential biomarkers and pave the way for future immune checkpoint inhibitor-based strategies, there is an urgent need to study the TIM of these tumors.(101, 103) Accordingly, we investigated the immunological landscape of LNENs by assessing the expression patterns of 15 immune-related markers and 4 novel immunotherapeutic markers in surgically resected AC, LCNEC and SCLC tumors.

In recent years, significant progress has been made in identifying potential predictive and prognostic biomarkers in LNENs, though only a few have been proposed in clinical practice. Among these, the expression of CD44, the presence and degree of spread through air spaces (STAS), the deletion of chromosome 11q (11q22.3-q25), and mutations in the multiple endocrine neoplasia type 1 (MEN1) gene have been reported to negatively impact prognosis in AC tumors.(104-108) Similarly, the Orthopedia Homeobox Protein (OTP) has emerged as a promising marker for pulmonary carcinoids. Both OTP and CD44 have been highlighted as potential prognostic markers; however, their exact impact on OS and the efficacy of immunotherapy remains controversial.(109, 110)

LCNEC has also been subject to recent genomic and transcriptomic analyses, leading to the identification of two distinct subgroups. Type I LCNEC tumors share similarities with the classic variant of SCLC, characterized by alterations in Retinoblastoma 1 (RB1) and Tumor Protein p53 (TP53). Conversely, type II LCNEC resembles NSCLC and is frequently associated with alterations in Serine/threonine Kinase 11 (STK11), Kelch-like ECH Associated Protein 1 (KEAP1), and Kirsten Rat Sarcoma Virus (KRAS). These findings support the theory that LCNEC represents a heterogeneous group or “a mixed basket” of tumors with different origins.(111-113) Furthermore, a high Ki-67 proliferation index has been linked to worse PFS and OS in the majority of LNENs.(114)

SCLC was traditionally considered a homogeneous disease characterized by a single morphological type. The most recent profiling studies have provided a framework to differentiate biologically distinct SCLC subtypes based on the expression of specific transcription factors: Achaete-Scute Homologue 1 (ASCL1), Neurogenic Differentiation Factor 1 (NEUROD1), POU Class 2 Homeobox 3 (POU2F3), and Yes-Associated Protein 1 (YAP1).(18, 58, 90) These biologically specific subgroups exhibit significant differences in their morphological features, growth properties, proteomic alterations, and prognosis. This newfound understanding underscores the heterogeneity within SCLC, challenging the previous notion of its homogeneity.(115-117)

These molecular insights have significant clinical implications, as they reveal the underlying complexity of LNENs and highlight the need for personalized therapeutic strategies. The identification of distinct subgroups within SCLC and LCNEC, based on specific molecular alterations, paves the way for more targeted and effective treatments, ultimately improving patient outcomes. As research continues to evolve, the precise role of these biomarkers in guiding therapeutic decisions and predicting prognosis will become clearer, offering hope for better management of patients with LNENs.

We employed unsupervised hierarchical clustering to effectively categorize samples from different LNEN subtypes based on the expression patterns of immune-related markers. Notably, our study presents the largest immune panel evaluated in these malignancies to date. NKG2A is an immune checkpoint molecule that signals repeated stimulation and cell division, but its expression by tumor cells is highly variable. Specifically, several tumor cells, especially in AC samples, exhibited NKG2A positivity. This finding holds potential clinical relevance as several antibodies targeting NKG2A are currently undergoing clinical trials.(118)

CD47, known for its overexpression in various malignancies such as breast cancer, pancreatic cancer, and NSCLC, plays a role in transmitting anti-phagocytic signals, thereby helping tumor cells evade the immune response.(119-122) High CD47 expression correlates with shortened PFS and OS in advanced-stage NSCLC patients.(123) In line with these observations, we found that CD47 is expressed in a significantly higher amount of SCLC cases.

CD40, another immune-related marker, is expressed in multiple cancers, including melanoma, colon, prostate, breast, and lung cancer. Its expression is associated with

improved survival in lung cancer, and it enhances the anti-tumor immune response in melanoma patients.(124, 125) Our study found that high CD40 expression by tumor cells was detected in ACs.

CD137 is a potent immune-modulating molecule that promotes anti-tumor immunity through interactions with antigen-presenting cells.(126) Based on our results, CD137 expression was not significantly different in the three tumor types. Publicly available datasets, such as GEPIA2 and TIMER 2.0, also support the notion that high CD137 expression is a favorable prognostic factor in melanoma and HER2+ breast cancer.(127, 128)

CD8+ T lymphocytes, known for their cytotoxic activity against malignant cells, have shown varying prognostic significance across different studies. Kawai et al. reported a survival benefit in stage IV NSCLC patients with high CD8+ T-cell presence, whereas other studies have linked high CD8+ levels to unfavorable survival rates.(129-131) In our study, high CD8+ expression by immune cells was detected in SCLC cases and tended to be a negative prognostic factor in LNEN patients, contrasting with findings from Wang et al., who observed improved PFS and OS in LNEN patients with high CD8+ TILs.(132) This discrepancy may be due to demographic differences, as Wang's study focused on Asian individuals, potentially differing significantly from our predominantly Caucasian cohort.

LAG-3, a novel immune checkpoint molecule that suppresses T cell activation and cytokine secretion, shows promise in cancer immunotherapy when targeted alongside other checkpoints.(133) Although its expression in various malignancies like SCLC, hepatocellular carcinoma, gastric cancer, ovarian cancer, and renal cell carcinoma is well-documented, its prognostic value remains controversial.(134, 135) Our study found that in LNEN patients LCNEC immune cells expressed statistically significant levels of LAG3.

Lastly, ICOS, which enhances CD4+ T cell-mediated immunosuppression, represents a promising alternative target in cancer immunotherapy.(136) Indeed, early-phase clinical trials have shown that ICOS agonist monoclonal antibodies exhibit promising antitumor activity, especially when combined with other immune checkpoint inhibitors like anti-PD-1 agents.(136, 137) ICOS expression correlates with improved survival outcomes in skin melanoma, head and neck squamous cell carcinoma, and lung adenocarcinoma.

However, high ICOS expression is associated with poorer prognosis in low-grade glioma and uveal melanoma.(138) In our study, ICOS expression was the lowest in AC specimens (and high ICOS expression emerged as a negative prognosticator), suggesting that AC tumors might have a less favorable immunological environment and may not be suitable candidates for immunotherapy.

Regarding to novel immunotherapeutic targets, VISTA is a membrane protein typically expressed by myeloid cells, granulocytes, and T cells, serving as a negative checkpoint ligand for antigen-presenting cells and T cells.(139) Studies on various cancers, including lung, kidney, colorectal, endometrial, and ovarian, have shown VISTA expression in lymphocytes within the tumor microenvironment and by tumor cells.(140, 141) Its prognostic significance is often controversial: high VISTA expression correlates with improved OS in epithelioid mesothelioma but worse outcomes in colorectal tumors.(142-144) Our study found no significant impact of VISTA on OS, though immune cells in LCNEC and SCLC expressed VISTA more than in AC tumors. This suggests that VISTA may inhibit T lymphocyte function, reducing antitumor response and making it a potential treatment target.(139) Murine models have shown that VISTA inhibition increases T lymphocyte numbers and enhances their function. A phase 1 clinical trial is currently evaluating the efficacy of an anti-VISTA monoclonal antibody (JNJ-61610588) in various solid tumors. Additionally, another ongoing multicenter study is examining the long-term effects of CA-170, a PD-L1/PD-L2 and VISTA inhibitor, in solid tumors and lymphomas. These studies aim to determine whether targeting VISTA can improve immune response and patient outcomes in various malignancies.(139, 145-148)

The OX40 ligand (OX40L) is an immune checkpoint modulator primarily found on activated antigen-presenting cells (APCs), dendritic cells, B cells, and macrophages.(149) Its interaction with OX40 enhances the survival of CD4⁺ and CD8⁺ cells, boosting tumor-specific responses of effector T cells and counteracting the suppressive effects of regulatory T cells (Tregs).(150) A recent study on NSCLC revealed that elevated OX40L expression is associated with increased CD4⁺ infiltration and improved OS.(151) Similar findings have been reported in studies on SCLC, melanoma, and pancreatic ductal adenocarcinoma.(152, 153) Our findings did not show significant survival benefits associated with OX40L expression, which could be partly due to the small sample size. We did observe that AC tumor cells expressed OX40L at lower levels than other LNEN

tumor cells. Interestingly, in our previous study on LNENs, we found no significant differences in OX40 expression across histological subtypes, suggesting that OX40 and OX40L may have independent expression patterns.(154) Importantly, recent in vivo studies indicate that both agonistic and antagonistic therapies targeting the OX40-OX40L interaction could be promising therapeutic options.(81, 149, 150)

GITR, a costimulatory cell surface receptor, is an attractive target for immunotherapy due to its significant role in activating effector T cells.(155) Primarily expressed on T cells and natural killer (NK) cells, GITR enhances the immune system's anti-tumoral response by stimulating T lymphocyte activity and inhibiting regulatory T cells (Tregs). The first clinical trial of the GITR agonist TRX518 in solid tumors began in 2018. Despite combining TRX518 with PD-1 and PD-L1 inhibitors, the trial showed only modest survival benefits and did not meet primary endpoints.(83, 84, 156, 157) However, several ongoing studies continue to investigate GITR targeting(158, 159). Increased GITR expression has been identified as a positive prognostic factor in endometrial carcinoma and head and neck tumors but is associated with worse outcomes in renal carcinoma.(156-158) In our cohort, GITR was expressed to a greater degree by AC tumor cells than LCNEC and SCLC tumor cells, and immune cells in ACs expressed significantly less GITR compared to LCNEC and SCLC tissue samples. Notably, the impact of GITR expression on tumor-infiltrating immune cells changes over time. Initially, GITR activation inhibits Tregs, leading to increased immune infiltration. However, as time progresses, GITR activation exerts the opposite effect, ultimately inhibiting the antitumor immune response.(83, 155, 160-162) In our previous study, we observed that AC tumors, which typically have the highest GITR expression, had significantly lower levels of tumor-infiltrating CD8+ and CD3+ lymphocytes compared to LCNEC and SCLC tumors with high GITR expression.(154) Regarding survival, low GITR expression in the tumor environment showed a borderline significant trend towards improved survival, a trend that persisted in the Cox regression model.

TIM3, primarily expressed on NK cells and macrophages, was the final protein examined in our study. As a negative regulator of T cells, TIM3 induces immunosuppression and inhibits anti-tumor immunity, making it a potential target for inhibition.(86, 87, 163) Blocking both TIM3 and PD-1 has shown to cause tumor regression in preclinical models, and several clinical trials are investigating TIM3 inhibition in solid tumors.(158, 164,

165) Our findings revealed that both tumor cells and immune cells expressed TIM3 more in AC tumors than in LCNEC and SCLC tumors. Clinically, high TIM3 expression by tumor cells and immune cells was generally associated with improved survival. However, patients with AC tumors typically had a better prognosis than those with other LNENs, and TIM3 expression could not be confirmed as an independent prognostic factor in our multivariate model. Nevertheless, the high expression of TIM3 in AC tumors suggests that it could be a promising subtype-specific immunotherapeutic target for AC patients.

In recent years, targeting the PD-1/PD-L1 axis has revolutionized the treatment landscape for many solid tumors, including melanoma, urothelial carcinoma, and NSCLC.(166) However, the success seen with immune checkpoint inhibitors in these cancers has not been replicated in LNENs. Neuroendocrine tumors, particularly those with AC histology, generally exhibit low PD-L1 expression.(48, 167, 168) In the rare instances where PD-L1 expression is observed, it has been associated with improved survival in both LCNEC and SCLC patients.(168, 169) Our results confirmed low or absent PD-L1 expression in LNENs. Specifically, PD-L1 was only present in a subset of LCNEC tumors and was absent in both SCLC and AC samples. Similarly, tumor cell PD-1 expression was low across all three LNEN subtypes, while immune cells exhibited slightly higher expression levels. Importantly, neither PD-1 nor PD-L1 expression significantly impacted survival in our cohort. Given the much lower PD-L1 expression in these tumors compared to NSCLC and the lack of correlation with immune checkpoint inhibitor efficacy, alternative predictive biomarkers are needed for LNENs. Potential alternatives include tissue-based tumor mutation burden (TMB) and the tumor's inflammatory phenotype, which may offer more promising insights in these cases.(88, 115)

Despite the distinct expression patterns of VISTA, OX40L, GITR, and TIM3, cluster analysis did not distinguish between LNEN subtypes. However, when we supplemented our current results with findings from an overlapping cohort (154), it became clear that LNEN tumors exhibit widely different immune phenotypes. Notably, AC tumors were found to be the least immunogenic among the LNENs studied, despite having the highest expression of TIM3 and GITR in tumor cells. These immune profiles can aid in diagnosing specific histologic subsets and predicting potential therapeutic responses to immune checkpoint blockade. It is important to consider that the expression of VISTA, OX40L, GITR, and TIM3 regulates the tumor immune microenvironment through

complex, time-dependent processes.(80, 81, 83, 84, 86, 87, 148, 155, 161, 163, 164, 170) These factors should be taken into account when assessing their impact on intratumoral immune cell distribution and antitumor response.

Recent reports suggest a molecular link between low- and high-grade NENs.(113, 171, 172) Alcala et al. identified a subgroup of atypical carcinoids, termed supracarcinoids, which display a carcinoid morphological pattern but possess molecular characteristics similar to LCNEC.(171) Additionally, various studies indicate that LNENs are not monolithic entities; combined neuroendocrine carcinomas can contain both SCLC and LCNEC components, or even AC elements.(101, 113, 173, 174) This supports the concept of lineage plasticity in these tumors. Beyond specific genes influencing neuroendocrine differentiation and morphology, the immune system might also impact tumor fate.(101, 173, 174) Our study's unsupervised clustering, using an immune panel, successfully differentiated tumor samples of different histologies, despite a small study population. This finding further underscores the potential role of the immune system in influencing tumor fate. However, no definitive conclusions regarding LNEN tumor transition can be drawn from our results. Further investigation is needed to explore the biological characteristics, molecular profiles, and clinical behavior of these tumors to better understand their transitions and lineage plasticity.

Our work has certain limitations that need to be addressed in future settings. Although we managed to collect a relatively large number of surgically treated LNEN samples ideal for profiling studies, the overall size of the study cohort remained small. Additionally, the retrospective design limited the collection of clinicopathological variables in most cases. Moreover, our study is not suited to examine the direct effects of immunotherapy, as we only included surgically treated patients where ICIs are not part of the standard care. Nevertheless, our findings may be hypothesis-generating and provide a framework for future validation studies. Another limitation is the inclusion of SCLC patients over a relatively long period. Although FFPE blocks are well-preserved, some older blocks might show decreased nuclear immunosignal intensity.(92, 93) Despite obtaining positive staining with quality check antibodies (CD56 and Ki-67) (94, 95) in the three oldest blocks, weaker-than-expected Ki-67 staining rates suggest potential signal reduction in some cases.

This study is more descriptive and hypothesis-generating than evidence-based, as we did not focus on the mechanism of the four selected proteins but aimed to provide insight into the targetability of these tumors with ICIs from a pathological perspective. The analysis of surgically removed whole tissue sections and randomly selected areas in each sample helped counterbalance some limitations, providing a comprehensive overview of the tumors' immunologic landscape while considering the potential confounding effects of tumoral heterogeneity.

6. Conclusions

Our study is among the first to investigate the specific aspects of TIM in surgically resected LNENs, using a large panel of immune-related markers. We report that LNENs have widely divergent immunologic profiles and the expression pattern of investigated markers varies significantly within the different histological subtypes. These LNEN-specific immune signatures might be a valuable resource for the development of future immune checkpoint inhibitor-based therapeutic strategies.

By investigating the expression pattern of potential immunotherapy targets in intermediate- and high-grade LNENs, the current multicenter study aimed to aid the future implementation of novel immunotherapeutic approaches. We report that high tumor cell TIM3 expression is characteristic of AC tumors, whereas elevated GITR levels in tumor cells could be found in both ACs and SCLCs. OX40L expression by tumor cells is the highest in SCLCs and the lowest in ACs. Immune cell infiltration is the least pronounced in AC lesions, and immune cell VISTA and GITR expressions are also considerably lower in these intermediate-grade malignancies. Altogether, these results might open alternative diagnostic approaches and new immunotherapeutic horizons in these hard-to-treat malignancies.

7. Summary

Intermediate-, and especially high-grade neuroendocrine lung neoplasms are aggressive tumors, with high metastatic potential and poor prognosis. Due to their relative rarity and complex biology, our knowledge of these entities remains very limited. In the last few years, molecular studies have shed more light on these tumors, thus bringing us closer to understand their development and behavior. However, there are still many gaps in our knowledge regarding their treatment; consequently, the therapeutic arsenal has not changed significantly over the past 30 years. Therefore, it is of utmost importance to understand the microenvironment of LNENs, map their TIM, and thereby identify potential therapeutic targets for future investigations. To answer these questions, we examined surgically resected histological samples from a total of 156 patients diagnosed with LNENs (26 AC, 64 LCNEC and 66 SCLC). A total of 19 immune markers (PD-L1, PD-1, CD3, CD4, CD8, CD27, CD47, IDO, ICOS, CD70, CD137, CD40, NKG2A, LAG3, OX40, VISTA, OX40L, GITR and TIM3) were used to explore the tumor immune profile.

Our results show a significantly different immune marker expression pattern between these 3 tumor types. Based on this, a well-matched immune marker profile allows a good differentiation between LNENs. The immunological landscape of AC tumors is sparse whereas the majority of highly aggressive LCNEC and SCLC samples are dominated by high expression of immunological markers. In case of the 4 novel immunotherapeutic targets, we have found that ACs have high TIM3 tumor cell expression, GITR is highly expressed in both AC and SCLC tumor cells, while OX40L is most highly expressed in SCLC tumor cells.

Ultimately, since our results provide a deeper understanding of the immunologic nature of these tumors, they represent an important first step towards the development of effective and appropriate immunotherapeutic strategies and immunotherapy-based clinical trials for these deadly diseases.

8. References

1. Thandra KC, Barsouk A, Saginala K, Aluru JS, Barsouk A. Epidemiology of lung cancer. *Contemp Oncol (Pozn)*. 2021;25(1):45-52.
2. Ferlay J, Colombet M, Soerjomataram I, Parkin DM, Piñeros M, Znaor A, Bray F. Cancer statistics for the year 2020: An overview. *Int J Cancer*. 2021.
3. Ferlay J, Steliarova-Foucher E, Lortet-Tieulent J, Rosso S, Coebergh JW, Comber H, Forman D, Bray F. Cancer incidence and mortality patterns in Europe: estimates for 40 countries in 2012. *Eur J Cancer*. 2013;49(6):1374-1403.
4. Bray F, Ferlay J, Soerjomataram I, Siegel RL, Torre LA, Jemal A. Global cancer statistics 2018: GLOBOCAN estimates of incidence and mortality worldwide for 36 cancers in 185 countries. *CA Cancer J Clin*. 2018;68(6):394-424.
5. Ferlay J, Colombet M, Soerjomataram I, Dyba T, Randi G, Bettio M, Gavin A, Visser O, Bray F. Cancer incidence and mortality patterns in Europe: Estimates for 40 countries and 25 major cancers in 2018. *Eur J Cancer*. 2018;103:356-387.
6. Bogos K, Kiss Z, Gálffy G, Tamási L, Ostoros G, Müller V, Urbán L, Bittner N, Sárosi V, Vastag A, Polányi Z, Nagy-Erdei Z, Vokó Z, Nagy B, Rokszin G, Abonyi-Tóth Z, Moldvay J. Novel approaches to the epidemiology of lung cancer in Hungary. *Magyar onkologia*. 2020;64:175-181.
7. Metovic J, Barella M, Bianchi F, Hofman P, Hofman V, Remmelink M, Kern I, Carvalho L, Pattini L, Sonzogni A, Veronesi G, Harari S, Forest F, Papotti M, Pelosi G. Morphologic and molecular classification of lung neuroendocrine neoplasms. *Virchows Arch*. 2021;478(1):5-19.
8. Nicholson AG, Tsao MS, Beasley MB, Borczuk AC, Brambilla E, Cooper WA, Dacic S, Jain D, Kerr KM, Lantuejoul S, Noguchi M, Papotti M, Rekhtman N, Scagliotti G, van Schil P, Sholl L, Yatabe Y, Yoshida A, Travis WD. The 2021 WHO Classification of Lung Tumors: Impact of Advances Since 2015. *J Thorac Oncol*. 2022;17(3):362-387.
9. Sung H, Ferlay J, Siegel RL, Laversanne M, Soerjomataram I, Jemal A, Bray F. Global Cancer Statistics 2020: GLOBOCAN Estimates of Incidence and Mortality Worldwide for 36 Cancers in 185 Countries. *CA: A Cancer Journal for Clinicians*. 2021;71(3):209-249.
10. Travis WD, Brambilla E, Nicholson AG, Yatabe Y, Austin JHM, Beasley MB, Chirieac LR, Dacic S, Duhig E, Flieder DB, Geisinger K, Hirsch FR, Ishikawa Y, Kerr

- KM, Noguchi M, Pelosi G, Powell CA, Tsao MS, Wistuba I. The 2015 World Health Organization Classification of Lung Tumors: Impact of Genetic, Clinical and Radiologic Advances Since the 2004 Classification. *J Thorac Oncol.* 2015;10(9):1243-1260.
11. Hendifar AE, Marchevsky AM, Tuli R. Neuroendocrine Tumors of the Lung: Current Challenges and Advances in the Diagnosis and Management of Well-Differentiated Disease. *J Thorac Oncol.* 2017;12(3):425-436.
 12. Morandi U, Casali C, Rossi G. Bronchial typical carcinoid tumors. *Semin Thorac Cardiovasc Surg.* 2006;18(3):191-198.
 13. Pusceddu S, Lo Russo G, Macerelli M, Proto C, Vitali M, Signorelli D, Ganzinelli M, Scanagatta P, Duranti L, Trama A, Buzzoni R, Pelosi G, Pastorino U, de Braud F, Garassino MC. Diagnosis and management of typical and atypical lung carcinoids. *Crit Rev Oncol Hematol.* 2016;100:167-176.
 14. Randhawa S, Trikalinos N, Patterson GA. Neuroendocrine Tumors of the Lung. *Thorac Surg Clin.* 2021;31(4):469-476.
 15. Metovic J, Barella M, Pelosi G. Neuroendocrine neoplasms of the lung: a pathology update. *memo - Magazine of European Medical Oncology.* 2021;14(4):381-385.
 16. Ferrara MG, Stefani A, Simbolo M, Pilotto S, Martini M, Lococo F, Vita E, Chiappetta M, Cancellieri A, D'Argento E, Trisolini R, Rindi G, Scarpa A, Margaritora S, Milella M, Tortora G, Bria E. Large Cell Neuro-Endocrine Carcinoma of the Lung: Current Treatment Options and Potential Future Opportunities. *Front Oncol.* 2021;11:650293.
 17. Borczuk AC. Pulmonary Neuroendocrine Tumors. *Surg Pathol Clin.* 2020;13(1):35-55.
 18. Megyesfalvi Z, Gay CM, Popper H, Pirker R, Ostoros G, Heeke S, Lang C, Hoetzenecker K, Schwendenwein A, Boettiger K, Bunn jr PA, Renyi-Vamos F, Schelch K, Prosch H, Byers LA, Hirsch FR, Dome B. Clinical insights into small cell lung cancer: Tumor heterogeneity, diagnosis, therapy, and future directions. *CA: A Cancer Journal for Clinicians.*n/a(n/a).
 19. Cakir M, Grossman A. The molecular pathogenesis and management of bronchial carcinoids. *Expert Opin Ther Targets.* 2011;15(4):457-491.

20. Leotlela PD, Jauch A, Holtgreve-Grez H, Thakker RV. Genetics of neuroendocrine and carcinoid tumours. *Endocr Relat Cancer*. 2003;10(4):437-450.
21. Oliveira AM, Tazelaar HD, Wentzlaff KA, Kosugi NS, Hai N, Benson A, Miller DL, Yang P. Familial pulmonary carcinoid tumors. *Cancer*. 2001;91(11):2104-2109.
22. Petursdottir A, Sigurdardottir J, Fridriksson BM, Johnsen A, Isaksson HJ, Hardardottir H, Jonsson S, Gudbjartsson T. Pulmonary carcinoid tumours: incidence, histology, and surgical outcome. A population-based study. *Gen Thorac Cardiovasc Surg*. 2020;68(5):523-529.
23. Almquist DR, Sonbol MB, Ross HJ, Kosiorek H, Jaroszewski D, Halfdanarson T. Clinical Characteristics of Diffuse Idiopathic Pulmonary Neuroendocrine Cell Hyperplasia: A Retrospective Analysis. *Chest*. 2021;159(1):432-434.
24. Hayes AR, Luong TV, Banks J, Shah H, Watkins J, Lim E, Patel A, Grossman AB, Navalkisoor S, Krell D, Caplin ME. Diffuse idiopathic pulmonary neuroendocrine cell hyperplasia (DIPNECH): Prevalence, clinicopathological characteristics and survival outcome in a cohort of 311 patients with well-differentiated lung neuroendocrine tumours. *J Neuroendocrinol*. 2022;34(10):e13184.
25. Koo CW, Baliff JP, Torigian DA, Litzky LA, Gefter WB, Akers SR. Spectrum of pulmonary neuroendocrine cell proliferation: diffuse idiopathic pulmonary neuroendocrine cell hyperplasia, tumorlet, and carcinoids. *AJR Am J Roentgenol*. 2010;195(3):661-668.
26. Sun TY, Hwang G, Pancirer D, Hornbacker K, Codima A, Lui NS, Raj R, Kunz P, Padda SK. Diffuse idiopathic pulmonary neuroendocrine cell hyperplasia: clinical characteristics and progression to carcinoid tumour. *Eur Respir J*. 2022;59(1).
27. Samhuri BF, Halfdanarson TR, Koo CW, McCarthy C, Yi ES, Thomas CF, Ryu JH. DIPNECH: pragmatic approach, uncertainties, notable associations, and a proposal for an improved definition. *Endocr Relat Cancer*. 2023;30(10).
28. Travis WD. Lung Cancer Pathology: Current Concepts. *Clin Chest Med*. 2020;41(1):67-85.
29. Network NCC. Small cell lung cancer (Version 3.2024). 2024.
30. Kalemkerian GP, Akerley W, Bogner P, Borghaei H, Chow LQ, Downey RJ, Gandhi L, Ganti AK, Govindan R, Grecula JC, Hayman J, Heist RS, Horn L, Jahan T, Koczywas M, Loo BW, Jr., Merritt RE, Moran CA, Niell HB, O'Malley J, Patel JD, Ready

- N, Rudin CM, Williams CC, Jr., Gregory K, Hughes M. Small cell lung cancer. *J Natl Compr Canc Netw*. 2013;11(1):78-98.
31. Gustafsson BI, Kidd M, Chan A, Malfertheiner MV, Modlin IM. Bronchopulmonary neuroendocrine tumors. *Cancer*. 2008;113(1):5-21.
 32. Naalsund A, Rostad H, Strøm EH, Lund MB, Strand TE. Carcinoid lung tumors-incidence, treatment and outcomes: a population-based study. *Eur J Cardiothorac Surg*. 2011;39(4):565-569.
 33. Soldath P, Petersen RH. The Surgical Management of Lung Neuroendocrine Neoplasms. *Cancers (Basel)*. 2023;15(6).
 34. Fisseler-Eckhoff A, Demes M. Neuroendocrine tumors of the lung. *Cancers (Basel)*. 2012;4(3):777-798.
 35. Zoccarato M, Grisold W. Paraneoplastic neurologic manifestations of neuroendocrine tumors. *Handb Clin Neurol*. 2024;200:397-407.
 36. Iams WT, Shiuan E, Meador CB, Roth M, Bordeaux J, Vaupel C, Boyd KL, Summitt IB, Wang LL, Schneider JT, Warner JL, Zhao Z, Lovly CM. Improved Prognosis and Increased Tumor-Infiltrating Lymphocytes in Patients Who Have SCLC With Neurologic Paraneoplastic Syndromes. *J Thorac Oncol*. 2019;14(11):1970-1981.
 37. Soomro Z, Youssef M, Yust-Katz S, Jalali A, Patel AJ, Mandel J. Paraneoplastic syndromes in small cell lung cancer. *J Thorac Dis*. 2020;12(10):6253-6263.
 38. Gade AK, Olariu E, Douthit NT. Carcinoid Syndrome: A Review. *Cureus*. 2020;12(3):e7186.
 39. Savu C, Melinte A, Diaconu C, Stiru O, Gherghiceanu F, Tudorica Ş DO, Dumitraşcu OC, Bratu A, Balescu I, Bacalbasa N. Lung neuroendocrine tumors: A systematic literature review (Review). *Exp Ther Med*. 2022;23(2):176.
 40. Granberg D, Juhlin CC, Falhammar H, Hedayati E. Lung Carcinoids: A Comprehensive Review for Clinicians. *Cancers (Basel)*. 2023;15(22).
 41. Gazdar AF, Bunn PA, Minna JD. Small-cell lung cancer: what we know, what we need to know and the path forward. *Nat Rev Cancer*. 2017;17(12):725-737.
 42. Ramirez RA, Cass AS, Das S, Low SW, Mehrad M, Rickman OB, Scherer PM, Thomas KE, Gillaspie EA. A multidisciplinary approach to the work up and management of pulmonary carcinoid tumors and DIPNECH: a narrative review. *Transl Lung Cancer Res*. 2022;11(12):2567-2587.

43. Roesel C, Welter S, Kambartel KO, Weinreich G, Krbek T, Serke M, Ibrahim M, Alnajdawi Y, Plönes T, Aigner C. Prognostic markers in resected large cell neuroendocrine carcinoma: a multicentre retrospective analysis. *J Thorac Dis.* 2020;12(3):466-476.
44. Kurul IC, Topçu S, Taştepe I, Yazici Ü, Altinok T, Cetinçetin G. Surgery in bronchial carcinoids: experience with 83 patients. *European journal of cardio-thoracic surgery.* 2002;21(5):883-887.
45. Reuling E, Dickhoff C, Plaisier PW, Bonjer HJ, Daniels JMA. Endobronchial and surgical treatment of pulmonary carcinoid tumors: A systematic literature review. *Lung Cancer.* 2019;134:85-95.
46. Caplin ME, Pavel M, Ćwikła JB, Phan AT, Raderer M, Sedláčková E, Cadiot G, Wolin EM, Capdevila J, Wall L. Lanreotide in metastatic enteropancreatic neuroendocrine tumors. *New England Journal of Medicine.* 2014;371(3):224-233.
47. Rinke A, Müller H-H, Schade-Brittinger C, Klose K-J, Barth P, Wied M, Mayer C, Aminossadati B, Pape U-F, Bläker M. Placebo-controlled, double-blind, prospective, randomized study on the effect of octreotide LAR in the control of tumor growth in patients with metastatic neuroendocrine midgut tumors: a report from the PROMID Study Group. *Journal of Clinical oncology.* 2009;27(28):4656-4663.
48. Tsuruoka K, Horinouchi H, Goto Y, Kanda S, Fujiwara Y, Nokihara H, Yamamoto N, Asakura K, Nakagawa K, Sakurai H. PD-L1 expression in neuroendocrine tumors of the lung. *Lung Cancer.* 2017;108:115-120.
49. Mehnert JM, Bergsland E, O'neil BH, Santoro A, Schellens JH, Cohen RB, Doi T, Ott PA, Pishvaian MJ, Puzanov I. Pembrolizumab for the treatment of programmed death–ligand 1–positive advanced carcinoid or pancreatic neuroendocrine tumors: Results from the KEYNOTE-028 study. *Cancer.* 2020;126(13):3021-3030.
50. Naidoo J, Santos-Zabala ML, Iyriboz T, Woo KM, Sima CS, Fiore JJ, Kris MG, Riely GJ, Lito P, Iqbal A, Veach S, Smith-Marrone S, Sarkaria IS, Krug LM, Rudin CM, Travis WD, Rekhtman N, Pietanza MC. Large Cell Neuroendocrine Carcinoma of the Lung: Clinico-Pathologic Features, Treatment, and Outcomes. *Clin Lung Cancer.* 2016;17(5):e121-e129.
51. Zacharias J, Nicholson AG, Ladas GP, Goldstraw P. Large cell neuroendocrine carcinoma and large cell carcinomas with neuroendocrine morphology of the lung:

prognosis after complete resection and systematic nodal dissection. *Ann Thorac Surg.* 2003;75(2):348-352.

52. Rieber J, Schmitt J, Warth A, Muley T, Kappes J, Eichhorn F, Hoffmann H, Heussel CP, Welzel T, Debus J, Thomas M, Steins M, Rieken S. Outcome and prognostic factors of multimodal therapy for pulmonary large-cell neuroendocrine carcinomas. *Eur J Med Res.* 2015;20(1):64.

53. Eldessouki I, Gaber O, Namad T, Wang J, Morris JC, Abdel Karim N. Small or Non-Small Cell Lung Cancer Based Therapy for Treatment of Large Cell Neuroendocrine Cancer of The Lung? University of Cincinnati Experience. *J Oncol.* 2018;2018:9761826.

54. Yang L, Fan Y, Lu H. Pulmonary Large Cell Neuroendocrine Carcinoma. *Pathol Oncol Res.* 2022;28:1610730.

55. Atieh T, Huang CH. Treatment of Advanced-Stage Large Cell Neuroendocrine Cancer (LCNEC) of the Lung: A Tale of Two Diseases. *Front Oncol.* 2021;11:667468.

56. Masters GA, Temin S, Azzoli CG, Giaccone G, Baker S, Jr., Brahmer JR, Ellis PM, Gajra A, Rackear N, Schiller JH, Smith TJ, Strawn JR, Trent D, Johnson DH. Systemic Therapy for Stage IV Non-Small-Cell Lung Cancer: American Society of Clinical Oncology Clinical Practice Guideline Update. *J Clin Oncol.* 2015;33(30):3488-3515.

57. Sun JM, Ahn MJ, Ahn JS, Um SW, Kim H, Kim HK, Choi YS, Han J, Kim J, Kwon OJ, Shim YM, Park K. Chemotherapy for pulmonary large cell neuroendocrine carcinoma: similar to that for small cell lung cancer or non-small cell lung cancer? *Lung Cancer.* 2012;77(2):365-370.

58. Schwendenwein A, Megyesfalvi Z, Barany N, Valko Z, Bugyik E, Lang C, Ferencz B, Paku S, Lantos A, Fillinger J, Rezeli M, Marko-Varga G, Bogos K, Galffy G, Renyi-Vamos F, Hoda MA, Klepetko W, Hoetzenecker K, Laszlo V, Dome B. Molecular profiles of small cell lung cancer subtypes: therapeutic implications. *Mol Ther Oncolytics.* 2021;20:470-483.

59. Rudin CM, Brambilla E, Faivre-Finn C, Sage J. Small-cell lung cancer. *Nat Rev Dis Primers.* 2021;7(1):3.

60. Anraku M, Waddell TK. Surgery for small-cell lung cancer. *Semin Thorac Cardiovasc Surg.* 2006;18(3):211-216.

61. Hoda MA, Klikovits T, Klepetko W. Controversies in oncology: surgery for small cell lung cancer? It's time to rethink the case. *ESMO Open*. 2018;3(3):e000366.
62. Combs SE, Hancock JG, Boffa DJ, Decker RH, Detterbeck FC, Kim AW. Bolstering the case for lobectomy in stages I, II, and IIIA small-cell lung cancer using the National Cancer Data Base. *J Thorac Oncol*. 2015;10(2):316-323.
63. Karim SM, Zekri J. Chemotherapy for small cell lung cancer: a comprehensive review. *Oncol Rev*. 2012;6(1):e4.
64. Scagliotti GV, Parikh P, von Pawel J, Biesma B, Vansteenkiste J, Manegold C, Serwatowski P, Gatzemeier U, Digumarti R, Zukin M, Lee JS, Mellempgaard A, Park K, Patil S, Rolski J, Goksel T, de Marinis F, Simms L, Sugarman KP, Gandara D. Phase III study comparing cisplatin plus gemcitabine with cisplatin plus pemetrexed in chemotherapy-naive patients with advanced-stage non-small-cell lung cancer. *J Clin Oncol*. 2008;26(21):3543-3551.
65. Horn L, Mansfield AS, Szczęśna A, Havel L, Krzakowski M, Hochmair MJ, Huemer F, Losonczy G, Johnson ML, Nishio M, Reck M, Mok T, Lam S, Shames DS, Liu J, Ding B, Lopez-Chavez A, Kabbinavar F, Lin W, Sandler A, Liu SV. First-Line Atezolizumab plus Chemotherapy in Extensive-Stage Small-Cell Lung Cancer. *N Engl J Med*. 2018;379(23):2220-2229.
66. Pavan A, Attili I, Pasello G, Guarneri V, Conte PF, Bonanno L. Immunotherapy in small-cell lung cancer: from molecular promises to clinical challenges. *J Immunother Cancer*. 2019;7(1):205.
67. Paz-Ares L, Dvorkin M, Chen Y, Reinmuth N, Hotta K, Trukhin D, Statsenko G, Hochmair MJ, Özgüroğlu M, Ji JH, Voitko O, Poltoratskiy A, Ponce S, Verderame F, Havel L, Bondarenko I, Kazarnowicz A, Losonczy G, Conev NV, Armstrong J, Byrne N, Shire N, Jiang H, Goldman JW. Durvalumab plus platinum-etoposide versus platinum-etoposide in first-line treatment of extensive-stage small-cell lung cancer (CASPIAN): a randomised, controlled, open-label, phase 3 trial. *Lancet*. 2019;394(10212):1929-1939.
68. Lim SM, Hong MH, Kim HR. Immunotherapy for Non-small Cell Lung Cancer: Current Landscape and Future Perspectives. *Immune Netw*. 2020;20(1):e10.
69. Albertelli M, Dotto A, Nista F, Veresani A, Patti L, Gay S, Sciallero S, Boschetti M, Ferone D. "Present and future of immunotherapy in Neuroendocrine Tumors". *Rev Endocr Metab Disord*. 2021;22(3):615-636.

70. Di Molfetta S, Feola T, Fanciulli G, Florio T, Colao A, Faggiano A, Nike G. Immune Checkpoint Blockade in Lung Carcinoids with Aggressive Behaviour: One More Arrow in Our Quiver? *J Clin Med*. 2022;11(4).
71. Komiya T, Ravindra N, Powell E. Role of Immunotherapy in Stage IV Large Cell Neuroendocrine Carcinoma of the Lung. *Asian Pac J Cancer Prev*. 2021;22(2):365-370.
72. Zimmermann S, Peters S, Owinokoko T, Gadgeel SM. Immune Checkpoint Inhibitors in the Management of Lung Cancer. *Am Soc Clin Oncol Educ Book*. 2018;38:682-695.
73. Berghmans T, Dingemans AM, Hendriks LEL, Cadranel J. Immunotherapy for nonsmall cell lung cancer: a new therapeutic algorithm. *Eur Respir J*. 2020;55(2).
74. Bremnes RM, Busund LT, Kilvær TL, Andersen S, Richardsen E, Paulsen EE, Hald S, Khanekkenari MR, Cooper WA, Kao SC, Dønnem T. The Role of Tumor-Infiltrating Lymphocytes in Development, Progression, and Prognosis of Non-Small Cell Lung Cancer. *J Thorac Oncol*. 2016;11(6):789-800.
75. Dantoing E, Piton N, Salaün M, Thiberville L, Guisier F. Anti-PD1/PD-L1 Immunotherapy for Non-Small Cell Lung Cancer with Actionable Oncogenic Driver Mutations. *Int J Mol Sci*. 2021;22(12).
76. Han Y, Liu D, Li L. PD-1/PD-L1 pathway: current researches in cancer. *Am J Cancer Res*. 2020;10(3):727-742.
77. Rowshanravan B, Halliday N, Sansom DM. CTLA-4: a moving target in immunotherapy. *Blood*. 2018;131(1):58-67.
78. Huang X, Zhang X, Li E, Zhang G, Wang X, Tang T, Bai X, Liang T. VISTA: an immune regulatory protein checking tumor and immune cells in cancer immunotherapy. *J Hematol Oncol*. 2020;13(1):83.
79. Mortezaee K, Majidpoor J, Najafi S. VISTA immune regulatory effects in bypassing cancer immunotherapy: Updated. *Life Sci*. 2022;310:121083.
80. Tagliamento M, Agostinetti E, Borea R, Brandão M, Poggio F, Addeo A, Lambertini M. VISTA: A Promising Target for Cancer Immunotherapy? *Immunotargets Ther*. 2021;10:185-200.
81. Lu X. OX40 and OX40L Interaction in Cancer. *Curr Med Chem*. 2021;28(28):5659-5673.

82. Redmond WL, Weinberg AD. Targeting OX40 and OX40L for the treatment of autoimmunity and cancer. *Crit Rev Immunol*. 2007;27(5):415-436.
83. Chan S, Belmar N, Ho S, Rogers B, Stickler M, Graham M, Lee E, Tran N, Zhang D, Gupta P, Sho M, MacDonough T, Woolley A, Kim H, Zhang H, Liu W, Zheng P, Dezso Z, Halliwill K, Ceccarelli M, Rhodes S, Thakur A, Forsyth CM, Xiong M, Tan SS, Iyer R, Lake M, Digiammarino E, Zhou L, Bigelow L, Longenecker K, Judge RA, Liu C, Trumble M, Remis JP, Fox M, Cairns B, Akamatsu Y, Hollenbaugh D, Harding F, Alvarez HM. An anti-PD-1-GITR-L bispecific agonist induces GITR clustering-mediated T cell activation for cancer immunotherapy. *Nat Cancer*. 2022;3(3):337-354.
84. Hernandez-Guerrero T, Moreno V. GITR Antibodies in Cancer: Not Ready for Prime Time. *Clin Cancer Res*. 2022;28(18):3905-3907.
85. Davar D, Zappasodi R, Wang H, Naik GS, Sato T, Bauer T, Bajor D, Rixe O, Newman W, Qi J, Holland A, Wong P, Sifferlen L, Piper D, Sirard CA, Merghoub T, Wolchok JD, Luke JJ. Phase IB Study of GITR Agonist Antibody TRX518 Singly and in Combination with Gemcitabine, Pembrolizumab, or Nivolumab in Patients with Advanced Solid Tumors. *Clin Cancer Res*. 2022;28(18):3990-4002.
86. Kandel S, Adhikary P, Li G, Cheng K. The TIM3/Gal9 signaling pathway: An emerging target for cancer immunotherapy. *Cancer Lett*. 2021;510:67-78.
87. Solinas C, De Silva P, Bron D, Willard-Gallo K, Sangiolo D. Significance of TIM3 expression in cancer: From biology to the clinic. *Semin Oncol*. 2019;46(4-5):372-379.
88. Drapkin BJ, Rudin CM. Advances in Small-Cell Lung Cancer (SCLC) Translational Research. *Cold Spring Harb Perspect Med*. 2021;11(4).
89. Jordan EJ, Kim HR, Arcila ME, Barron D, Chakravarty D, Gao J, Chang MT, Ni A, Kundra R, Jonsson P, Jayakumaran G, Gao SP, Johnsen HC, Hanrahan AJ, Zehir A, Rekhtman N, Ginsberg MS, Li BT, Yu HA, Paik PK, Drilon A, Hellmann MD, Reales DN, Benayed R, Rusch VW, Kris MG, Chaft JE, Baselga J, Taylor BS, Schultz N, Rudin CM, Hyman DM, Berger MF, Solit DB, Ladanyi M, Riely GJ. Prospective Comprehensive Molecular Characterization of Lung Adenocarcinomas for Efficient Patient Matching to Approved and Emerging Therapies. *Cancer Discov*. 2017;7(6):596-609.

90. Rudin CM, Poirier JT, Byers LA, Dive C, Dowlati A, George J, Heymach JV, Johnson JE, Lehman JM, MacPherson D, Massion PP, Minna JD, Oliver TG, Quaranta V, Sage J, Thomas RK, Vakoc CR, Gazdar AF. Molecular subtypes of small cell lung cancer: a synthesis of human and mouse model data. *Nat Rev Cancer*. 2019;19(5):289-297.
91. Baudin E, Caplin M, Garcia-Carbonero R, Fazio N, Ferolla P, Filosso PL, Frilling A, de Herder WW, Hörsch D, Knigge U, Korse CM, Lim E, Lombard-Bohas C, Pavel M, Scoazec JY, Sundin A, Berruti A. Lung and thymic carcinoids: ESMO Clinical Practice Guidelines for diagnosis, treatment and follow-up(☆). *Ann Oncol*. 2021;32(4):439-451.
92. Grillo F, Bruzzone M, Pigozzi S, Prosapio S, Migliora P, Fiocca R, Mastracci L. Immunohistochemistry on old archival paraffin blocks: is there an expiry date? *J Clin Pathol*. 2017;70(11):988-993.
93. Kokkat TJ, Patel MS, McGarvey D, LiVolsi VA, Baloch ZW. Archived formalin-fixed paraffin-embedded (FFPE) blocks: A valuable underexploited resource for extraction of DNA, RNA, and protein. *Biopreserv Biobank*. 2013;11(2):101-106.
94. Mlika M, Zendah I, Braham E, El Mezni F. CD56 antibody: old-fashioned or still trendy in endocrine lung tumors. *J Immunoassay Immunochem*. 2015;36(4):414-419.
95. Pelosi G, Rindi G, Travis WD, Papotti M. Ki-67 antigen in lung neuroendocrine tumors: unraveling a role in clinical practice. *J Thorac Oncol*. 2014;9(3):273-284.
96. Gu Z, Eils R, Schlesner M. Complex heatmaps reveal patterns and correlations in multidimensional genomic data. *Bioinformatics*. 2016;32(18):2847-2849.
97. Friedman J, Hastie T, Tibshirani R. Regularization Paths for Generalized Linear Models via Coordinate Descent. *J Stat Softw*. 2010;33(1):1-22.
98. Xie X, Li X, Tang W, Xie P, Tan X. Primary tumor location in lung cancer: the evaluation and administration. *Chin Med J (Engl)*. 2021;135(2):127-136.
99. Galli F, Aguilera JV, Palermo B, Markovic SN, Nisticò P, Signore A. Relevance of immune cell and tumor microenvironment imaging in the new era of immunotherapy. *Journal of Experimental & Clinical Cancer Research*. 2020;39(1):89.
100. Whiteside TL. Immune responses to malignancies. *J Allergy Clin Immunol*. 2010;125(2 Suppl 2):S272-283.
101. Gonzalez H, Hagerling C, Werb Z. Roles of the immune system in cancer: from tumor initiation to metastatic progression. *Genes Dev*. 2018;32(19-20):1267-1284.

102. Ruiz-Cordero R, Devine WP. Targeted Therapy and Checkpoint Immunotherapy in Lung Cancer. *Surg Pathol Clin*. 2020;13(1):17-33.
103. Bruni D, Angell HK, Galon J. The immune contexture and Immunoscore in cancer prognosis and therapeutic efficacy. *Nat Rev Cancer*. 2020;20(11):662-680.
104. Swarts DR, Henfling ME, Van Neste L, van Suylen RJ, Dingemans AM, Dinjens WN, Haesevoets A, Rudelius M, Thunnissen E, Volante M, Van Criekinge W, van Engeland M, Ramaekers FC, Speel EJ. CD44 and OTP are strong prognostic markers for pulmonary carcinoids. *Clin Cancer Res*. 2013;19(8):2197-2207.
105. Swarts DR, Scarpa A, Corbo V, Van Criekinge W, van Engeland M, Gatti G, Henfling ME, Papotti M, Perren A, Ramaekers FC, Speel EJ, Volante M. MEN1 gene mutation and reduced expression are associated with poor prognosis in pulmonary carcinoids. *J Clin Endocrinol Metab*. 2014;99(2):E374-378.
106. Altinay S, Metovic J, Massa F, Gatti G, Cassoni P, Scagliotti GV, Volante M, Papotti M. Spread through air spaces (STAS) is a predictor of poor outcome in atypical carcinoids of the lung. *Virchows Arch*. 2019;475(3):325-334.
107. Senbanjo LT, Chellaiah MA. CD44: A Multifunctional Cell Surface Adhesion Receptor Is a Regulator of Progression and Metastasis of Cancer Cells. *Front Cell Dev Biol*. 2017;5:18.
108. Swarts DR, Claessen SM, Jonkers YM, van Suylen RJ, Dingemans AM, de Herder WW, de Krijger RR, Smit EF, Thunnissen FB, Seldenrijk CA, Vink A, Perren A, Ramaekers FC, Speel EJ. Deletions of 11q22.3-q25 are associated with atypical lung carcinoids and poor clinical outcome. *Am J Pathol*. 2011;179(3):1129-1137.
109. Moonen L, Derks J, Dingemans AM, Speel EJ. Orthopedia Homeobox (OTP) in Pulmonary Neuroendocrine Tumors: The Diagnostic Value and Possible Molecular Interactions. *Cancers (Basel)*. 2019;11(10).
110. Papaxoinis G, Nonaka D, O'Brien C, Sanderson B, Krysiak P, Mansoor W. Prognostic Significance of CD44 and Orthopedia Homeobox Protein (OTP) Expression in Pulmonary Carcinoid Tumours. *Endocr Pathol*. 2017;28(1):60-70.
111. George J, Walter V, Peifer M, Alexandrov LB, Seidel D, Leenders F, Maas L, Müller C, Dahmen I, Delhomme TM, Ardin M, Leblay N, Byrnes G, Sun R, De Reynies A, McLeer-Florin A, Bosco G, Malchers F, Menon R, Altmüller J, Becker C, Nürnberg P, Achter V, Lang U, Schneider PM, Bogus M, Soloway MG, Wilkerson MD, Cun Y,

McKay JD, Moro-Sibilot D, Brambilla CG, Lantuejoul S, Lemaitre N, Soltermann A, Weder W, Tischler V, Brustugun OT, Lund-Iversen M, Helland Å, Solberg S, Ansén S, Wright G, Solomon B, Roz L, Pastorino U, Petersen I, Clement JH, Sängler J, Wolf J, Vingron M, Zander T, Perner S, Travis WD, Haas SA, Olivier M, Foll M, Büttner R, Hayes DN, Brambilla E, Fernandez-Cuesta L, Thomas RK. Integrative genomic profiling of large-cell neuroendocrine carcinomas reveals distinct subtypes of high-grade neuroendocrine lung tumors. *Nat Commun.* 2018;9(1):1048.

112. Derks JL, Leblay N, Lantuejoul S, Dingemans AC, Speel EM, Fernandez-Cuesta L. New Insights into the Molecular Characteristics of Pulmonary Carcinoids and Large Cell Neuroendocrine Carcinomas, and the Impact on Their Clinical Management. *J Thorac Oncol.* 2018;13(6):752-766.

113. Rekhtman N, Pietanza MC, Hellmann MD, Naidoo J, Arora A, Won H, Halpenny DF, Wang H, Tian SK, Litvak AM, Paik PK, Drilon AE, Socci N, Poirier JT, Shen R, Berger MF, Moreira AL, Travis WD, Rudin CM, Ladanyi M. Next-Generation Sequencing of Pulmonary Large Cell Neuroendocrine Carcinoma Reveals Small Cell Carcinoma-like and Non-Small Cell Carcinoma-like Subsets. *Clin Cancer Res.* 2016;22(14):3618-3629.

114. Wang HY, Li ZW, Sun W, Yang X, Zhou LX, Huang XZ, Jia L, Lin DM. Automated quantification of Ki-67 index associates with pathologic grade of pulmonary neuroendocrine tumors. *Chin Med J (Engl).* 2019;132(5):551-561.

115. Gay CM, Stewart CA, Park EM, Diao L, Groves SM, Heeke S, Nabet BY, Fujimoto J, Solis LM, Lu W, Xi Y, Cardnell RJ, Wang Q, Fabbri G, Cargill KR, Vokes NI, Ramkumar K, Zhang B, Della Corte CM, Robson P, Swisher SG, Roth JA, Glisson BS, Shames DS, Wistuba II, Wang J, Quaranta V, Minna J, Heymach JV, Byers LA. Patterns of transcription factor programs and immune pathway activation define four major subtypes of SCLC with distinct therapeutic vulnerabilities. *Cancer Cell.* 2021;39(3):346-360.e347.

116. Megyesfalvi Z, Barany N, Lantos A, Valko Z, Pipek O, Lang C, Schwendenwein A, Oberndorfer F, Paku S, Ferencz B, Dezso K, Fillinger J, Lohinai Z, Moldvay J, Galffy G, Szeitz B, Rezeli M, Rivard C, Hirsch FR, Brcic L, Popper H, Kern I, Kovacevic M, Skarda J, Mittak M, Marko-Varga G, Bogos K, Renyi-Vamos F, Hoda MA, Klikovits T, Hoetzenecker K, Schelch K, Laszlo V, Dome B. Expression patterns and prognostic

relevance of subtype-specific transcription factors in surgically resected small-cell lung cancer: an international multicenter study. *J Pathol.* 2022.

117. Szeitz B, Megyesfalvi Z, Woldmar N, Valkó Z, Schwendenwein A, Bárány N, Paku S, László V, Kiss H, Bugyik E, Lang C, Szász AM, Pizzatti L, Bogos K, Hoda MA, Hoetzenecker K, Marko-Varga G, Horvatovich P, Döme B, Schelch K, Rezeli M. In-depth proteomic analysis reveals unique subtype-specific signatures in human small-cell lung cancer. *Clin Transl Med.* 2022;12(9):e1060.

118. Borst L, Sluijter M, Sturm G, Charoentong P, Santegoets SJ, van Gulijk M, van Elsas MJ, Groeneveldt C, van Montfoort N, Finotello F, Trajanoski Z, Kiełbasa SM, van der Burg SH, van Hall T. NKG2A is a late immune checkpoint on CD8 T cells and marks repeated stimulation and cell division. *Int J Cancer.* 2022;150(4):688-704.

119. Zhao H, Wang J, Kong X, Li E, Liu Y, Du X, Kang Z, Tang Y, Kuang Y, Yang Z, Zhou Y, Wang Q. CD47 Promotes Tumor Invasion and Metastasis in Non-small Cell Lung Cancer. *Sci Rep.* 2016;6:29719.

120. Michaels AD, Newhook TE, Adair SJ, Morioka S, Goudreau BJ, Nagdas S, Mullen MG, Persily JB, Bullock TNJ, Slingsluff CL, Jr., Ravichandran KS, Parsons JT, Bauer TW. CD47 Blockade as an Adjuvant Immunotherapy for Resectable Pancreatic Cancer. *Clin Cancer Res.* 2018;24(6):1415-1425.

121. Nigro A, Ricciardi L, Salvato I, Sabbatino F, Vitale M, Crescenzi MA, Montico B, Triggiani M, Pepe S, Stellato C, Casolaro V, Dal Col J. Enhanced Expression of CD47 Is Associated With Off-Target Resistance to Tyrosine Kinase Inhibitor Gefitinib in NSCLC. *Front Immunol.* 2019;10:3135.

122. Yuan J, Shi X, Chen C, He H, Liu L, Wu J, Yan H. High expression of CD47 in triple negative breast cancer is associated with epithelial-mesenchymal transition and poor prognosis. *Oncol Lett.* 2019;18(3):3249-3255.

123. Arrieta O, Aviles-Salas A, Orozco-Morales M, Hernández-Pedro N, Cardona AF, Cabrera-Miranda L, Barrios-Bernal P, Soca-Chafre G, Cruz-Rico G, Peña-Torres ML, Moncada-Claudio G, Ramirez-Tirado LA. Association between CD47 expression, clinical characteristics and prognosis in patients with advanced non-small cell lung cancer. *Cancer Med.* 2020;9(7):2390-2402.

124. Sabel MS, Yamada M, Kawaguchi Y, Chen FA, Takita H, Bankert RB. CD40 expression on human lung cancer correlates with metastatic spread. *Cancer Immunol Immunother.* 2000;49(2):101-108.
125. Yan C, Richmond A. Hiding in the dark: pan-cancer characterization of expression and clinical relevance of CD40 to immune checkpoint blockade therapy. *Mol Cancer.* 2021;20(1):146.
126. Glorieux C, Huang P. Regulation of CD137 expression through K-Ras signaling in pancreatic cancer cells. *Cancer Commun (Lond).* 2019;39(1):41.
127. Tang Z, Kang B, Li C, Chen T, Zhang Z. GEPIA2: an enhanced web server for large-scale expression profiling and interactive analysis. *Nucleic Acids Res.* 2019;47(W1):W556-w560.
128. Li T, Fu J, Zeng Z, Cohen D, Li J, Chen Q, Li B, Liu XS. TIMER2.0 for analysis of tumor-infiltrating immune cells. *Nucleic Acids Res.* 2020;48(W1):W509-w514.
129. Kawai O, Ishii G, Kubota K, Murata Y, Naito Y, Mizuno T, Aokage K, Saijo N, Nishiwaki Y, Gemma A, Kudoh S, Ochiai A. Predominant infiltration of macrophages and CD8(+) T Cells in cancer nests is a significant predictor of survival in stage IV nonsmall cell lung cancer. *Cancer.* 2008;113(6):1387-1395.
130. Wakabayashi O, Yamazaki K, Oizumi S, Hommura F, Kinoshita I, Ogura S, Dosaka-Akita H, Nishimura M. CD4+ T cells in cancer stroma, not CD8+ T cells in cancer cell nests, are associated with favorable prognosis in human non-small cell lung cancers. *Cancer Sci.* 2003;94(11):1003-1009.
131. Tian C, Lu S, Fan Q, Zhang W, Jiao S, Zhao X, Wu Z, Sun L, Wang L. Prognostic significance of tumor-infiltrating CD8⁺ or CD3⁺ T lymphocytes and interleukin-2 expression in radically resected non-small cell lung cancer. *Chin Med J (Engl).* 2015;128(1):105-110.
132. Wang H, Li Z, Dong B, Sun W, Yang X, Liu R, Zhou L, Huang X, Jia L, Lin D. Prognostic significance of PD-L1 expression and CD8⁺ T cell infiltration in pulmonary neuroendocrine tumors. *Diagn Pathol.* 2018;13(1):30.
133. He Y, Rivard CJ, Rozeboom L, Yu H, Ellison K, Kowalewski A, Zhou C, Hirsch FR. Lymphocyte-activation gene-3, an important immune checkpoint in cancer. *Cancer Sci.* 2016;107(9):1193-1197.

134. Sun H, Dai J, Zhao L, Zhu J, Wang H, Chen P, Lu H, Chen Q, Zhang Z. Lymphocyte activation gene-3 is associated with programmed death-ligand 1 and programmed cell death protein 1 in small cell lung cancer. *Ann Transl Med.* 2021;9(18):1468.
135. Long L, Zhang X, Chen F, Pan Q, Phiphatwatchara P, Zeng Y, Chen H. The promising immune checkpoint LAG-3: from tumor microenvironment to cancer immunotherapy. *Genes Cancer.* 2018;9(5-6):176-189.
136. Solinas C, Gu-Trantien C, Willard-Gallo K. The rationale behind targeting the ICOS-ICOS ligand costimulatory pathway in cancer immunotherapy. *ESMO Open.* 2020;5(1).
137. Amatore F, Gorvel L, Olive D. Role of Inducible Co-Stimulator (ICOS) in cancer immunotherapy. *Expert Opin Biol Ther.* 2020;20(2):141-150.
138. Wu G, He M, Ren K, Ma H, Xue Q. Inducible Co-Stimulator ICOS Expression Correlates with Immune Cell Infiltration and Can Predict Prognosis in Lung Adenocarcinoma. *Int J Gen Med.* 2022;15:3739-3751.
139. Le Mercier I, Chen W, Lines JL, Day M, Li J, Sergent P, Noelle RJ, Wang L. VISTA Regulates the Development of Protective Antitumor Immunity. *Cancer Res.* 2014;74(7):1933-1944.
140. Hendry S, Salgado R, Gevaert T, Russell PA, John T, Thapa B, Christie M, van de Vijver K, Estrada MV, Gonzalez-Ericsson PI, Sanders M, Solomon B, Solinas C, Van den Eynden G, Allory Y, Preusser M, Hainfellner J, Pruneri G, Vingiani A, Demaria S, Symmans F, Nuciforo P, Comerma L, Thompson EA, Lakhani S, Kim SR, Schnitt S, Colpaert C, Sotiriou C, Scherer SJ, Ignatiadis M, Badve S, Pierce RH, Viale G, Sirtaine N, Penault-Llorca F, Sugie T, Fineberg S, Paik S, Srinivasan A, Richardson A, Wang Y, Chmielik E, Brock J, Johnson DB, Balko J, Wienert S, Bossuyt V, Michiels S, Ternes N, Burchardi N, Luen SJ, Savas P, Klauschen F, Watson PH, Nelson BH, Criscitiello C, O'Toole S, Larsimont D, de Wind R, Curigliano G, André F, Lacroix-Triki M, van de Vijver M, Rojo F, Floris G, Bedri S, Sparano J, Rimm D, Nielsen T, Kos Z, Hewitt S, Singh B, Farshid G, Loibl S, Allison KH, Tung N, Adams S, Willard-Gallo K, Horlings HM, Gandhi L, Moreira A, Hirsch F, Dieci MV, Urbanowicz M, Brcic I, Korski K, Gaire F, Koeppen H, Lo A, Giltane J, Rebelatto MC, Steele KE, Zha J, Emancipator K, Juco JW, Denkert C, Reis-Filho J, Loi S, Fox SB. Assessing Tumor-Infiltrating Lymphocytes

in Solid Tumors: A Practical Review for Pathologists and Proposal for a Standardized Method from the International Immuno-Oncology Biomarkers Working Group: Part 2: TILs in Melanoma, Gastrointestinal Tract Carcinomas, Non-Small Cell Lung Carcinoma and Mesothelioma, Endometrial and Ovarian Carcinomas, Squamous Cell Carcinoma of the Head and Neck, Genitourinary Carcinomas, and Primary Brain Tumors. *Adv Anat Pathol.* 2017;24(6):311-335.

141. Zong L, Mo S, Sun Z, Lu Z, Yu S, Chen J, Xiang Y. Analysis of the immune checkpoint V-domain Ig-containing suppressor of T-cell activation (VISTA) in endometrial cancer. *Mod Pathol.* 2022;35(2):266-273.

142. Muller S, Victoria Lai W, Adusumilli PS, Desmeules P, Frosina D, Jungbluth A, Ni A, Eguchi T, Travis WD, Ladanyi M, Zauderer MG, Sauter JL. V-domain Ig-containing suppressor of T-cell activation (VISTA), a potentially targetable immune checkpoint molecule, is highly expressed in epithelioid malignant pleural mesothelioma. *Mod Pathol.* 2020;33(2):303-311.

143. Saleh R, Taha RZ, Toor SM, Sasidharan Nair V, Murshed K, Khawar M, Al-Dhaheeri M, Petkar MA, Abu Nada M, Elkord E. Expression of immune checkpoints and T cell exhaustion markers in early and advanced stages of colorectal cancer. *Cancer Immunol Immunother.* 2020;69(10):1989-1999.

144. Terenziani R, Zoppi S, Fumarola C, Alfieri R, Bonelli M. Immunotherapeutic Approaches in Malignant Pleural Mesothelioma. *Cancers (Basel).* 2021;13(11).

145. Hung YP. Neuroendocrine Tumors of the Lung: Updates and Diagnostic Pitfalls. *Surg Pathol Clin.* 2019;12(4):1055-1071.

146. Röcken C. Predictive biomarkers in gastric cancer. *J Cancer Res Clin Oncol.* 2023;149(1):467-481.

147. Wang Y, Zhang H, Liu C, Wang Z, Wu W, Zhang N, Zhang L, Hu J, Luo P, Zhang J, Liu Z, Peng Y, Liu Z, Tang L, Cheng Q. Immune checkpoint modulators in cancer immunotherapy: recent advances and emerging concepts. *J Hematol Oncol.* 2022;15(1):111.

148. Yuan L, Tatineni J, Mahoney KM, Freeman GJ. VISTA: A Mediator of Quiescence and a Promising Target in Cancer Immunotherapy. *Trends Immunol.* 2021;42(3):209-227.

149. Rittig SM, Lutz MS, Clar KL, Zhou Y, Kropp KN, Koch A, Hartkopf AD, Hinterleitner M, Zender L, Salih HR, Maurer S, Hinterleitner C. Controversial Role of the Immune Checkpoint OX40L Expression on Platelets in Breast Cancer Progression. *Front Oncol.* 2022;12:917834.
150. Fu Y, Lin Q, Zhang Z, Zhang L. Therapeutic strategies for the costimulatory molecule OX40 in T-cell-mediated immunity. *Acta Pharm Sin B.* 2020;10(3):414-433.
151. Porciuncula A, Morgado M, Gupta R, Syrigos K, Meehan R, Zacharek SJ, Frederick JP, Schalper KA. Spatial Mapping and Immunomodulatory Role of the OX40/OX40L Pathway in Human Non-Small Cell Lung Cancer. *Clin Cancer Res.* 2021;27(22):6174-6183.
152. Chen P, Wang H, Zhao L, Guo H, Zhang L, Zhang W, Sun C, Zhao S, Li W, Zhu J, Yu J, Wu C, He Y. Immune Checkpoints OX40 and OX40L in Small-Cell Lung Cancer: Predict Prognosis and Modulate Immune Microenvironment. *Front Oncol.* 2021;11:713853.
153. Chen X, Ma H, Mo S, Zhang Y, Lu Z, Yu S, Chen J. Analysis of the OX40/OX40L immunoregulatory axis combined with alternative immune checkpoint molecules in pancreatic ductal adenocarcinoma. *Front Immunol.* 2022;13:942154.
154. Ferencz B, Megyesfalvi Z, Csende K, Fillinger J, Poór V, Lantos A, Pipek O, Sólyom-Tisza A, Rényi-Vámos F, Schelch K, Lang C, Schwendenwein A, Boettiger K, László V, Hoetzenecker K, Döme B, Berta J. Comparative expression analysis of immune-related markers in surgically resected lung neuroendocrine neoplasms. *Lung Cancer.* 2023;181:107263.
155. Nocentini G, Riccardi C. GITR: a modulator of immune response and inflammation. *Adv Exp Med Biol.* 2009;647:156-173.
156. Kraehenbuehl L, Weng CH, Eghbali S, Wolchok JD, Merghoub T. Enhancing immunotherapy in cancer by targeting emerging immunomodulatory pathways. *Nat Rev Clin Oncol.* 2022;19(1):37-50.
157. Zappasodi R, Sirard C, Li Y, Budhu S, Abu-Akeel M, Liu C, Yang X, Zhong H, Newman W, Qi J, Wong P, Schaer D, Koon H, Velcheti V, Hellmann MD, Postow MA, Callahan MK, Wolchok JD, Merghoub T. Rational design of anti-GITR-based combination immunotherapy. *Nat Med.* 2019;25(5):759-766.

158. Marin-Acevedo JA, Dholaria B, Soyano AE, Knutson KL, Chumsri S, Lou Y. Next generation of immune checkpoint therapy in cancer: new developments and challenges. *J Hematol Oncol.* 2018;11(1):39.
159. Ronchetti S, Nocentini G, Petrillo MG, Bianchini R, Sportoletti P, Bastianelli A, Ayroldi EM, Riccardi C. Glucocorticoid-Induced TNFR family Related gene (GITR) enhances dendritic cell activity. *Immunol Lett.* 2011;135(1-2):24-33.
160. Buzzatti G, Dellepiane C, Del Mastro L. New emerging targets in cancer immunotherapy: the role of GITR. *ESMO Open.* 2020;4(Suppl 3):e000738.
161. Davar D, Zappasodi R. Targeting GITR in cancer immunotherapy - there is no perfect knowledge. *Oncotarget.* 2023;14:614-621.
162. Riccardi C, Ronchetti S, Nocentini G. Glucocorticoid-induced TNFR-related gene (GITR) as a therapeutic target for immunotherapy. *Expert Opin Ther Targets.* 2018;22(9):783-797.
163. Herrera-Camacho I, Anaya-Ruiz M, Perez-Santos M, Millán-Pérez Peña L, Bandala C, Landeta G. Cancer immunotherapy using anti-TIM3/PD-1 bispecific antibody: a patent evaluation of EP3356411A1. *Expert Opin Ther Pat.* 2019;29(8):587-593.
164. Wolf Y, Anderson AC, Kuchroo VK. TIM3 comes of age as an inhibitory receptor. *Nat Rev Immunol.* 2020;20(3):173-185.
165. Zhao L, Cheng S, Fan L, Zhang B, Xu S. TIM-3: An update on immunotherapy. *Int Immunopharmacol.* 2021;99:107933.
166. He Y, Yu H, Rozeboom L, Rivard CJ, Ellison K, Dziadziuszko R, Suda K, Ren S, Wu C, Hou L, Zhou C, Hirsch FR. LAG-3 Protein Expression in Non-Small Cell Lung Cancer and Its Relationship with PD-1/PD-L1 and Tumor-Infiltrating Lymphocytes. *J Thorac Oncol.* 2017;12(5):814-823.
167. Vesterinen T, Kuopio T, Ahtiainen M, Knuutila A, Mustonen H, Salmenkivi K, Arola J, Haglund C. PD-1 and PD-L1 expression in pulmonary carcinoid tumors and their association to tumor spread. *Endocr Connect.* 2019;8(8):1168-1175.
168. Kasajima A, Ishikawa Y, Iwata A, Steiger K, Oka N, Ishida H, Sakurada A, Suzuki H, Kameya T, Konukiewitz B, Klöppel G, Okada Y, Sasano H, Weichert W. Inflammation and PD-L1 expression in pulmonary neuroendocrine tumors. *Endocr Relat Cancer.* 2018;25(3):339-350.

169. Yu H, Batenchuk C, Badzio A, Boyle TA, Czapiewski P, Chan DC, Lu X, Gao D, Ellison K, Kowalewski AA, Rivard CJ, Dziadziuszko R, Zhou C, Hussein M, Richards D, Wilks S, Monte M, Edenfield W, Goldschmidt J, Page R, Ulrich B, Waterhouse D, Close S, Jassem J, Kulig K, Hirsch FR. PD-L1 Expression by Two Complementary Diagnostic Assays and mRNA In Situ Hybridization in Small Cell Lung Cancer. *J Thorac Oncol.* 2017;12(1):110-120.
170. Martin AS, Molloy M, Ugolkov A, von Roemeling RW, Noelle RJ, Lewis LD, Johnson M, Radvanyi L, Martell RE. VISTA expression and patient selection for immune-based anticancer therapy. *Front Immunol.* 2023;14:1086102.
171. Alcalá N, Leblay N, Gabriel AAG, Mangiante L, Hervas D, Giffon T, Sertier AS, Ferrari A, Derks J, Ghantous A, Delhomme TM, Chabrier A, Cuenin C, Abedi-Ardekani B, Boland A, Olaso R, Meyer V, Altmüller J, Le Calvez-Kelm F, Durand G, Voegelé C, Boyault S, Moonen L, Lemaitre N, Lorimier P, Toffart AC, Soltermann A, Clement JH, Saenger J, Field JK, Brevet M, Blanc-Fournier C, Galateau-Salle F, Le Stang N, Russell PA, Wright G, Sozzi G, Pastorino U, Lacomme S, Vignaud JM, Hofman V, Hofman P, Brustugun OT, Lund-Iversen M, Thomas de Montpreville V, Muscarella LA, Graziano P, Popper H, Stojšić J, Deleuze JF, Herceg Z, Viari A, Nuernberg P, Pelosi G, Dingemans AMC, Milione M, Roz L, Brcic L, Volante M, Papotti MG, Caux C, Sandoval J, Hernandez-Vargas H, Brambilla E, Speel EJM, Girard N, Lantuejoul S, McKay JD, Foll M, Fernandez-Cuesta L. Integrative and comparative genomic analyses identify clinically relevant pulmonary carcinoid groups and unveil the supra-carcinoids. *Nature Communications.* 2019;10(1):3407.
172. Pelosi G, Bianchi F, Dama E, Simbolo M, Mafficini A, Sonzogni A, Pilotto S, Harari S, Papotti M, Volante M, Fontanini G, Mastracci L, Albin A, Bria E, Calabrese F, Scarpa A. Most high-grade neuroendocrine tumours of the lung are likely to secondarily develop from pre-existing carcinoids: innovative findings skipping the current pathogenesis paradigm. *Virchows Arch.* 2018;472(4):567-577.
173. Ireland AS, Micinski AM, Kastner DW, Guo B, Wait SJ, Spainhower KB, Conley CC, Chen OS, Guthrie MR, Soltero D, Qiao Y, Huang X, Tarapcsák S, Devarakonda S, Chalishazar MD, Gertz J, Moser JC, Marth G, Puri S, Witt BL, Spike BT, Oliver TG. MYC Drives Temporal Evolution of Small Cell Lung Cancer Subtypes by Reprogramming Neuroendocrine Fate. *Cancer Cell.* 2020;38(1):60-78.e12.

174. Rekhtman N. Lung neuroendocrine neoplasms: recent progress and persistent challenges. *Mod Pathol.* 2022;35(Suppl 1):36-50.

9. Bibliography of the candidate's publications

Cumulative impact factor: 49.385

9.1. List of publications that served as a basis for the current thesis

1. **Ferencz B**, Megyesfalvi Z, Csende K, Fillinger J, Poór V, Lantos A, Pipek O, Sólyom-Tisza A, Rényi-Vámos F, Schech K, Lang C, Schwendenwein A, Boettiger K, László V, Hoetzenecker K, Döme B & Berta J. Comparative expression analysis of immune-related markers in surgically resected lung neuroendocrine neoplasms *Lung Cancer* 2023 Jul;181:107263. doi: 10.1016/j.lungcan.2023.107263. **IF: 4.5**
2. **Ferencz B**, Török K, Pipek O, Fillinger J, Csende K, Lantos A, Čserneková R, Mitták M, Škarda J, Delongová P, Megyesfalvi E, Schelch K, Lang C, Solta A, Boettiger K, Brcic L, Lindenmann J, Rényi-Vámos F, Aigner C, Berta J, Megyesfalvi Z & Döme B. Expression patterns of novel immunotherapy targets in the intermediate and high-grade lung neuroendocrine neoplasms *Cancer Immunology, Immunotherapy* 2024 May 2;73(6):114. doi: 10.1007/s00262-024-03704-7. **IF: 4.6**

9.2. Other publications

2024

3. Lang C, Megyesfalvi Z, Lantos A, Oberndorfer F, Hoda MA, Solta A, **Ferencz B**, Fillinger J, Solyom-Tisza A, Querner AS, Egger F, Boettiger K, Klikovits T, Timelthaler G, Renyi-Vamos F, Aigner C, Hoetzenecker K, Laszlo V, Schelch K, Dome B. C-Myc protein expression indicates unfavorable clinical outcome in surgically resected small cell lung cancer *World Journal of Surgical Oncology* 2024 Feb 19;22(1):57. doi: 10.1186/s12957-024-03315-7. **IF: 2.5**

2023

4. Berta J, **Ferencz B**, Horváth L, Fillinger J, Lantos A, Bogos K, Rényi-Vámos F, Megyesfalvi Z, Döme B. A molekuláris altípusok szerinti heterogenitás biológiai és klinikai jelentősége kissejtes tüdőrákban [Small cell lung cancer heterogeneity and molecular subtypes: biological and clinical relevance] *Magyar Onkológia* 2023 Sep 28;67(3):181-192. Hungarian. **IF: 0**
5. Gyulai M, Megyesfalvi Z, Reiniger L, Harko T, **Ferencz B**, Karsko L, Agocs L, Fillinger J, Dome B, Szallasi Z, Moldvay J. PD-1 and PD-L1 expression in rare lung tumors *Pathology and Oncology Research* 2023 May 18;29:161-164. doi: 10.3389/pore.2023.1611164. **IF: 2.3**
6. Valko Z, Megyesfalvi Z, Schwendenwein A, Lang C, Paku S, Barany N, **Ferencz B**, Horvath-Rozsas A, Kovacs I, Schlegl E, Pozonec V, Boettiger K, Rezel M, Marko-Varga G, Renyi-Vamos F, Hoda MA, Klikovits T, Hoetzenecker K, Grusch M, Laszlo V, Dome B, Schelch K. Dual targeting of BCL-2 and MCL-1 in the presence of BAX breaks venetoclax resistance in human small cell lung cancer *British Journal of Cancer* 2023 May;128(10):1850-1861. doi: 10.1038/s41416-023-02219-9. **IF: 6.4**

2022

7. Megyesfalvi Z, Barany N, Lantos A, Valko Z, Pipek O, Lang C, Schwendenwein A, Oberndorfer F, Paku S, **Ferencz B**, Dezso K, Fillinger J, Lohinai Z, Moldvay J, Galfy G, Szeitz B, Rezeli M, Rivard C, Hirsch FR, Brcic L, Popper H, Kern I, Kovacevic M, Skarda J, Mittak M, Marko-Varga G, Bogos K, Renyi-Vamos F, Hoda MA, Klikovits T, Hoetzenecker K, Schelch K, Laszlo V, Dome B. Expression patterns and prognostic relevance of subtype-specific transcription factors in surgically resected small-cell lung cancer: an international multicenter study *Journal of Pathology* 2022 Aug;257(5):674-686. doi: 10.1002/path.5922. **IF: 7.3**
8. Lang C, Egger F, Alireza Hoda M, Saeed Querner A, **Ferencz B**, Lungu V, Szegedi R, Bogyo L, Torok K, Oberndorfer F, Klikovits T, Schwendenwein A, Boettiger K, Renyi-Vamos F, Hoetzenecker K, Schelch K, Megyesfalvi Z, Dome B. Lymphocyte-to-monocyte ratio is an independent prognostic factor in surgically treated small cell lung cancer: An international multicenter analysis *Lung Cancer* 2022 Jul;169:40-46. doi: 10.1016/j.lungcan.2022.05.010. **IF: 5.3**
9. Lang C, Lantos A, Megyesfalvi Z, Egger F, Hoda M A, Mosleh B, Klikovits T, Oberndorfer F, Timelthaler G, **Ferencz B**, Fillinger J, Schwendenwein A, Querner A S, Boettiger K, Renyi-Vamos F, Hoetzenecker K, Laszlo V, Schelch K, Dome B. Clinical and prognostic implications of CD47 and PD-L1 expression in surgically resected small-cell lung cancer *ESMO Open* 2022 Dec;7(6):100631. doi: 10.1016/j.esmoop.2022.100631. **IF: 7.3**

2021

10. Radeckzy P, Moldvay J, Fillinger J, Szeitz B, **Ferencz B**, Boettiger K, Rezeli M, Bogos K, Renyi-Vamos F, Hoetzenecker K, Hegedus B, Megyesfalvi Z, Dome B. Bone-Specific Metastasis Pattern of Advanced-Stage Lung Adenocarcinoma According to the Localization of the Primary Tumor *Pathology and Oncology Research* 2021 Sep 23;27:1609926. doi: 10.3389/pore.2021.1609926. **IF: 2.874**

11. Schwendenwein A, Megyesfalvi Z, Barany N, Valko Z, Bugyik E, Lang C, **Ferencz B**, Paku S, Lantos A, Fillinger J, Rezeli M, Marko-Varga G, Bogos K, Galffy G, Renyi-Vamos F, Hoda MA, Klepetko W, Hoetzenecker K, Laszlo V, Dome B. Molecular profiles of small cell lung cancer subtypes: therapeutic implications *Molecular Therapy Oncolytics* 2021 Feb 6;20:470-483. doi: 10.1016/j.omto.2021.02.004. **IF: 6.311**

10. Acknowledgments

I would like to express my deepest appreciation to my supervisor and mentor, Zsolt Megyesfalvi and Balázs Döme. They guided me not only throughout my PhD project but several other scientific studies as well in the past years. I hope that we can work together for many more years, and I can still count on their expertise as mentors and also friends in the future.

I could not have undertaken this journey without Judit Berta, who introduced me to the mysteries of preclinical research.

I am also grateful to Katalin Dezső and János Fillinger, they showed me the wonderful world of pathology. I deeply appreciate their invaluable patience and feedback. I sincerely hope that our journey will continue for many years in this stunning field of medicine.

Additionally, I would like to thank Professor Ferenc Rényi-Vámos, Head of the Department of Thoracic Surgery, whose support was indispensable during our research.

I would like to express my special thanks to general directors Krisztina Bogos and Professor Csaba Polgár for all that they have done for our Team.

Thanks, should also go to my colleagues from the National Korányi Institute of Pulmonology: Erzsébet Schlegl, Erzsébet Nagy, Anita Rózsás, Vivien Téglás, Lilla Horváth, Andrea Fülöp and Áron Gellért. I would also like to extend my sincere thanks to my colleagues from the National Institute of Oncology, Semmelweis University and Medical University of Vienna. Thank you for your hard work in the past years. Your dedication and relentless effort helped us reach our goals as a Team.

I cannot overlook expressing gratitude to our collaborators from all around the world and the patients who participated in our studies. Their invaluable contributions rendered our studies possible.

Finally, I would also like to express my gratitude to my whole family, without whom I would most certainly not be here today. Words cannot express how grateful I am to my wife, Anita, for all of the sacrifices she has made on my behalf. Special thanks to my son, Máté who could bring a smile to our faces, even in the most difficult moments. I owe special thanks to my parents, Erzsébet and Károly, and my brother Vince, who always supported me in every circumstance and believed in me, even when I no longer believed in myself.

Thank you all for supporting and encouraging me throughout this experience!