

SEMMELWEIS EGYETEM
DOKTORI ISKOLA

Ph.D. értekezések

3403.

KOKAS BÁLINT ANDRÁS

Viscéláris megbetegedések intervenció, sebészeti kezelése és a hasüregi
szervek transzplantációja
című program

Programvezető: Dr. Szijártó Attila, egyetemi tanár

Témavezetők: Dr. Szücs Ákos, egyetemi docens

The Role of Percutaneous Transhepatic Biliary Interventions in Optimizing Therapeutic Approaches for Biliary Obstructions and Anastomotic Leakage

PhD thesis

Bálint András Kokas, MD.

Semmelweis University Doctoral School

Surgical Medicine Division



Supervisor: Ákos Szücs, MD, PhD

Official reviewers: Dénes Balázs Horváthy, MD, PhD; Kristóf Dede, MD, PhD

Head of the Complex Examination Committee: Pál Miheller, MD, Prof.

Members of the Complex Examination Committee: Attila Doros, MD, PhD; Gábor István, MD, PhD

Budapest 2026

Table of contents

Table of contents	2
List of Abbreviations.....	5
1. Introduction	7
1.1. Literature review.....	8
1.2. Etiology of biliary strictures.....	8
1.2.1. Benign biliary strictures (BBS)	8
1.2.2. Malignant biliary stenosis (MBS).....	9
1.2.2.1. Primary Cancer.....	9
1.2.2.2. Metastatic cancers.....	10
1.3. Diagnostic methods for biliary obstructions.....	11
1.4. Therapeutic options for biliary obstructions.....	12
1.4.1. Endoscopic solutions for biliary obstructions	12
1.4.1.1. Complications.....	12
1.4.2. Interventional radiology techniques in biliary obstructions	13
1.4.2.1. Complications.....	14
1.4.3. Surgical techniques in biliary obstructions.....	14
1.4.3.1. Palliative surgery	17
1.4.3.2. Surgical complications	17
1.5. Interventions in biliary anastomosis leakage.....	18
2. Objectives	21
2.1. Evaluation of safety and effectiveness of percutaneous transhepatic drainage in biliary obstruction.....	21

2.2.	Evaluation of biliary anastomotic failure and the role of percutaneous transhepatic interventions in its treatment	22
3.	Methods	23
3.1.	Assessment of percutaneous transhepatic drainage in biliary obstructions.....	23
3.1.1.	Patient population	23
3.1.2.	Variables and definitions	24
3.1.3.	Percutaneous transhepatic drainage technique	25
3.2.	Assessment of biliary anastomotic failure.....	26
3.2.1.	Outcomes and definitions	26
3.2.2.	Statistical analysis.....	28
4.	Results	29
4.1.	Results of percutaneous transhepatic drainage in biliary obstructions.....	29
4.1.1.	Technical success and reintervention rate	29
4.1.2.	Complications.....	29
4.1.2.1.	Complications in the perihilar obstruction subgroup	30
4.1.3.	Improving results.....	33
4.2.	Results of postoperative bile leaks of biliary anastomosis and leakage treatments 36	
4.2.1.	Anastomotic failure	38
4.2.2.	Management of the biliary leakage	43
5.	Discussion.....	45
5.1.	Limitations.....	52
6.	Conclusion.....	53
7.	Summary.....	54

7.1. New scientific findings	55
8. References	56
9. Bibliography of the candidate's publications	65
10. Acknowledgements	66

List of Abbreviations

ALT – Alanine Aminotransferase

ALP – Alkaline Phosphatase

ASA – American Society of Anesthesiologists

AST – Aspartate Aminotransferase

BBS – Benign Biliary Stricture

B-C – Bismuth-Corlette

CBD – Common Bile Duct

CT – Computer Tomography

DM – Distal Malignant

ESGE – The European Society of Gastrointestinal Endoscopy

EUS-BD – Endoscopic Ultrasound-Guided Biliary Drainage

EUS-FNA – Endoscopic Ultrasound-Guided Fine Needle Aspiration

GGT – Gamma-Glutamyl Transferase

HPB – Hepato-Pancreato-Biliary

ISGLS – International Study Group of Liver Surgery

ISGPS – International Study Group of Pancreatic Surgery

MBS – Malignant Biliary Stricture

MRCP – Magnetic Resonance Cholangiopancreatography

MRI – Magnetic Resonance Imaging

OLT – Orthotopic Liver Transplantation

POPF – Post Operative Pancreatic Fistula

PM – Perihilar Malignant

PML – Perihilar Malignant with Liver Resection

PSC – Primary Sclerosing Cholangitis

PTC – Percutaneous Transhepatic Cholangiography

PTBD – Percutaneous Transhepatic Biliary Drainage

QoL – Quality of Life

SEMS – Self-expandable Metallic Stent

US – Ultrasound

1. Introduction

Biliary tract diseases, particularly obstructions and their consequences, pose major challenges for diagnosis and treatment. The treatment of biliary obstructions and anastomotic leakage requires a multidisciplinary approach, utilizing surgical, radiological, and endoscopic techniques. Therapeutic techniques may vary based on the cause of the blockages; therefore, differential diagnosis is crucial.

Biliary anastomotic leaks are serious medical conditions that affect morbidity, mortality, and quality of life. An optimal treatment plan is crucial to limit life-threatening consequences and reduce inpatient duration. The surgeon must assess potential risk factors prior to the first procedure; yet, leakage may occur despite all precautions. The therapeutic plan suited to the patient, dependent upon the primary operation, patient fitness, and accessible therapy alternatives, is implemented if leakage is apparent.

The aim of this dissertation is to evaluate the efficacy and safety of percutaneous transhepatic biliary drainage for biliary obstruction treatment, as well as to report the incidence of biliary anastomotic leakage, associated risks, and available therapeutic interventions through a retrospective analysis of two high-volume patient cohorts. The goal is to facilitate the identification of the most efficient treatment strategy for biliary anastomotic leakage and to enhance treatment quality in this complex condition.

1.1. Literature review

1.2. Etiology of biliary strictures.

Classifying the different causes of biliary strictures is a difficulty in and of itself. As the following research focuses on problems around the wall of the biliary tree, the classification will not detail gallstone disease and congenital anomalies such as biliary atresia.

1.2.1. Benign biliary strictures (BBS)

The most prevalent causes of BBS are **iatrogenic**, including cholecystectomy and orthotopic liver transplantation, not to forget partial hepatectomies or endoscopic sphincterotomy complications. Postoperative biliary strictures can be subdivided into anastomotic and nonanastomotic subtypes (1). With the evolution of minimally invasive techniques such as laparoscopic cholecystectomy, the patients could recover faster and with a lower chance of developing postoperative complications. However, complications tend to be less common but more complex, happening mainly on the biliary tree or affecting hepatic blood supply. In a large laparoscopic cholecystectomy series spanning over 10,000 patients, the reported risk of biliary injury ranges between 0.18 and 0.6% (2). The possibility of an injury may increase if the anatomy of the patient is altered (3).

Extended ischemic time during transplantation can lead to nonanastomotic and anastomotic stricture as well. There are a number of other factors that can contribute to anastomotic stricture development. Injury of the hepatic artery, excessive dissection of the hepatoduodenal ligament, anastomosis distal to the cystic duct, bile leakage, T-tube insertion, or anastomotic technique. All these factors lead to a compromised blood supply of the bile ducts, leading to a bad healing tendency, stricture, or even bile leakage (4) (5).

Inflammatory processes such as **chronic pancreatitis** can also lead to BBS in 3-46% (6). Worsening portal hypertension and bile duct proliferation can lead to secondary biliary fibrosis and strictures. Sometimes other structural changes in the pancreas (pseudocysts, acute inflammation, abscess) lead to obstruction of the intrapancreatic bile duct (6).

Primary sclerosing cholangitis is a rare autoimmune inflammatory disorder that leads to stricture formation dominantly on the extrahepatic biliary tree, usually leading to end-

stage cirrhosis. Predominantly males are affected between ages 30 and 40; frequently it is combined with inflammatory bowel disease (7). **IgG4-related sclerosing cholangitis** is one of the spectrums of sclerosing cholangiopathies that cause biliary stenosis. Clinical, laboratory, histological, and cholangiogram findings determine the diagnosis. Increased blood IgG4 levels are nonspecific yet part of the criteria for IgG4-SC. 90% of individuals have autoimmune pancreatitis, while 10% have only biliary involvement, and dacryoadenitis/sialadenitis, retroperitoneal fibrosis, and kidney lesions affect 26% of patients (8). Infection may produce biliary stricturing in recurrent pyogenic **cholangitis**. Bile stasis and intrahepatic bile duct stones induce recurrent bacterial cholangitis. Bacterial infection causes scarring, fibrosis, and stricturing (9). Xanthogranulomatous cholangitis, eosinophilic cholangiopathy, radiation, vasculitis (Wegener granulomatosis), and cystic fibrosis are other rare causes of BBS. Choledochal cysts can mimic biliary strictures on imaging and cause them through infection and stone production (10). Mirizzi syndrome is caused when a gallstone gets trapped in the neck of the gallbladder or in a long cystic duct with a low opening. This blocks the common hepatic duct (10).

1.2.2. Malignant biliary stenosis (MBS)

1.2.2.1. Primary Cancer

Unfortunately, only a small percentage of biliary strictures (15%-24%) are benign (11). **Pancreatic head adenocarcinoma** is the most common cause of malignant stricture of the distal common bile duct. It has an incidence of 10-15 per 100,000 in Europe. It is rarely curable, and the 5-year survival rate is 5%. Known risk factors are diabetes, smoking, and the presence of premalignant lesions such as pancreatic intraepithelial neoplasia, intraductal papillary mucinous neoplasia, and mucinous cystadenoma (12).

Cholangiocarcinoma is the second most frequent cause of malignant biliary stricture (13). Cholangiocyte differentiation markers are present in this epithelial cell malignancy, which develops from numerous locations within the biliary system. Intrahepatic, perihilar, and distal cholangiocarcinoma are the most recent anatomical classifications, with relative prevalences of 10%, 50%, and 40%. The mixed hepatocellular-cholangiocellular type represents less than 1% of all liver cancers. Age-adjusted rates of cholangiocarcinoma can be as high as 2.8–3.3 per 100,000. It has male predominance,

and there are several risk factors for cholangiocarcinoma, including PSC, cirrhosis, liver fluke infestations, hepatolithiasis, choledochal cysts, and hepatitis C and B infections (14).

Malignant biliary stricture can also result from advanced **gallbladder cancer**. This is the most common type of cancer of the biliary tract, usually causing perihilar obstruction in advanced stages. It shows female predominance. Known risk factors are the presence of stones in the gallbladder. Patients with larger stones (>3 cm) are at higher risk of developing invasive disease. Most of the patients are diagnosed after cholecystectomy; however, only 1% of cholecystectomy specimens contain malignant cells (15).

Ampullary cancers, a very small subtype of periampullary tumors, make up only 0.2% of all gastrointestinal malignancies. Most of them are adenocarcinomas, and recently two other subtypes have been identified: intestinal and pancreatobiliary. Notably, median overall survival for the pancreatobiliary subtype is significantly worse than that for those with intestinal histology (16 vs. 115.5 months; $p=0.001$, respectively). Ampullary cancers tend to cause distal obstructions (16).

1.2.2.2. Metastatic cancers

In most cases, primary cancers of the pancreatic head, bile duct, gallbladder, liver, and ampulla of Vater cause malignant biliary blockage. Rarer causes of biliary obstruction include metastatic tumors from other primary cancers to these organs or adjacent lymph nodes. The most prevalent primary malignancies include melanoma, lymphoma, lung, gastric, colorectal, breast, and kidney cancer (17).

1.3. Diagnostic methods for biliary obstructions

Several diagnostic tools are available for the diagnosis of biliary obstructions. A thorough physical exam, laboratory investigation, imaging, and biopsy must determine the cause of a biliary stricture. Even then, a definitive diagnosis is difficult, and many strictures' causes are unclear. The leading physical symptom is jaundice accompanied by pruritus, acholic stool, and dark urine. This is associated with hyperbilirubinemia, elevated gamma-glutamyl transferase (GGT), and alkaline phosphatase (ALP). These two enzymes are located in the biliary epithelium, as bile duct constriction results in enhanced production and secretion from biliary epithelial cells, while diminished excretion causes regurgitation into the bloodstream. Aspartate aminotransferase (AST) and alanine aminotransferase (ALT) are elevated due to hepatocyte necrosis induced by the toxic effects of jaundice. High inflammatory markers are detectable in cholangitis. The most common biomarkers for malignant obstruction are cancer antigen 19-9 (CA 19-9) and carcinoembryonic antigen (CEA), but their sensitivity and specificity are relatively low (<80%) regarding the etiology, especially if obstructive jaundice is present ((18) (19). Abdominal ultrasound (US), computed tomography (CT), and magnetic resonance imaging (MRI) with or without cholangiopancreatography (MRCP) are non-invasive imaging modalities for biliary strictures. MR-MRCP is the most sensitive non-invasive modality with sensitivity of 38%–90% and a specificity of 70%–85% in differentiating between benign and malignant strictures. Invasive imaging is fast growing beyond the more standard ERCP, endoscopic ultrasound-fine-needle aspiration (EUS-FNA), and percutaneous transhepatic cholangiography (PTC) to include cholangioscopy, intraductal ultrasound, and confocal laser endomicroscopy (20). PTC is usually not recommended as a diagnostic method if other non-invasive modalities are available. The role of PTC in diagnosis can be important where MRCP fails to detect biliary leakage or ERCP is not feasible due to anatomical alterations. It can be performed using fluoroscopic guidance alone or using both fluoroscopic and ultrasound guidance. Surgeons sometimes decide to insert a percutaneous transhepatic biliary drainage (PTBD) intraoperatively when a technically difficult biliary anastomosis is created. PTC is an easy and reproducible imaging technique helping surgeons in the postoperative period to control anastomotic leakage. It can be combined with cholangioscopy to directly visualize biliary ducts when endoscopy is not feasible (21).

1.4. Therapeutic options for biliary obstructions

1.4.1. Endoscopic solutions for biliary obstructions

If the Vater papilla is accessible by endoscopy, it is typically the primary therapy for biliary strictures.

The European Society of Gastrointestinal Endoscopy (ESGE) guideline generally recommends endoscopic drainage over PTBD in MBS. Routine preoperative biliary drainage is not recommended. In hilar obstructions, the route should be decided by a multidisciplinary team. The guideline recommends the implantation of SEMS over plastic stents for preoperative drainage, as perioperative complications seem to be lower with this technique without compromising resectability (22). EUS-BD is restricted to failed ERCP in distal obstructions and to inoperable cases with left-sided hepatic duct dilation (23).

The ESGE advocates for the temporary placement of several plastic stents or a fully covered self-expanding metal stent for the management of benign biliary strictures. A single plastic stent yields suboptimal long-term outcomes; hence, its use is not advised. Uncovered or partially covered SEMSs are challenging to extract, leading to their discontinuation in use. Typically, an increasing number of plastic stents are inserted every 3 to 4 months for a duration of 12 months (22).

1.4.1.1. Complications

Stent migration is the most frequent complication. Besides, as endoscopic sphincterotomy is used in most cases, pancreatitis, bleeding, and cholangitis are also frequent. More serious but rare complications are related to bowel perforation and subsequent peritonitis (24).

1.4.2. Interventional radiology techniques in biliary obstructions

The most common indication for a percutaneous intervention is obstructive jaundice with or without cholangitis. The place of PTBD is continuously changing in the treatment algorithm as other techniques evolve. Often it is performed in high hilar obstructions or after failed ERCP. It is also feasible when endoscopic methods are not possible due to altered anatomy (previous Roux-en-Y biliary anastomosis, enteral stent).

When MBS is planned to be treated with a curative intention, usually surgery is involved. Although routine preoperative biliary drainage is not recommended, patients with cholangitis or those with jaundice undergoing delayed surgery (staged hepatectomy, neoadjuvant chemotherapy) benefit from preoperative transhepatic biliary drainage (25), (26), (22). In unresectable cases, plastic stents are advised only with a prognosis of less than three months' survival. In other cases, self-expandable metallic stents (SEMS) (covered and uncovered) are used. For the management of early complications, 1-2 weeks of internal-external catheter can be left in place (27). In BBS uncovered metallic stents are generally not recommended; rather, retrievable metallic or plastic stents can be used. Biodegradable stents are proposed to be used in strictures refractory to standard bilioplasty. The hydrolytical degradation lasts 3-6 months, and the patient's quality of life can improve as there is no need for an invasive stent removal (27).

Balloon dilation is one of the oldest methods used in BBS in interventional radiology since its first reports in the 1970s. First, the stricture should be passed with a catheter. Then another balloon catheter with a balloon diameter as large as the proximal or distal bile duct is inflated in the middle of the stricture. Subsequently, an internal-external PTBD is left in place for 2-4 weeks. The procedure is repeated 2-4 times for better results (28). Another technique is the maintained large-bore catheter, which is placed across the stricture and subsequently upsized every 1-2 weeks until 18-20F is reached (29).

The literature indicates that there is no established method for performing PTBD. The application of ultrasonography during the initial puncture, especially of nondilated bile ducts, is debated (30). A few studies compare ultrasound-guided technique with fluoroscopy-guided drainage (31-33). The ultrasound-guided approach seems to decrease

complication rates, fluoroscopy duration, and the number of punctures; nevertheless, the success rate is not consistently superior. One study demonstrated a significantly higher technical success rate for fluoroscopic techniques in right-sided punctures (31).

The primary palliative character of the PTBD makes the improvement of quality of life (QoL) a crucial outcome metric for palliation. While it is widely believed that the alleviation of jaundice enhances quality of life, several studies indicate that it has no significant impact on it (34), (35). A main issue concerning PTBD is its inferior quality of life relative to endoscopic methods, which has led to a more restricted indication for PTBD, now limited to the draining of proximal lesions and cases following unsuccessful ERCP. In certain instances, external drainage is the sole method to ensure biliary outflow, necessitating a lifelong percutaneous drain (34).

1.4.2.1. Complications

Bleeding, biliary sepsis (cholangitis), pancreatitis, cholecystitis, and drain dislodgement are the most common complications of PTBD. External drain-specific complications are related to excess bile loss and electrolyte imbalance. Stent-specific complications are migration and restenosis (27). Small bowel perforations are extremely rare (36).

1.4.3. Surgical techniques in biliary obstructions

Regardless of the etiology, R0 resection provides the best long-term results; however, it is the most invasive solution available. The surgical trauma can be reduced with robotic or laparoscopic solutions (37).

The approach should be selected based on the etiology and the location of the obstruction. In malignant disease, the stage should influence the radicality of the operation.

In **distal malignant** obstructions, resection of the biliary tract should involve the resection of the duodenum and the head of the pancreas. The reason behind the complex resection is the common blood supply and lymphatic drainage of the region. The first 15 cm of the jejunum and the gallbladder are also resected; the pylorus can be saved in pylorus-preserving techniques or resected in Whipple surgery (Fig. 1) (38).

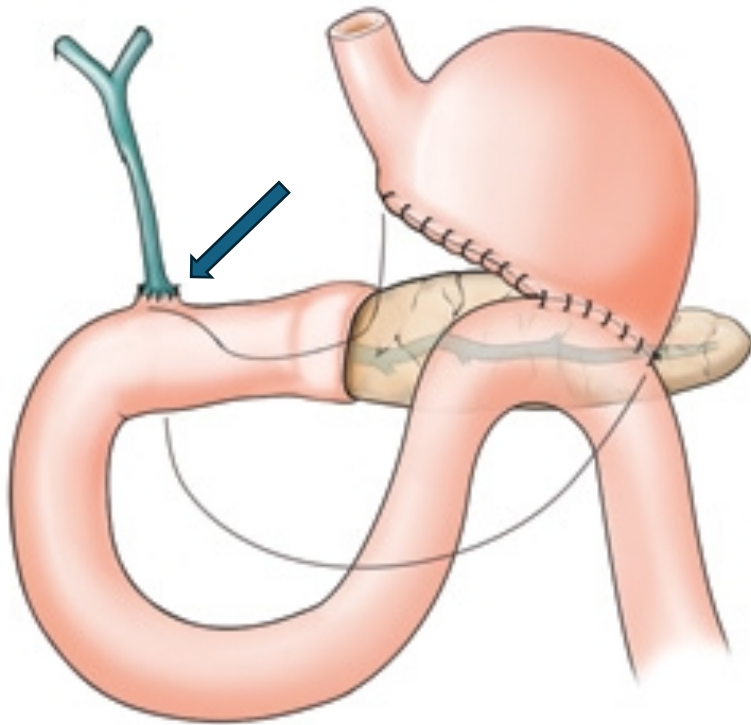


Figure 1: Reconstruction after Whipple surgery. Arrow: Roux-en-Y choledocho-jejunostomy (39).

In **perihilar malignant** obstructions, Bismuth-Corlette is the most widely used classification system, which helps to choose the surgical technique (40). Depending on the site of the obstruction, the operation may include hepatic resection (Fig. 2). Other systems like the one from American Joint Committee on Cancer or Blumgart include local (biliary and vascular) and distant tumor extent (41) (42).

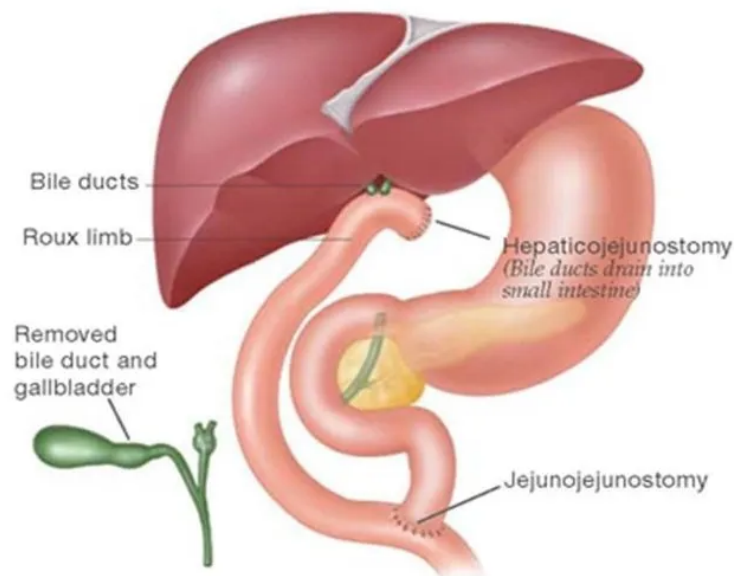


Figure 2: Reconstruction after the resection of the extrahepatic biliary duct (without liver resection) (43).

Low sensitivity and specificity of preoperative diagnostics are the reasons why the definitive decision to resect or not is often made at surgical exploration (44). In **benign** etiologies, surgical radicality is based on the location of the stricture and sometimes the presence of preoperative vascular injury. The most widely used bilioenteric anastomosis technique is the end-to-side hepaticojejunostomy with a Roux-Y loop of the jejunum. When the duodenum is not removed, hepaticoduodenostomy is a technically viable option; nevertheless, because of the elevated risk of postoperative cholangitis, this procedure has been abandoned. The recommended method is to connect various small bile ducts in the same anastomosis when the anastomosis is situated close to the common bile duct (CBD) bifurcation. This is referred to as hepatoenterostomy (4). End-to-end reconstruction of the bile duct is nowadays almost exclusively reserved for liver transplantation. Anastomotic leakage or stricture might be reduced with the use of preoperative and/or intraoperative biliary drainage. Preoperative drainage can be achieved with endoscopic stent implantation or percutaneous transhepatic biliary drain insertion. This may help reduce preoperative jaundice. PTBD can be left in place to drain the anastomosis, or it can be placed intraoperatively as well. Other widely used techniques

are T-tube (Kehr), trans-jejunal (Voelcker), and cystic drainage. The evidence of the usefulness in the prevention of postoperative bile leak of these techniques is lacking (45) (46) (47) (48).

1.4.3.1. Palliative surgery

R1 resection offers a significant survival benefit over non-resection treatment. Therefore, R1 resection is justified as efficient palliation. However, in advanced malignant disease with vascular infiltration and distant metastasis, resection is not possible. To control jaundice, biliary drainage should be used. In terms of procedure-related mortality and survival, non-operative biliary stenting is considered the first option for palliative biliary drainage because surgical drainage treatments have not been shown to be superior to non-surgical palliation. If surgical drainage is used, choledocho-duodenostomy or Roux-en-Y hepatico-jejunostomy is performed (49).

1.4.3.2. Surgical complications

Early complications may arise after surgery, like bleeding and surgical site infections or anastomotic leakage. Late complications include cholangitis and anastomosis stricture

Procedures such as pancreatoduodenectomy, bile duct resection, and surgical palliation are employed to repair the biliary tract in instances of malignant blockage. This procedure typically succeeds, although failure may result in bile leakage or peritonitis. Depending on the treatment modality, 0.4% to 33% of patients may develop biliary leakage following a hepaticojejunostomy (47)(50-53).

The successful outcome of biliary anastomosis is fundamentally reliant on vascular supply, especially that of the hepatic artery. This disorder elucidates the elevated prevalence of biliary problems in individuals with hepatic arterial thrombosis (up to 80%) or hepatic artery stenosis (up to 67%) (54). Innovative surgical techniques and enhanced postoperative management have diminished morbidity and mortality associated with hepatobiliary and pancreatic procedures. Bile leakage continues to induce surgical morbidity by extending hospitalizations, postponing abdominal drain extraction, and necessitating invasive diagnostic procedures and treatments.

The bile leakage can be managed using a variety of techniques, including percutaneous abdominal drainage, PTBD, or relaparotomy; however, the optimal treatment choice is debated (55)(56).

1.5. Interventions in biliary anastomosis leakage

Bile leakage following a bilioenteric anastomosis can be addressed in several ways. Conservative therapy is typically the initial strategy in clinical practice for individuals without biliary peritonitis; however, it may not always be enough (55)(56). The biloma can be percutaneously drained under computed tomography or ultrasound guidance to rectify biliary leakage. PTBD is capable of addressing bilioenteric anastomotic failure. A transhepatic drainage catheter is introduced into the bile ducts to access the bilioenteric anastomosis and facilitate external bile drainage (Fig. 3-4). It mitigates symptoms and averts additional consequences. Uncontrolled anastomosis dehiscence may need relaparotomy and resuturing. External biliary drainage has been investigated to avert leaking from bilioenteric anastomosis following biliary repair. External drainage can alleviate pressure on the anastomosis by redirecting bile. Nonetheless, there is a lack of information about the appropriate therapy and prevention of postoperative biliary leakage. Research assessing the efficacy of diverse therapeutic options is insufficient. This study seeks to assess the failure rate and risks associated with bilioenteric anastomosis, alongside the available therapies and their outcomes, in a high-volume tertiary referral facility with significant experience in percutaneous transhepatic drainage.

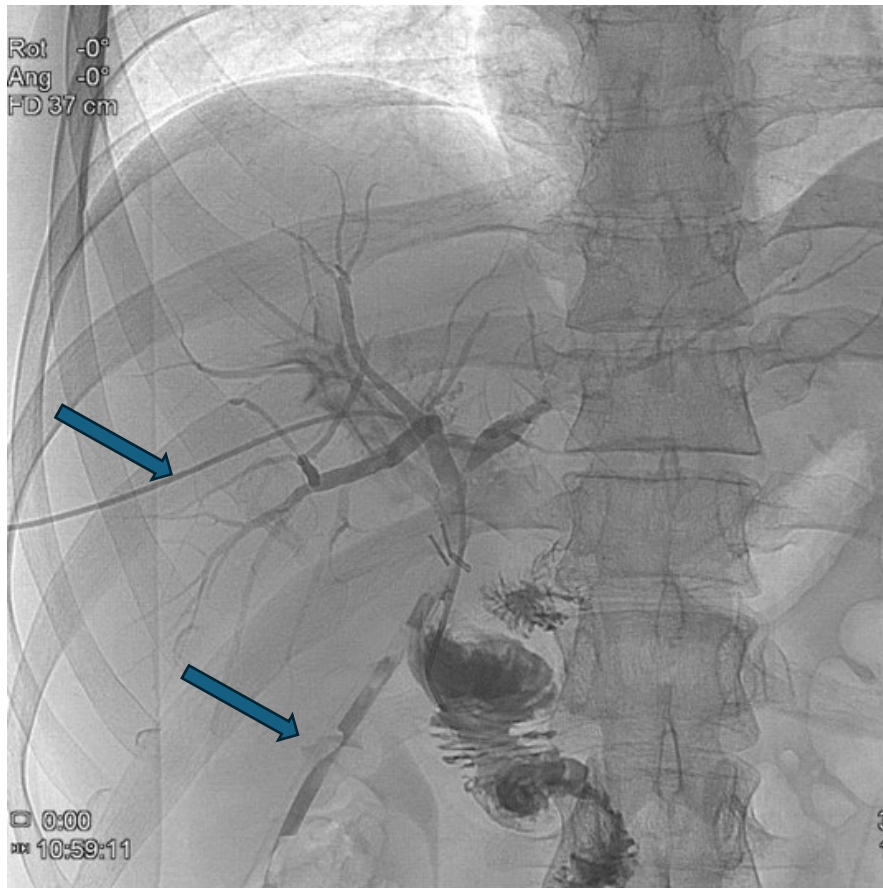


Figure 3: Percutaneous transhepatic cholangiography. Left arrow: percutaneous transhepatic catheter; right arrow: abdominal catheter draining the leakage of the hepatico-jejunostomy

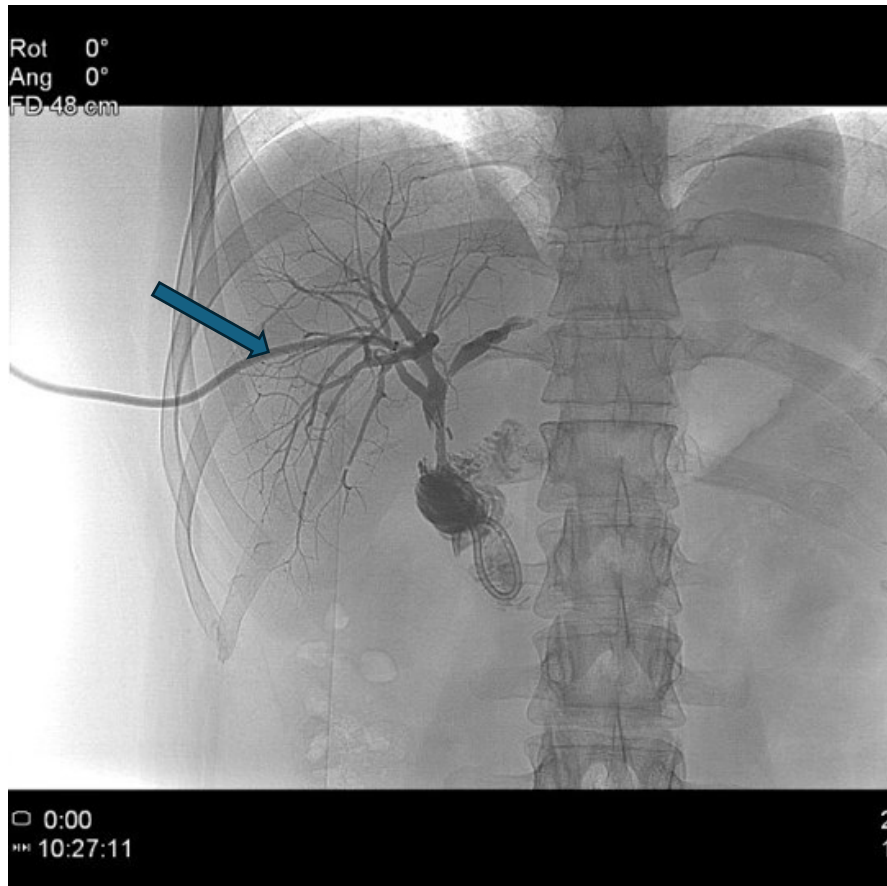


Figure 4: PTBD draining the bile towards the jejunum (arrow), no visible leakage.

2. Objectives

This thesis seeks to evaluate the efficacy, safety, and clinical outcomes of surgical and radiological interventions for the management of biliary obstructions. The purpose of the following studies is to assess the technical success rates, reintervention rates, and morbidity and mortality associated with percutaneous transhepatic drainage by conducting a comprehensive analysis of retrospective data. In addition, the thesis seeks to evaluate the prevalence and risk factors of biliary anastomosis leakage and assesses the various therapies of anastomotic failure, including PTBD and other procedures, as well as their outcomes in a tertiary referral center with a high patient volume. Considering the low-level evidence available in the treatment of biliary anastomosis failure and biliary obstructions, the ultimate objective is to give insights that help with the creation of treatment algorithms, improve patient care, and direct the selection of the most effective therapeutic approach for biliary obstructions.

2.1. Evaluation of safety and effectiveness of percutaneous transhepatic drainage in biliary obstruction

A retrospective data analysis was undertaken on the outcomes of patients with biliary obstruction treated with PTBD at our tertiary referral institution between 2007 and 2018.

Intervention results, including technical success rate, reintervention rate, and early complications, were evaluated. In addition, learning curves were analyzed based on the ratio of internal-external to external drainage, as well as the complication rates over time.

Our results were assessed in the light of international results. Accordingly, the safety and effectiveness of the method were concluded.

2.2. Evaluation of biliary anastomotic failure and the role of percutaneous transhepatic interventions in its treatment

Between 2016 and 2021, we designed a retrospective cohort research study and analyzed the outcomes of patients who had biliary anastomosis creation at our tertiary referral center. We assessed the technical and clinical efficacy of methods to stop biliary leakage.

Our results were assessed in the light of international results. Accordingly, the effectiveness of the used method was concluded.

3. Methods

3.1. Assessment of percutaneous transhepatic drainage in biliary obstructions

A retrospective data analysis was undertaken on the outcomes of patients with biliary obstruction treated with PTBD at our tertiary referral institution between 2007 and 2018. The Semmelweis University Regional and Institutional Committee of Science and Research Ethics (SE RKEB # 50/2021) accepted the project. The patient records were retrieved using Semmelweis University's electronic medical system. Due to the fact that the records were completely anonymized prior to the data analysis, the ethics commission did not seek informed consent.

3.1.1. Patient population

599 individuals with biliary obstruction had 615 percutaneous biliary procedures. The interventions were undertaken with curative and palliative aims: preoperatively in 98 patients, followed by a surgery with curative intent; postoperatively in 63 inoperable patients; and non-operatively in 436 patients who were initially diagnosed as inoperable. Radiologic data (CT, MRI) and histology were utilized to determine the source of biliary blockage. Percutaneous transhepatic cholangiography was used to determine the level of obstruction. The classification of perihilar obstructions was based on the Bismuth-Corlette classification. Distal bile duct obstruction was diagnosed between the cystic duct and the level of the pancreas; no further localization was specified in the case of postoperative local recurrence of malignancy or anastomotic benign obstruction. Table 1 details the disease etiology and stenosis localization outcomes.

Table 1: Patient population of 599 patients. n = number of patients.

Patient population	n (total=599)	%
Age (mean)	65.1 (St.dev 12.07)	-
Sex		
Male	315	53%
Female	284	47%

Disease etiology		
Pancreatic head malignancy	207	35%
Perihilar malignancy (Klatskin tumor)	183	31%
Common bile duct malignancy	20	3%
Vater papilla malignancy	16	3%
Benign biliary stricture	22	4%
Intrahepatic malignancy	15	3%
Gallbladder malignancy	44	7%
Other malignant diseases	92	15%
Localization of the stenosis		
Benign anastomotic stricture (in a previous biliodigestive anastomosis)*	5	1%
Intrahepatic	14	2%
Local recurrence of malignancy *	25	4%
Distal bile duct (below the cystic duct)	198	33%
Common bile duct	357	59%
Perihilar common bile duct stenosis: Bismuth-Corlette Classification		
Bismuth-Corlette type I	202	34%
Bismuth-Corlette type II	21	4%
Bismuth-Corlette type IIIa	20	3%
Bismuth-Corlette type IIIb	24	4%
Bismuth-Corlette type IV	90	43%
	mean:	median:
Serum bilirubin (mean)	365.4 $\mu\text{mol/l}$ St. dev. 193.6	360 $\mu\text{mol/l}$

* No further localization was defined.

3.1.2. Variables and definitions

The technical success rate, reintervention rate, incidence of early complications, and learning curves were evaluated. Technical success rate was calculated considering the primary interventions only. Scheduled reinterventions were excluded from the reintervention rate calculation. Complications were categorized into minor and major groups. The minor group corresponded to grades I-II, whereas the major group corresponded to grades III-V, according to the Clavien-Dindo classification. Pancreatitis, cholangitis, hemorrhage, hepatic abscess, biloma, and drain dislocation were among the minor problems encountered. Cholangitis was identified if systemic inflammation,

cholestasis, and biliary dilatation were present, per the diagnostic criteria for acute cholangitis established by the Tokyo Guidelines (57). On the basis of the internal-external to external drainage ratio, the learning curves of the two physicians were evaluated, with the assumption that a greater internal-external drainage % indicated a more experienced physician. The complication rates over the years were also evaluated for their learning curve.

3.1.3. Percutaneous transhepatic drainage technique

The procedures were conducted by two expert HPB surgeons certified in biliary radiological interventions. All interventions were conducted with the patient in the supine posture. After premedication with an injection of promethazine (25-50 mg), atropine (0.5-1 mg), and pethidine (50-100 mg), the patient received local anesthetic comprising 1% lidocaine at the puncture site. The initial puncture under fluoroscopic guidance was executed in the 9th–10th intercostal area on the patient's right side. If decompression of the left liver lobe was warranted, a left-sided puncture was executed in the subxiphoid region. After the Chiba needle (Cook Medical, Bloomington, IN, USA) was positioned in the bile duct, as verified by cholangiography, a 0.018-inch wire (Cook Medical) was introduced, and the needle was then withdrawn. A percutaneous access set (Cook Medical) comprising two sheaths and a metal cannula was utilized to introduce a cannula accommodating a bigger hydrophilic guidewire appropriate for the intended intervention. Subsequent to the insertion of the coaxial tip into the bile duct utilizing the hydrophilic guidewire, the two internal components were extracted, retaining the outer 4 French (F) sheath. Cholangiography was conducted to ascertain the level of occlusion. A 4F biliary manipulation catheter (Cook Medical) was employed to traverse the obstructive lesion. The hydrophilic guidewire was retained to maintain the route for security purposes. An 8.5F or 10.2F drain (Cook Medical) was ultimately retained to bridge the stricture. If bypassing the obstacle was unfeasible, an external drain was retained. The drain was sutured and secured to the skin using its original kit. When external drainage alone was retained, an intended reintervention with the possibility of catheter internalization was considered and scheduled in selected cases.

3.2. Assessment of biliary anastomotic failure

We conducted retrospective cohort research and analyzed data from patients who underwent biliary anastomosis for malignant obstruction at our tertiary referral center from 2016 to 2021. We gathered data on patient demographics, perioperative clinical and biochemical parameters, preoperative and intraoperative biliary drainage, underlying pathology, surgical procedures leading to bilioenteric anastomosis, the incidence of anastomotic failure causing bile leakage, additional radiological and surgical interventions, and clinical outcomes.

The research received approval from the Semmelweis University Regional and Institutional Committee of Science and Research Ethics (SE RKEB #25/2023). Patient records were accessed on March 13, 2023, through the computerized medical system utilized by Semmelweis University. The records were entirely anonymized during data analysis, and the ethics commission did not mandate informed consent. The authors lacked access to information that may identify individual participants during and after data collection.

3.2.1. Outcomes and definitions

The initial patient cohort comprised a variety of disease etiologies followed by operations detailed in the results section. After exclusions, patient data were evaluated collectively, and in order to mitigate inhomogeneity bias, the patients were analyzed in separate homogeneous cohorts. The three groups were defined as the following:

1. Distal Malignant (DM) group—patients with distal malignant biliary obstruction undergoing pancreatic head resection.
2. Perihilar malignant (PM) group—patients with perihilar malignant obstruction undergoing perihilar resection. Liver resection is a major trauma for the patients and can result in complex, technically more challenging biliary reconstructions that are hard to evaluate homogenously. Thus, this group only included patients without liver resection.

3. Perihilar malignant group who underwent liver resections (PML). Due to the limited sample size, the liver resection group was analyzed descriptively to highlight key clinical observations and trends without statistical comparison.

The surgeon's experience is crucial in preventing anastomotic leakage; yet, at our institution, complex HPB procedures, such as pancreatic head and perihilar resections, are consistently conducted under the oversight of a seasoned HPB surgeon. In instances where a younger individual performs the procedure, an experienced HPB surgeon supervises as the first assistant in every case.

We assessed the technical and clinical results of therapies aimed at stopping biliary leakage. Biliary leakage was detected upon the observation of bile in the postoperative drain fluid. The diagnoses were established on clinical evidence. The site of biliary leakage was identified through the analysis of data from subsequent surgical or radiological procedures. Failure of bilioenteric anastomosis was defined as the observation of bile leakage through the anastomosis. Sites of bile leakage, such as gastroenteric anastomosis, cystic duct stump, or pancreatic anastomosis, were excluded from the analysis of anastomotic failure.

Technical success was defined as a successful intervention that resulted in bile leakage controlled by a percutaneous or transabdominal drain catheter. Our percutaneous transhepatic drainage technique is described in our previous publication (58).

Conservative therapy has been defined by the cessation of leakage without the necessity for additional intervention.

Clinical success was defined as the resolution of bile leakage without the necessity for further treatments directly associated with anastomotic leakage, except for percutaneous intra-abdominal drainage.

Biliary leaks were classified from A to C by the impact of this complication on the clinical management of patients, according to the classification system described by the International Study Group of Liver Surgery (ISGLS) (59).

We investigated the correlation between anastomotic failure and multiple variables, including the ASA (American Society of Anesthesiologists) score, patient age, total bilirubin levels, preoperative cholangitis, preoperative biliary drainage, the presence of

preoperative biliary duct dilation, surgical type, intraoperative external biliary drainage, postoperative red blood cell transfusion, and postoperative pancreatic fistula (POPF). Cholangitis was identified when there was systemic inflammation, cholestasis, and biliary dilatation, as described in the Tokyo Guidelines for acute cholangitis (57). Pancreatic fistula (type A, B, or C) was defined following the guideline of the International Study Group of Pancreatic Surgery (ISGPS) (60).

3.2.2. Statistical analysis

Descriptive statistical methods were applied: for continuous variables, mean and standard deviation were calculated, while categorical variables were expressed as frequencies and percentages. Differences between groups were analyzed using the Mann–Whitney U test for continuous data, and the chi-squared test or Fisher’s exact test for categorical data (the latter in case of small sample sizes). To identify independent predictive variables, binary logistic regression with stepwise selection was applied. All analyses were performed using IBM SPSS Statistics for Windows (Version 25.0 or 28.0; IBM Corp., Armonk, NY, USA). Additional descriptive analyses and visualizations were prepared with GraphPad Prism and Microsoft Excel 2016.

4. Results

4.1. Results of percutaneous transhepatic drainage in biliary obstructions

4.1.1. Technical success and reintervention rate

The intervention was considered technically successful when an internal-external or external drain could be left in the bile ducts and the final PTC confirmed adequate biliary drainage. Thus, technical success was achieved in 94.5% (566/599) of the patients. In 33 cases, it was technically pointless to drain, as the subsegmental obstruction resulting from the advanced state of the disease could not be resolved with even multiple drainages, nevertheless they were considered as technical failures. The technical success rate was measured in the perihilar subgroup as well: 96.3% (344/357). 16 patients needed reintervention in 30 days due to complications like dislocation (n=13), drain obliteration (n=2), or hemobilia (n=1). The calculated 30-day reintervention rate for the total cohort is 2.7% (16/599).

4.1.2. Complications

Intervention-related early complications were divided into minor and major groups (Table 2). The minor complications (111/599, 18.5%) were the following: Pancreatitis—defined by the Revised Atlanta Classification—was observed in 7 (7/599, 1.2%) patients. Bleeding was registered as a complication if a red blood cell transfusion was needed. With that consideration, 5 cases of bleeding (5/599, 0.8%) were registered. Biloma and hepatic abscess were observed in 4 cases (4/599, 0.6%), which needed no surgical intervention. 71 patients (71/599, 12%) with cholangitis were registered after the intervention. 63 drain dislocations were noted. Out of these 63 complications, 39 happened within 30 days after the intervention (early dislocation), and 24 happened later than that (late dislocation). From the 39 early dislocations, 24 (24/599, 4%) were managed without intervention. In these cases, there were different disease courses that did not indicate a reintervention. Such case scenarios were repositioning managed without true radiological intervention, internal-external drain dislocated to external position, resolution of cholangitis and dilated bile ducts, disease progression, or other organ failure.

Major complications were observed in 22 (22/599, 3.6%) cases. In 1 (1/599, 0.17%) case, bile duct perforation with intraabdominal drain dislocation and bile leakage resulted in peritonitis and required an operation. In 4 cases (4/599, 0.6%), other etiologies (pancreatitis with necrosis, hepatic abscess, and intra-abdominal bleeding in two cases) required surgical laparotomy; in 15 (15/599, 0.25%) cases, drain dislocation or obliteration; and in 1 (1/599, 0.17%) case, hemobilia was managed with reintervention.

In 1 case, PTBD-related small bowel perforation resulted in biliary peritonitis, reoperation, and death. The intervention-related mortality is 0.17% (1/599).

Table 2: Minor and major complications after percutaneous intervention in 599 patients.

Minor complications (Clavien Dindo I-II)	n	%
Bleeding (transfusion needed)	5	0.8
Cholangitis (after the PTBD)	71	12
Early dislocation (managed without intervention)	24	4
Pancreatitis	7	1.2
Intraabdominal abscess	3	0.5
Intraabdominal biloma	1	0.17
Total	111	18.5
Major complications (Clavien Dindo III-V)	n	%
Perforation	1	0.17
Bleeding (2 managed with reoperation, 1 with reintervention)	3	0.005
Pancreatitis	1	0.17
Early dislocation and obliteration (managed with reintervention)	15	0.25
Intraabdominal abscess	1	0.17
Death	1	0.17
Total	22	3.6

n = number of patients

4.1.2.1. Complications in the perihilar obstruction subgroup

In this subgroup, we assessed the obstructions classified by B-C, mentioned in Table 1. In total, 357 perihilar obstructions were found. Percutaneous intervention was performed after failed ERCP in 214 (214/357, 59%) patients, and 143 (143/214, 41%) PTBD without

ERCP were done in the mentioned subgroup. Failed ERCP included unsuccessful stent implantation or ineffective drainage. All endoscopic interventions were performed in other institutes. Complication data of percutaneous intervention alone (hilar PTBD) and ERCP followed by percutaneous intervention (hilar ERCP+PTBD) were analyzed and compared in the hilar obstruction subgroup. 30 (30/143, 21%) minor and 8 (8/143, 6%) major complications were observed in the hilar PTBD group, and 39 (39/214, 18%) minor and 12 (12/214, 6%) major complications were found in the hilar ERCP+PTBD group (Table 3). The difference between the two groups (hilar ERCP+PTBD vs. hilar PTBD) was statistically not significant ($p=0.557$) regarding the total number of complications. We analyzed cholangitis separately as well, as it was the complication with the highest numbers in both subgroups. The other complications were not compared statistically by type because of the low number of events. In the hilar PTBD group, 15 (15/143, 10.5%) cases of cholangitis were observed before and 23 (23/143, 16%) after the intervention. Nevertheless, in the hilar ERCP+PTBD group, 39 (39/214, 18.2%) cases were observed before the percutaneous drainage (between the ERCP and PTBD) and 25 (25/214, 11.6%) after the percutaneous drainage. The number of cholangitis cases observed before the intervention in the hilar ERCP+PTBD subgroup was significantly higher than in the other group ($p=0.046$) (Fig. 5). The numbers of cholangitis observed after the intervention were not statistically different in the subgroups ($p=0.232$).

Table 3: Minor and major complications in the hilar PTBD group of 143 patients and the hilar ERCP+PTBD group of 214 patients.

Minor complications (Clavien-Dindo I-II)	n (%) – hilar ERCP+PTBD	n (%) – hilar PTBD group	p
Bleeding	4 (2)	0	0.232
Biloma	1 (0.5)	0	
Intraabdominal abscess	1 (0.5)	1 (0.7)	
Cholangitis (after the PTBD)	25 (12)	23 (16)	
Early dislocation (managed without intervention)	8 (4)	1 (0.7)	
Pancreatitis	0	5 (3.5)	
Total	39 (18)	30 (21)	
Major complications (Clavien-Dindo III-V)	n (%) – hilar ERCP+PTBD group	n (%) – hilar PTBD group	p
Perforation	1 (0.5)	0	0.996
Bleeding (managed with reintervention or reoperation)	2 (0.1)	0	
Pancreatitis	0	1 (0.7)	
Early dislocation and obliteration (managed with reintervention)	9 (4)	6 (4)	
Intraabdominal abscess	0	1 (0.7)	
Total	12 (6)	8 (6)	
Major and minor complications	n (%) – hilar ERCP+PTBD group	n (%) – hilar PTBD group	p
Total	51 (24)	38 (27)	0.557

n = number of patients

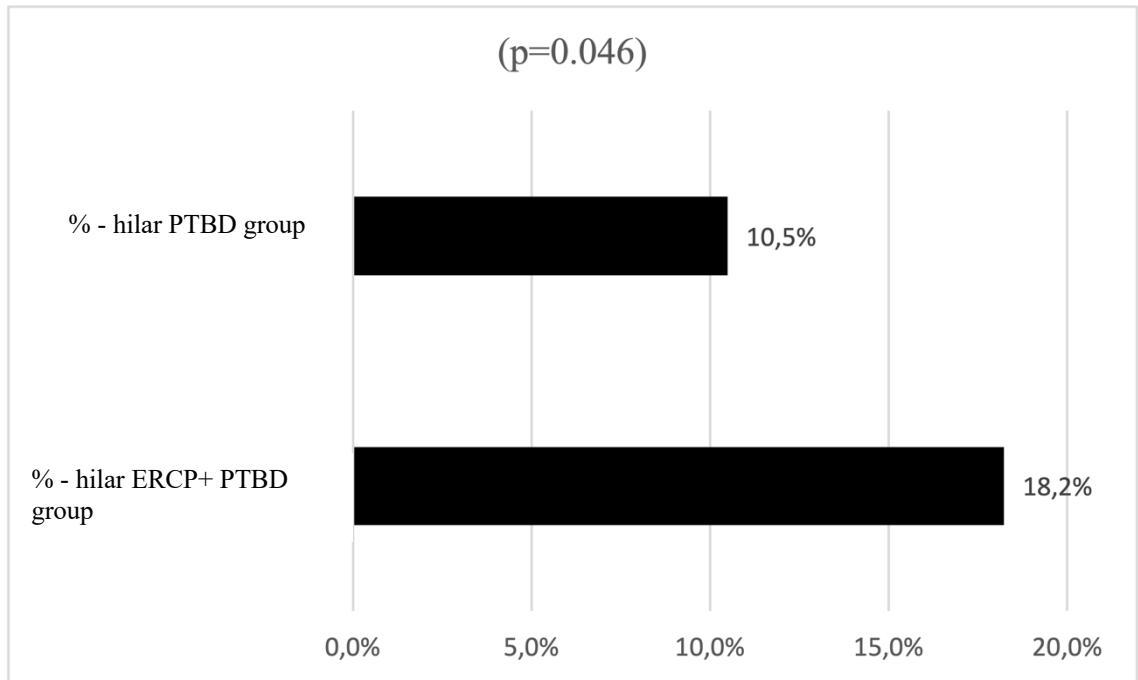


Figure 5: Cholangitis in the hilar PTBD group of 143 patients and the hilar ERCP+PTBD group of 214 patients before the PTBD intervention. Statistically significant difference. $p=0.046$

4.1.3. Improving results

All interventions were performed by two physicians who were getting more and more experienced through the years. This allowed us to try to measure their improvement with a learning curve. We analyzed the success rates of the percutaneous interventions on an annual basis. External decompression and internal-external decompression were differentiated and counted for every single year in the investigated period. Internal-external decompression was considered the best experience, being superior to the external method. An annual increase was observed in the number of internal-external drainages as a result of the physicians getting more and more experienced (Fig. 6). After 203 PTBDs, the rate of internal-external/external drainage ratio stabilized above 1.

Yearly complication rates were also calculated. A higher peak point has been found during the early years and a decreasing complication rate over the years. This peak corresponds to the early courage of the less experienced interventionists, which decreased

with rising experience (Fig. 7). Although this does not precisely follow the learning curve on the other figure, a major decrease can be observed in the number of complications, approximately between the years 2011 and 2012 (X-axis), where the internal-external/external ratio stabilized above 1.

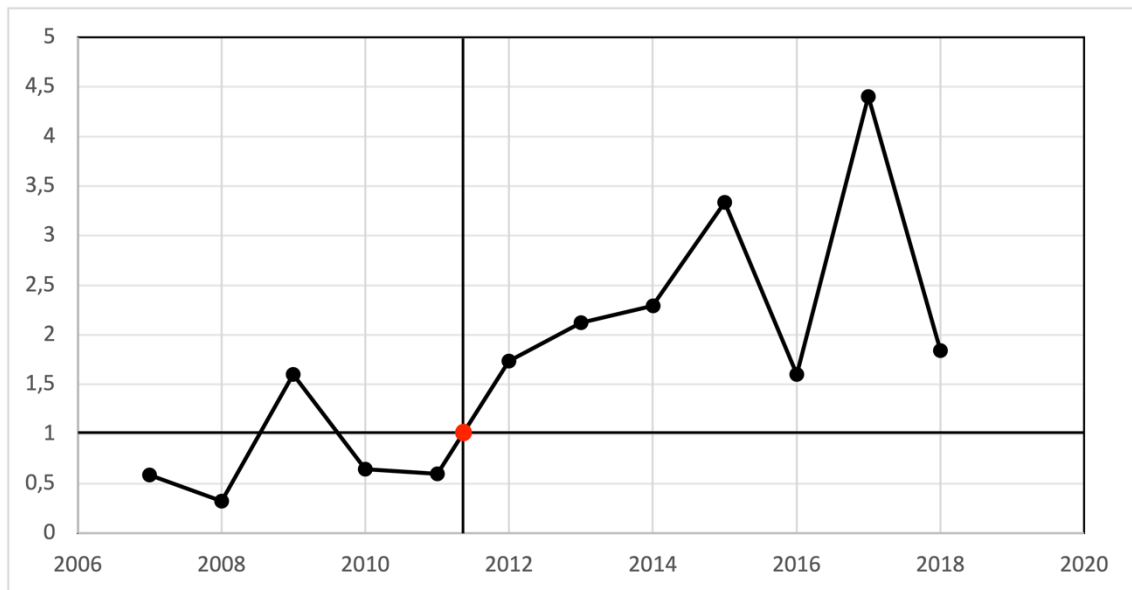


Figure 6: X axis - years; Y axis - internal-external/external drainage ratio. X axis—years. The red dot shows the point where the ratio stabilized above 1 (203 PTBDs).

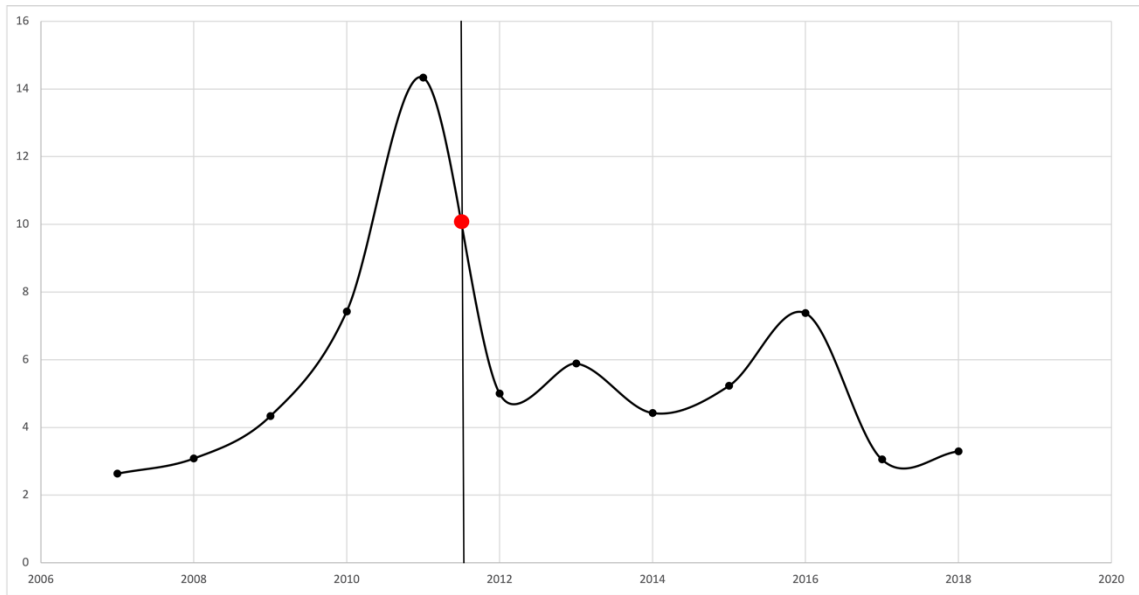


Figure 7: X axis—years, Y axis—total number of interventions/total number of complications ratio. The red dot shows the point where, between 2011 and 2012, the internal-external/external ratio stabilized above 1 and the complications started to decrease

4.2. Results of postoperative bile leaks of biliary anastomosis and leakage treatments

The initial cohort comprised 724 patients who underwent bilioenteric anastomosis for various underlying conditions. After excluding benign etiologies, the analysis focused on 451 patients with malignant pathology. These were further stratified into three homogeneous cohorts: the DM group (410 patients), the PM group (41 patients), and the PML group (9 patients) (Fig. 8). PM and DM baseline characteristics are presented in Table 4.

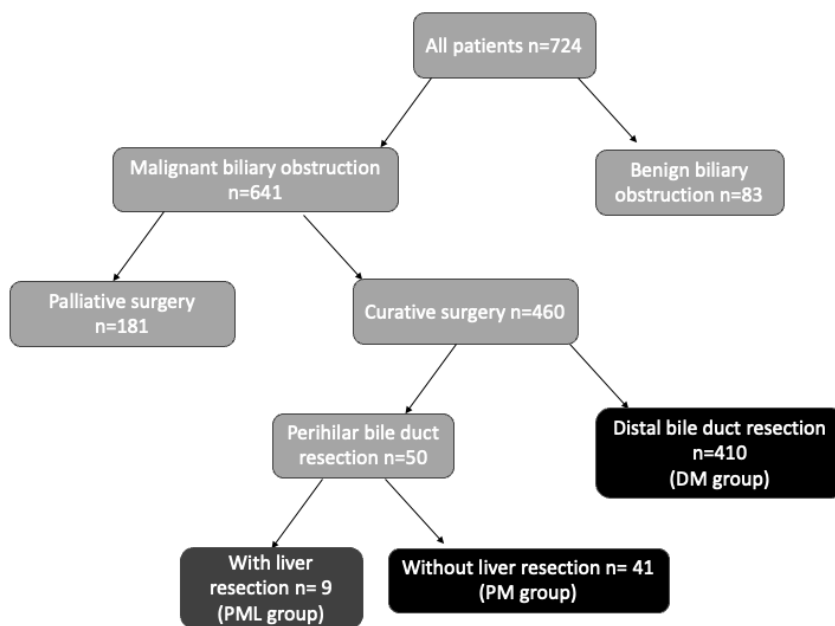


Figure 8: Patient exclusion flowchart

Table 4: Baseline characteristics of the second study group

Baseline characteristic	Total	DM	PM
Male sex, n (%)	223 (49%)	202 (49%)	26 (63%)
Age in years, mean (SD)	67.6 (11.07)	67 (11)	71 (12)
ASA score n, %			
I	3 (0.7%)	3 (0.9%)	0
II	229 (51%)	215 (68%)	14 (34%)
III	219 (49%)	192 (60%)	27 (65%)
IV	0	0	0
Bilirubin, pre-operative $\mu\text{mol/L}$, mean (SD)	40.77 (74.78)	37.35 (70.5)	74.76 (101.84)
Preoperative endoscopic stent, n (%)	229 (50%)	199 (49%)	30 (73%)
Preoperative PTBD, n (%)	24 (5%)	19 (5%)	5 (12%)
Not present or removed during surgery, n (%)	5 (20%)	5 (26%)	0
Not removed during surgery, n (%)	19 (79%)	14 (74%)	5 (100%)
External biliary drainage n, (%)	29 (6%)	16 (4%)	13 (31%)
Intraoperative PTBD placed during surgery	2 (6%)	0	2 (15%)
PTBD placed before surgery and left in place	19 (66%)	14 (87%)	5 (38%)
Transjejunal drainage	8 (28%)	2 (13%)	6 (46%)
Disease etiology n, (%)			
Pancreatic head cancer	318 (71%)	318 (78%)	0
Periampullary tumor	78 (17%)	78 (19%)	0
Perihilar cholangiocarcinoma (B-C 1-2)	35 (8%)	0	35 (85%)
Distal cholangiocarcinoma	14 (3%)	14 (3%)	0
Gallbladder carcinoma	6 (1%)	0	6 (15%)
Days between anastomosis formation and diagnosis of leakage, mean (SD)	5.3 (4.8)	5.4 (4.99)	5.1 (3)

(DM=Distal malignant group, PM=perihilar malignant group, B-C= Bismuth-Corlette, SD=standard deviation)

The overall mortality rate among all patients was 3.99%: 24% (7/29) in patients with anastomotic failure and 3% (11/422) in patients without anastomotic failure. ($p < 0.0001$)

In the DM group, mortality was 3.9%, significantly ($p < 0.0001$) higher in patients with anastomotic failure (26% [6/23]) vs. without failure (2.6% [10/387]).

In the PM group, mortality was 4.9% (2/41). 1 death happened with anastomotic failure (16.7%, 1/6) and 1 without (2.9%, 1/35); the difference was not significant.

4.2.1. Anastomotic failure

All patients' leak rate was 6.4% (29/451). The leak rate in the DM group was 5.6% (23/410); in the PM group, it was 14.6% (6/41), which difference was significant (p=0.038).

ASA score, age, total bilirubin levels, preoperative cholangitis, preoperative biliary drainage, bile duct dilatation, surgery type, intraoperative external biliary drainage, postoperative red blood cell transfusion, and POPF were examined in association with biliary failure and leakage. We found no non-dilated bile ducts in the PM group.

Although the leak rate appeared to be higher in patients with advanced comorbidities (ASA III), the differences across ASA categories were not statistically significant in either group. Biliary leakage had a greater prevalence across all potential risk factors analyzed; however, the differences did not demonstrate any statistically significant connections with leak rates in either group (Table 5).

The surgeon's experience in relation to the leakage rate was also analyzed. A less experienced surgeon refers to one whose surgical board examination was completed less than 10 years ago, whereas an experienced surgeon is defined as one whose surgical board examination was completed 10 years ago or more.

We found no significant difference regarding leak rates in DM and PM groups between less and more experienced surgeons (Table 7).

Table 5: Univariate analysis of factors in association with biliary failure and leakage.

Factor examined	number of patients (n)	leakage (n)	%	p
All patients - ASA I-II	232	11	4.74%	0.178
All patients - ASA III	219	18	8.22%	
DM group - ASA I-II	218	11	47.8%	0.597
DM group - ASA III	192	12	52.2%	
PM group - ASA II	14	0	0.0%	

PM group - ASA III	27	6	100.0%	0.079
All patients - Cholangitis	24	3	12.5%	0.194
All patients - No Cholangitis	427	26	6.09%	
DM group - Cholangitis	19	1	5.26%	1
DM group - No Cholangitis	391	22	5.63%	
PM group - Cholangitis	5	2	40%	0.148
PM group - No Cholangitis	36	4	11.11%	
All patients - Preoperative biliary drainage used	253	14	5.53%	0.441
All patients - No preoperative biliary drainage used	198	15	7.58%	
DM group - Preoperative biliary drainage used	218	9	4.1%	0.165
DM group - No preoperative biliary drainage used	192	14	7.3%	
PM group - Preoperative biliary drainage used	35	5	14.3%	>0.999
PM group - No preoperative biliary drainage used	6	1	16.7%	
DM group - Dilated bile duct	262	12	4.58%	0.265
DM group - Non dilated bile duct	148	11	7.43%	
All patients - External biliary drainage used	29	3	10.34%	0.42
All patients - No external biliary drainage used	422	26	6.16%	
DM group - External biliary drainage used	16	1	6.3%	0.61
DM group - No external biliary drainage used	394	22	5.6%	
PM group - External biliary drainage used	13	2	15.4%	>0.999
PM group - No external biliary drainage used	28	4	14.3%	
All patients - Postoperative red blood cell transfusion	93	10	10.75%	
All patients - No postoperative red blood cell transfusion	358	19	5.31%	

DM group - Postoperative red blood cell transfusion	87	8	9.2%	0.093
DM group - No postoperative red blood cell transfusion	323	15	4.64%	
PM group - Postoperative red blood cell transfusion	6	2	33.33%	0.116
PM group - No postoperative red blood cell transfusion	35	4	11.43%	
				0.206
DM group - Postoperative pancreatic fistula	35	4	11.43%	
DM group - No postoperative pancreatic fistula	375	19	5.07%	
				0.122
Age	mean	St. Dev	-	
All patients without leakage	67.74	10.011		
All patients with leakage	65.52	11.8111		
				0.331
DM group without leakage	67.39	11.088		
DM group with leakage	64.74	12.622		
				0.238
PM group without leakage	71.62	9.33		
PM group with leakage	68.55	7.44		
				0.237
Total bilirubin	mean (μmol/L)	St. Dev	-	
All patients without leakage	38.51	72.24		
All patients with leakage	73.50	101.03		
				0.077
DM group without leakage	36.49	70.17		
DM group with leakage	51.73	77.49		
				0.263
PM group without leakage	60.68	88.93		
PM group with leakage	156.95	129.73		
				0.080

(DM=Distal malignant group, PM=perihilar malignant group, St. Dev=standard deviation)

Multivariate analysis did not find any statistically significant protective or risk factors in relation to anastomosis leakage in either group (Table 6).

Table 6: Multivariate analysis of factors in association with biliary failure and leakage.

Variable	N	Cases	OR ₁	95% CI ₁	p-value
Variable	449	29	0.978	0.946, 1.01	0.191
Age	449	29			
Male	223	14	1.00	—	
No	226	15	0.967	0.427, 2.19	0.935
Yes	449	29			
ASA Class	230	11	1.00	—	
I-II	219	18	1.84	0.790, 4.49	0.165
III	449	29	1.00	0.999, 1.01	0.097
Preop total bilirubin	449	29			
Preop biliary drainage	197	15	1.00	—	
No	252	14	0.619	0.262, 1.42	0.260
Yes	449	29			
Preop Cholangitis	425	26	1.00	—	
No	24	3	1.55	0.312, 5.76	0.547
Yes	449	29			
External biliary drainage	420	26	1.00	—	
No	29	3	1.240	0.232, 4.90	0.781
Yes	449	29			
Transfusion	358	19	1.00	—	
No	91	10	1.80	0.735, 4.15	0.177
Yes					

1 OR = Odds Ratio, CI = Confidence Interval. Null deviance = 177; Null df = 407; Log-likelihood = -84.1; AIC = 188; BIC = 228; Deviance = 168; Residual df = 398; No. Obs. = 408

Table 7: Surgeon's experience in relation to the leakage rate

Total (DM+PM groups)	Operations (n)	Leak (n)	%	p
Less experienced	164	10	6%	0.986
Experienced	287	19	7%	
DM group	Operations (n)	Leak (n)	%	p
Less experienced	155	9	6%	1
Experienced	255	14	5%	
PM group	Operations (n)	Leak (n)	%	p
Less experienced	9	1	11%	1
Experienced	32	5	16%	

(DM=Distal malignant group, PM=perihilar malignant group)

We also performed descriptive analysis on the perihilar subgroup who underwent liver resections (Table 8). In this group, 9 patients were found. In this group mortality was 0%; the leak rate was 44% (4/9).

Table 8: Data analysis on the perihilar subgroup who underwent liver resections

Factor examined	number of patients (n)	leakage (n)	%
PML group - ASA II	5	1	20%
PML group - ASA III	4	3	75%
PML group - Cholangitis	2	1	50%
PML group - No Cholangitis	7	3	43%
PML group - Preoperative biliary drainage used	6	3	50%
PML group - No preoperative biliary drainage used	3	1	33%
PML group - Dilated bile duct	8	3	38%
PML group - Non dilated bile duct	1	1	100%

PML group - External biliary drainage used	8	4	50%
PML group - No external biliary drainage used	1	0	0%
PML group - Postoperative red blood cell transfusion	5	3	60%
PML group - No postoperative red blood cell transfusion	4	1	25%
Age	mean	St. Dev	-
PML group without leakage	57	20.08	
PML group with leakage	63.50	12.76	
Total bilirubin	mean ($\mu\text{mol/L}$)	St. Dev	-
PML group without leakage	246.06	144.01	
PML group with leakage	138.5	138.12	

(PML=perihilar malignant group with liver resection)

4.2.2. Management of the biliary leakage

Biliary leakage was managed using various approaches depending on the severity.

In the DM group, the prevalence of biliary leakage was 5% (23/410) among the patients; in 7 cases, conservative treatment was successful. A total of 16 patients needed intervention (3.9%, 16/410). The failed primary intervention was followed by repeat interventions in 6 cases, for a total of 22 interventions.

In the PM group, the prevalence of biliary leakage was 14.6% (6/41) among the patients; in 2 cases, conservative treatment was successful. A total of 4 patients needed intervention (9.7%, 4/41). The failed primary intervention was followed by repeat interventions in 3 cases, for a total of 7 interventions.

According to the classification proposed by the International Study Group of Liver Surgery, Grade B leaks received minimally invasive intervention, and Grade C leaks underwent relaparotomy (59). Grade C cases were further divided into two subgroups: laparotomy with (Grade C-2) or without intraoperative biliary drainage (Grade C-1).

The results of all groups and subgroups are detailed in Table 9.

Table 9: Results of interventions used to treat biliary leakage.

DM group	Total (n)	Technical success (n; %)	Clinical success (n; %)
Grade B	1	1; 100%	0;0%
PTBD	1	1; 100%	0;0%
Grade C	21	16;76.2%	12;57.1%
Grade C-1	10	8;80%	5;50%
Grade C-2	11	8;72.7%	7;63.6%
Laparotomy + PTBD	3	2;67%	2;67%
Laparotomy + T-Tube	5	3;60%	2;40%
Laparotomy + Transjejunal drain	3	3;100%	3;100%
PM group			
Grade B	2	1;50%	1;50%
PTBD	2	1;50%	1;50%
Grade C	5	4;80%	4;80%
Grade C-1	0		
Grade C-2	5	3;60%	3;60%
Laparotomy + PTBD	2	1;50%	1;50%
Laparotomy + T-Tube	1	1;100%	1;100%
Laparotomy + Transjejunal drain	2	1;50%	1;50%
PML group			
Grade B	0		
PTBD	2	2, 100%	1, 50%
Grade C	1	1, 100%	0, 0%
Grade C-1	1	1, 100%	0, 0%
Grade C-2	0		
Laparotomy + PTBD	0		
Laparotomy + T-Tube	0		
Laparotomy + Transjejunal drain	2	2, 100%	2, 100%
All patients			
Grade B	3	2;67%	1;33%
Grade C	27	21; 77%	16;52.2%
Grade C-1	11	9;81%	5;45.4%
Grade C-2	16	11;68%	10;62.5%

5. Discussion

Obstructive jaundice elevates the risk of morbidity and mortality due to many pathophysiological alterations (61). Depending on the disease etiology, palliative or curative treatment can be offered to the patients. In localized malignant obstruction, surgical resection is usually part of the curative treatment algorithm. Depending on the severity of the jaundice, primary resection or preoperative biliary drainage can be offered. Routine preoperative drainage is not advised; nonetheless, the specific criteria indicating the necessity for drainage lack robust evidential support (22)(62)(63). Whether to use endoscopic or percutaneous transhepatic access for biliary drainage is dependent upon anatomical and several other factors.

Percutaneous transhepatic biliary drainage is a widely used interventional method to relieve mechanical jaundice regardless of the localization of the obstruction. This technique is essential when endoscopic access has failed or is unfeasible due to altered anatomical conditions following Roux-en-Y anastomosis. And it is also a viable option in the treatment of biliary anastomosis leakage.

The research comparing endoscopic and percutaneous techniques and results of percutaneous interventions after failed endoscopy is controversial (64) (65) (66). More data is revealing the superiority of endoscopic ultrasound-guided biliary drainage (EUS-BD) over other techniques; however, this technique is still not widely available. On the other hand, EUS-BD is recommended after failed ERCP, mostly in distal obstructions and in inoperable hilar obstruction with left hepatic duct dilation (67).

Besides, it is extremely difficult to conduct a randomized clinical trial to compare treatment options for biliary anastomotic leakage; the existing research methods for this topic are insufficient. To address this methodological and knowledge gap, more empirical data analysis is the most efficient method to reinforce and validate existing findings. Thus, we decided to conduct our retrospective data analysis on these topics.

In our first study, we designed a single-center cohort with one of the largest patient populations to evaluate the outcomes of percutaneous transhepatic biliary drainage. In our second study, we conducted an analysis on one of the largest patient cohorts undergoing biliary anastomosis and studied anastomosis leak rates in malignant biliary obstruction

and highlighted the role of PTBD in the development of primary anastomosis or addressing anastomotic leakage.

We found high bilirubin levels in both cohorts, indicating an advanced stage of their disease and low compensatory capability, similar to the study populations in papers published by Sut et al. (median serum bilirubin 397 $\mu\text{mol/L}$) or Robson et al. (median serum bilirubin 201 $\mu\text{mol/L}$) (34)(68).

High ASA scores in the second cohort also suggest advanced disease stage, several comorbidities, and increased risks of postoperative complications. Low performance status can lead to biliary anastomotic failure. This tendency is visible in PM, PML, and DM groups, but it is statistically not significant due to the low number of events.

High bilirubin contributes to low performance status; thus, in case of operable biliary malignancy, preoperative biliary drainage logically can be considered. As it was mentioned before, routine drainage is dubious, as PTBD, an invasive intervention, can cause numerous complications that may offset its therapeutic effect. We analyzed mortality and the most common complications of PTBD. In the first study population, only one patient suffered a lethal complication (0.17%), and only 4% (22/599) of the cases were diagnosed with major complications, which is favorable. After percutaneous interventions, Robson et al. reported 2%, while Mueller et al. reported 0.015% of the interventions resulting in death.

Bowel perforations associated with interventions have serious, although infrequent, consequences; hence, limited research addresses this occurrence. In the largest study documenting perforation following percutaneous intervention, just one perforation was recorded among 261 patients. We recorded only 1 instance (0.17%) of this undesirable occurrence.

Bleeding around percutaneous transhepatic drainage is a recognized complication due to the anatomical positioning of the intraparenchymal blood vessels. Nennstiel et al. reported a 7.7% incidence of bleeding problems following PTBD, with only 1 out of 252 patients classified as a serious adverse event (31). Rivera-Sanfeliz et al. documented a greater incidence (8/346) necessitating intervention to halt the hemorrhage (69). Our findings revealed two significant hemorrhages.

Our study group identified one case of severe post-PTBD pancreatitis, representing 0.17% of the first cohort. Andriulli et al. identified a 3.47% incidence of post-ERCP pancreatitis among 16,855 participants in their study. Pancreatic damage was mild in 44.8% and moderate in 43.8%; it was severe in 11.4% of all patients with post-ERCP pancreatitis, constituting 0.40% of all examined patients (70). Research evaluating ultrasound versus fluoroscopy-guided percutaneous transhepatic drainage in 195 patients indicated no instances of pancreatitis following the procedure (31). A separate meta-analysis regarding preoperative biliary drainage in hilar cholangiocarcinoma indicated that the overall incidence of pancreatitis in the endoscopic biliary drainage cohort was 11.9% (21/157), but no cases were reported in the PTBD group (71). This demonstrates a distinct advantage of PTBD over the endoscopic approach concerning post-interventional pancreatitis.

Drain dislocation is a prevalent adverse occurrence, as indicated by our data. Table 2-3 indicates that it possesses the second greatest frequency of both major and minor adverse effects. Migration of ERCP stents is a similarly concerning consequence that may result in bowel perforation. A meta-analysis comparing percutaneous and endoscopic biliary drainage revealed total incidence rates of dislocation at 7.7% (12/156) and 18.1% (32/177), respectively. Our overall dislocation rate was 11% (63 out of 599).

Our data indicates that cholangitis and drain dislodgement are the two predominant adverse events following percutaneous drainage, consistent with findings reported by Nennstiel et al. and Asadi et al (72)(73).

A significant percentage (60%) of our patients had PTBD only following unsuccessful endoscopy. This indicates prevailing practice, as the majority of patients are referred to PTBD with an endoscopic stent in place or following unsuccessful ERCP (13)(74). Elevated pre-interventional cholangitis rates suggest potential complications from prior endoscopic procedures and prompt a study into whether ERCP or PTBD should be the preferred treatment for obstructive jaundice. Authors attempt to address this contentious subject using multiple meta-analyses (75) (76). The degree of bile duct obstruction determines the appropriateness of either the endoscopic or percutaneous approach. In distal or B-C type I-II blockage, endoscopic intervention is less technically challenging and is frequently the preferred option for perihilar obstruction. In advanced biliary type

III-IV obstructions, percutaneous transhepatic drainage (PTBD) is more advantageous, as it is less likely to induce cholangitis, as outlined in several guidelines (22)(77)(78). Consequently, we examined the perihilar subgroup within our patient cohort. The disparity in complications between the hilar PTBD and hilar ERCP+PTBD groups was negligible. However, an examination of the cholangitis figures prior to the percutaneous intervention revealed a statistically significant increase in the hilar ERCP+PTBD subgroup. This indicates that patients who received ERCP prior to PTBD had an increased likelihood of biliary infection. While we lack data on patients who successfully had ERCP without cholangitis, this outcome implies that percutaneous access may be less detrimental in cases of perihilar occlusion. This proposal aligns with the aforementioned guidelines' suggestions.

Preoperative cholangitis potentially raises the risk of postoperative complications such as biliary anastomotic failure. Darnell et al. revealed that cholangitis is an independent risk factor for mortality following pancreatoduodenectomy; however, it does not affect postoperative morbidity (79). Nonetheless, its status as an independent risk factor for biliary leakage remains unclear. No significant difference in biliary leakage rates was noted between patients with cholangitis and those without in the DM group. Conversely, the PM (and PML) group had a greater leakage rate; however, the limited number of instances precluded statistical significance for this finding.

The incidence of biliary leakage was dependent upon the surgical procedure and the underlying condition, with a significantly lower leak rate observed in the DM group (5.6%) relative to the PM group (14.6%) and the PML group (44%). This discovery underscores the necessity of evaluating the data within these groups independently. Prior research indicated biliary leak rates of 3-10% subsequent to pancreatoduodenectomy and as high as 11% following bile duct resection (80) (81) (50). Olthof et al. reported even higher rates of 32-36% after resection of perihilar carcinoma, but with liver resection (47). Segmental branches are involved in most perihilar resections, making these branches more vulnerable to leakage due to the extensive dissection required. This leads to compromised blood flow, which is known to be essential for the healing of biliary anastomosis (4). Based on these considerations, we formed the separate PML group, including liver resections.

The diameter of the resected bile ducts can correlate with the rate of anastomotic leakage, and it can be influenced by preoperative biliary drainage. A large diameter indicates prolonged obstruction and jaundice, which is detrimental for the patient. However, it is technically less demanding to suture or cannulate dilated ducts. A non-dilated bile duct is a verified risk factor of biliary leakage after pancreatoduodenectomy (82). Despite nearly double the number of patients experiencing biliary leakage with non-dilated bile ducts, the risk is statistically insignificant in our group. We were unable to identify such patients in the PM group. The PML group had only one patient with a non-dilated duct, and this patient developed anastomotic leakage.

Postoperative red blood cell transfusion might suggest anemia resulting from blood loss or septic complications and, consequently, could act as a marker for the likelihood of biliary leakage. After collection of the data, we considered that postprocedural transfusion is a parameter that is uniformly registered and measurable, and it will correlate with intervention-related bleeding; thus, we used it as a complication indicator. Our data indicated an increased biliary leakage ratio in patients who had transfusions; however, the difference did not achieve statistical significance. The existing literature on this risk factor is inconclusive, with only one study confirming bleeding as a substantial risk factor for biliary leakage following hepaticojejunostomy (50).

Postoperative pancreatic fistula can increase mortality and morbidity, but it is not yet verified as an independent risk factor for hepaticojejunostomy (82). We found a higher biliary leakage ratio in patients with POPF, although not significantly.

Insufficient evidence exists about the efficacy of external biliary drainage in avoiding biliary leakage. External drainage is expected to diminish bile leakage following bilioenteric anastomosis; nevertheless, due to the limited sample size, our investigation did not reveal any significant advantage of this method in pancreatoduodenectomy or perihilar bile duct resection with or without liver resection. Olthof et al. reported analogous results in their investigation of bile leakage following perihilar resection combined with liver resection (47).

Another aspect of external biliary drainage is utilizing a catheter in the differential diagnosis of postoperative biliary leakage. The direct administration of contrast material

through the catheter aids in the clear visualization of anastomotic leakage during fluoroscopic imaging.

In our clinical practice, if the patient has no signs of biliary peritonitis, we attempt to manage the leakage conservatively by retaining the intraoperatively inserted abdominal drain until the leaking disappears spontaneously. The efficacy of conservative treatment was evident in our results. If this procedure fails, surgery has historically been performed subsequently. With the development of minimally invasive techniques, the role of surgery decreased. Percutaneous therapies offer a good option because endoscopic interventions most of the time cannot be carried out on an altered anatomical structure, such as that left after a Roux-en-Y hepatico-jejunostomy. In high-volume centers, percutaneous transhepatic biliary interventions have high technical success rates (94%-100%) regardless of the presence of dilated bile ducts, as was demonstrated by other authors and our data as well (83) (84). In our practice, after a successful PTBD, if the intraabdominal catheter did not drain any more bile, it was removed. The patients were sent home with the opened PTBD, which was removed in an ambulatory setting after a final cholangiogram.

This approach is supported by publications by Mansueto et al., who report a long-term success rate (77%) of patients treated with biliary fistula, and Anglieri et al., who recommend percutaneous treatment of bile leaks as a first-line therapeutic option to avoid more invasive procedures (80)(85). In our cohort, percutaneous transhepatic drainage had low patient numbers in the minimally invasive subgroup, which limits the interpretation of the data. It was not possible to conclude whether the minimally invasive approach was superior to alternative procedures.

When excess biliary fluid results in peritonitis, reoperation is unavoidable. Various strategies have been delineated to optimize postoperative outcomes during revision surgery. Due to the deficiency of high-quality research about reoperation techniques, they can only be addressed at a low level of evidence (4). No guidelines exist regarding the consideration of external biliary drainage during relaparotomy. External biliary drainage has not demonstrated efficacy in avoiding biliary leakage in primary bilioenteric anastomosis. In the DM group, clinical success was slightly better when external drainage was used (Grade C-2) to treat biliary leakage in the relaparotomy group. Due to the

complexity of managing anastomotic leakage in the perihilar anatomical region, reoperations performed in the PM group consisted of implantation of an external biliary drainage with anastomosis reconstruction. In our practice, the preferred external drainage technique is the intraoperatively placed PTBD. Before completing the anterior aspect of the biliary anastomosis, a metallic probe is introduced through the anastomosis into the right intrahepatic bile duct. If entry from the right side is not feasible, access from the left side is recommended. The metallic probe is extracted through the intrahepatic bile duct and passed through the Glisson capsule and the 9th–10th intercostal space on the patient's right side or the subxiphoid space in the left-sided approach. The previously mentioned 8.5F or 10.2F drain is attached to the metallic probe and subsequently pulled back through the parenchyma, crossing over the anastomosis. With this external catheter, theoretically it's possible to decrease the biliary pressure and diagnose and treat any further leakage.

Nonetheless, external drainage lacks much scientific support, and there are no studies that compare the efficacy of surgical revision with external drainage. Consequently, this field requires further investigation.

5.1. Limitations

The primary limitation of this study is the retrospective examination of data, the patient composition regarding the many cases with failed ERCP, and the limited data available on the previous endoscopic intervention.

Retrospective data analysis precluded the utilization of previously established bile leak definitions; bilirubin levels were not systematically assessed in the catheter fluid of our study group; hence, we depended on expert judgments, clinical records indicating elevated biliary fluid in drain catheters, and examined intervention reports about leakage.

The methodology precluded the selection of biliary treatments based on severity and impeded direct result comparisons. The limited number of leaks and interventions diminishes the statistical power of the study.

Additionally, it was not feasible to gather other potential risk variables related to anastomotic failure. Moreover, the current investigation was conducted exclusively at a single center.

6. Conclusion

The outcomes, particularly the outstanding success rates, indicate that PTBD is both safe and effective, making it suitable as the primary option in the treatment protocol for perihilar stenosis. We determined that PTBD should be conducted in specialized centers to attain reduced mortality, morbidity, and elevated success rates.

The failure of postoperative biliary anastomosis is a severe complication of hepato-pancreato-biliary procedures, markedly elevating mortality rates. This study offers significant insights into the occurrence and management of this complication in patients receiving hepatopancreatobiliary surgery at a high-volume tertiary referral unit.

Our data indicate that the risk of anastomotic leaking is affected by the complexity of the surgical operation, with elevated rates particularly noted after perihilar bile duct resections. Although the literature proposes various risk factors for biliary anastomotic leakage, this study identified trends suggesting increased leak rates in patients with advanced comorbidities (ASA III), elevated preoperative bilirubin levels, cholangitis, postoperative red blood cell transfusion, non-dilated bile duct, or postoperative pancreatic fistula; however, these associations did not achieve statistical significance, likely due to the restricted sample size. This study assessed several strategies for managing biliary anastomotic leakage based on the severity of the problem. Our data indicate that conservative therapy is helpful for a subset of patients; nonetheless, the majority necessitated invasive actions. The majority of cases necessitated relaparotomy in conjunction with external biliary drainage. The restricted number of patients prevented us from drawing statistically significant findings about the optimal treatment modality.

This single-center study underscores the complexity of managing biliary anastomotic leaks and the necessity of a patient-specific approach.

7. Summary

Resolution of biliary obstruction and biliary anastomosis leakage is a serious challenge of hepato-pancreato-biliary interventions, increasing morbidity and mortality. This study aims to assess the technical success rate, reintervention rate, morbidity, mortality, and the learning curve of patients treated with PTBD and also evaluates the incidence of bilioenteric anastomotic leakage, their treatment options, and their outcomes at a high-volume tertiary referral center. Two retrospective cohort studies were conducted to analyze the outcomes of patients who underwent PTBD between 2007 and 2018 and biliary anastomosis formation between 2016 and 2021.

Based on the results the author suggests that PTBD is a safe and effective treatment for biliary obstructions. It may be chosen as a first-line modality in cases of high perihilar obstruction, particularly when sufficient endoscopic expertise is not available. Following an unsuccessful ERCP, the risk of developing cholangitis is higher; therefore, early PTBD can play a crucial role. Considering all of this, the author recommends the centralized management of perihilar obstructions. After perihilar resections, the risk of anastomotic leakage increases. Based on the data presented, routine intraoperative external biliary drainage is not recommended, especially in cases without liver resection, as we could not demonstrate that it prevents anastomotic leakage. If intraoperative external biliary drainage was applied and biliary leakage subsequently developed, the drain may be useful in the postoperative period, both diagnostically and to facilitate bile diversion.

The author cannot recommend a single clearly preferable modality for the management of established biliary anastomotic leakage; therefore, individualized decision-making is required in every case. In the absence of peritonitis, conservative management and minimally invasive techniques (e.g., PTBD) have a role, while in cases requiring surgical intervention, intraoperative transhepatic drainage may also be part of the therapeutic arsenal.

7.1. New scientific findings

- Perihilar resections were associated with significantly higher leakage rates compared to distal resections
- Trends (though not statistically significant) suggest increased leakage risk in patients with:
 - ASA III comorbidities
 - Elevated preoperative bilirubin
 - Preoperative cholangitis
 - Non-dilated bile ducts
 - Postoperative pancreatic fistula
 - Postoperative red blood cell transfusion
- PTBD can be performed with high technical success and low procedure-related mortality in a high-volume tertiary referral center and proved to be a viable minimally invasive option for managing anastomotic leaks
- In patients with perihilar biliary obstruction, prior unsuccessful endoscopic intervention does not significantly increase overall complication rates of subsequent percutaneous transhepatic biliary drainage; however, pre-PTBD ERCP is associated with higher rates of cholangitis, suggesting that primary PTBD may be preferable in selected high-risk cases.

8. References

1. Judah JR, Draganov PV. Endoscopic therapy of benign biliary strictures. *World J Gastroenterol.* 2007;13(26):3531-9.
2. Cai XJ, Ying HN, Yu H, Liang X, Wang YF, Jiang WB, Li JB, Ji L. Blunt Dissection: A Solution to Prevent Bile Duct Injury in Laparoscopic Cholecystectomy. *Chin Med J (Engl).* 2015;128(23):3153-7.
3. Choi JW, Kim TK, Kim KW, Kim AY, Kim PN, Ha HK, Lee MG. Anatomic variation in intrahepatic bile ducts: an analysis of intraoperative cholangiograms in 300 consecutive donors for living donor liver transplantation. *Korean J Radiol.* 2003;4(2):85-90.
4. Wellner UF, Keck T. Leakage of Hepaticojejunal Anastomosis: Reoperation. *Visc Med.* 2017;33(3):197-201.
5. Sundaram V, Jones DT, Shah NH, de Vera ME, Fontes P, Marsh JW, Humar A, Ahmad J. Posttransplant biliary complications in the pre- and post-model for end-stage liver disease era. *Liver Transpl.* 2011;17(4):428-35.
6. Altman A, Zangan SM. Benign Biliary Strictures. *Semin Intervent Radiol.* 2016;33(4):297-306.
7. Karlsen TH, Folseraas T, Thorburn D, Vesterhus M. Primary sclerosing cholangitis - a comprehensive review. *J Hepatol.* 2017;67(6):1298-323.
8. Drazilova S, Veseliny E, Lenartova PD, Drazilova D, Gazda J, Grgurevic I, Janicko M, Jarcuska P. IgG4-Related Sclerosing Cholangitis: Rarely Diagnosed, but not a Rare Disease. *Can J Gastroenterol Hepatol.* 2021;2021:1959832.
9. Rodrigues T, Boike JR. Biliary Strictures: Etiologies and Medical Management. *Semin Intervent Radiol.* 2021;38(3):255-62.
10. Shanbhogue AK, Tirumani SH, Prasad SR, Fasih N, McInnes M. Benign biliary strictures: a current comprehensive clinical and imaging review. *AJR Am J Roentgenol.* 2011;197(2):W295-306.

11. Tummala P, Munigala S, Eloubeidi MA, Agarwal B. Patients with obstructive jaundice and biliary stricture +/- mass lesion on imaging: prevalence of malignancy and potential role of EUS-FNA. *J Clin Gastroenterol*. 2013;47(6):532-7.
12. Szmola R, Farkas G, Hegyi P, Czako L, Dubravcsik Z, Hritz I, Kelemen D, Lasztity N, et al. [Pancreatic cancer. Evidence based management guidelines of the Hungarian Pancreatic Study Group]. *Orv Hetil*. 2015;156(8):326-39.
13. Fernandez YVM, Arvanitakis M. Early Diagnosis And Management Of Malignant Distal Biliary Obstruction: A Review On Current Recommendations And Guidelines. *Clin Exp Gastroenterol*. 2019;12:415-32.
14. Razumilava N, Gores GJ. Cholangiocarcinoma. *Lancet*. 2014;383(9935):2168-79.
15. Ertel AE, Bentrem D, Abbott DE. Gall Bladder Cancer. *Cancer Treat Res*. 2016;168:101-20.
16. Ahn DH, Bekaii-Saab T. Ampullary cancer: an overview. *Am Soc Clin Oncol Educ Book*. 2014:112-5.
17. Okamoto T. Malignant biliary obstruction due to metastatic non-hepato-pancreato-biliary cancer. *World J Gastroenterol*. 2022;28(10):985-1008.
18. Marrelli D, Caruso S, Pedrazzani C, Neri A, Fernandes E, Marini M, Pinto E, Roviello F. CA19-9 serum levels in obstructive jaundice: clinical value in benign and malignant conditions. *Am J Surg*. 2009;198(3):333-9.
19. Liu W, Liu Q, Wang W, Wang P, Chen J, Hong T, Zhang N, Li B, et al. Differential diagnostic roles of the serum CA19-9, total bilirubin (TBIL) and the ratio of CA19-9 to TBIL for benign and malignant. *J Cancer*. 2018;9(10):1804-12.
20. Dorrell R, Pawa S, Zhou Y, Lalwani N, Pawa R. The Diagnostic Dilemma of Malignant Biliary Strictures. *Diagnostics (Basel)*. 2020;10(5).
21. Tibana TK, Grubert RM, da Silva C, Fornazari VAV, Nunes TF. Percutaneous cholangioscopy for the treatment of choledocho-lithiasis. *Radiol Bras*. 2019;52(5):314-5.
22. Dumonceau JM, Tringali A, Papanikolaou IS, Blero D, Mangiavillano B, Schmidt A, Vanbiervliet G, Costamagna G, et al. Endoscopic biliary stenting: indications, choice

of stents, and results: European Society of Gastrointestinal Endoscopy (ESGE) Clinical Guideline - Updated October 2017. *Endoscopy*. 2018;50(9):910-30.

23. van Wanrooij RLJ, Bronswijk M, Kunda R, Everett SM, Lakhtakia S, Rimbaz M, Hucl T, Badaoui A, et al. Therapeutic endoscopic ultrasound: European Society of Gastrointestinal Endoscopy (ESGE) Technical Review. *Endoscopy*. 2022;54(3):310-32.

24. Szary NM, Al-Kawas FH. Complications of endoscopic retrograde cholangiopancreatography: how to avoid and manage them. *Gastroenterol Hepatol (N Y)*. 2013;9(8):496-504.

25. Nimura Y. Preoperative biliary drainage before resection for cholangiocarcinoma (Pro). *HPB (Oxford)*. 2008;10(2):130-3.

26. Ishiwatari H, Sato J, Sakamoto H, Doi T, Ono H. Current status of preoperative endoscopic biliary drainage for distal and hilar biliary obstruction. *Dig Endosc*. 2024;36(9):969-80.

27. Kapoor BS, Mauri G, Lorenz JM. Management of Biliary Strictures: State-of-the-Art Review. *Radiology*. 2018;289(3):590-603.

28. Molnar W, Stockum AE. Transhepatic dilatation of choledochoenterostomy strictures. *Radiology*. 1978;129(1):59-64.

29. Ring EJ, Husted JW, Oleaga JA, Freiman DB. A multihole catheter for maintaining longterm percutaneous antegrade biliary drainage. *Radiology*. 1979;132(3):752-4.

30. Kuhn JP, Busemann A, Lerch MM, Heidecke CD, Hosten N, Puls R. Percutaneous biliary drainage in patients with nondilated intrahepatic bile ducts compared with patients with dilated intrahepatic bile ducts. *AJR Am J Roentgenol*. 2010;195(4):851-7.

31. Nennstiel S, Treiber M, Faber A, Haller B, von Delius S, Schmid RM, Neu B. Comparison of Ultrasound and Fluoroscopically Guided Percutaneous Transhepatic Biliary Drainage. *Dig Dis*. 2019;37(1):77-86.

32. Wagner A, Mayr C, Kiesslich T, Berr F, Friesenbichler P, Wolkersdorfer GW. Reduced complication rates of percutaneous transhepatic biliary drainage with ultrasound guidance. *J Clin Ultrasound*. 2017;45(7):400-7.
33. Kozlov AV, Polikarpov AA, Oleshchuk NV, Tarazov PG. [Comparative assessment of percutaneous transhepatic cholangiodrainage under roentgenoscopy and ultrasound guidance]. *Vestn Rentgenol Radiol*. 2002(4):30-3.
34. Robson PC, Heffernan N, Gonen M, Thornton R, Brody LA, Holmes R, Brown KT, Covey AM, et al. Prospective study of outcomes after percutaneous biliary drainage for malignant biliary obstruction. *Ann Surg Oncol*. 2010;17(9):2303-11.
35. Sayeed MS, Ekambaram G, Rajput JPS, Parmar P, Saikhedkar S, Saiyad SS, Saiyad T. The Impact of Biliary Drainage on Quality of Life in Unresectable Biliary and Pancreatic Cancer. *Cureus*. 2025;17(2):e78986.
36. Ozcan N, Kahriman G, Mavili E. Percutaneous transhepatic removal of bile duct stones: results of 261 patients. *Cardiovasc Intervent Radiol*. 2012;35(3):621-7.
38. Chu D, Adler DG. Malignant biliary tract obstruction: evaluation and therapy. *J Natl Compr Canc Netw*. 2010;8(9):1033-44.
39. Surgery CUSDo. [Available from: <https://columbiasurgery.org/conditions-and-treatments/whipple-procedure-pancreaticoduodenectomy>].
40. Bismuth H, Corlette MB. Intrahepatic cholangioenteric anastomosis in carcinoma of the hilus of the liver. *Surg Gynecol Obstet*. 1975;140(2):170-8.
41. Gaspersz MP, Buettner S, van Vugt JLA, de Jonge J, Polak WG, Doukas M, Ijzermans JNM, Koerkamp BG, et al. Evaluation of the New American Joint Committee on Cancer Staging Manual 8th Edition for Perihilar Cholangiocarcinoma. *J Gastrointest Surg*. 2020;24(7):1612-8.
42. Jarnagin WR, Fong Y, DeMatteo RP, Gonen M, Burke EC, Bodniewicz BJ, Youssef BM, Klimstra D, et al. Staging, resectability, and outcome in 225 patients with hilar cholangiocarcinoma. *Ann Surg*. 2001;234(4):507-17; discussion 17-9.

43. Hospitals P. [Available from: <https://lirp.cdn-website.com/69c0b277/dms3rep/multi/opt/Hepaticojejunostomy-5bdc653d-960w.jpg>].
44. Cillo U, Fondevila C, Donadon M, Gringeri E, Mocchegiani F, Schlitt HJ, Ijzermans JNM, Vivarelli M, et al. Surgery for cholangiocarcinoma. *Liver Int.* 2019;39 Suppl 1(Suppl Suppl 1):143-55.
45. Nagino M, Takada T, Miyazaki M, Miyakawa S, Tsukada K, Kondo S, Furuse J, Saito H, et al. Preoperative biliary drainage for biliary tract and ampullary carcinomas. *J Hepatobiliary Pancreat Surg.* 2008;15(1):25-30.
46. Lai EC, Lau SH, Lau WY. The current status of preoperative biliary drainage for patients who receive pancreaticoduodenectomy for periampullary carcinoma: a comprehensive review. *Surgeon.* 2014;12(5):290-6.
47. Olthof PB, Coelen RJ, Wiggers JK, Besselink MG, Busch OR, van Gulik TM. External biliary drainage following major liver resection for perihilar cholangiocarcinoma: impact on development of liver failure and biliary leakage. *HPB (Oxford).* 2016;18(4):348-53.
48. Mercado MA, Chan C, Orozco H, Cano-Gutierrez G, Chaparro JM, Galindo E, Vilatoba M, Samaniego-Arvizu G. To stent or not to stent bilioenteric anastomosis after iatrogenic injury: a dilemma not answered? *Arch Surg.* 2002;137(1):60-3.
49. Witzigmann H, Lang H, Lauer H. Guidelines for palliative surgery of cholangiocarcinoma. *HPB (Oxford).* 2008;10(3):154-60.
50. de Castro SM, Kuhlmann KF, Busch OR, van Delden OM, Lameris JS, van Gulik TM, Obertop H, Gouma DJ. Incidence and management of biliary leakage after hepaticojejunostomy. *J Gastrointest Surg.* 2005;9(8):1163-71; discussion 71-3.
51. Zafar SN, Khan MR, Raza R, Khan MN, Kasi M, Rafiq A, Jamy OH. Early complications after biliary enteric anastomosis for benign diseases: a retrospective analysis. *BMC Surg.* 2011;11:19.
52. Morikawa T, Ishida M, Iseki M, Aoki S, Hata T, Kawaguchi K, Ohtsuka H, Mizuma M, et al. Liver resections in patients with prior bilioenteric anastomosis are

predisposed to develop organ/space surgical site infections and biliary leakage: results from a propensity score matching analysis. *Surg Today*. 2021;51(4):526-36.

53. Henry AC, Smits FJ, van Lienden K, van den Heuvel DAF, Hofman L, Busch OR, van Delden OM, Zijlstra IA, et al. Biliopancreatic and biliary leak after pancreatoduodenectomy treated by percutaneous transhepatic biliary drainage. *HPB (Oxford)*. 2021.

54. Giampalma E, Renzulli M, Mosconi C, Ercolani G, Pinna AD, Golfieri R. Outcome of post-liver transplant ischemic and nonischemic biliary stenoses treated with percutaneous interventions: the Bologna experience. *Liver Transpl*. 2012;18(2):177-87.

55. May K, Hunold P. Leakage of Hepaticojejunal Anastomosis: Radiological Interventional Therapy. *Visc Med*. 2017;33(3):192-6.

56. Sohn TA, Yeo CJ, Cameron JL, Geschwind JF, Mitchell SE, Venbrux AC, Lillemoe KD. Pancreaticoduodenectomy: role of interventional radiologists in managing patients and complications. *J Gastrointest Surg*. 2003;7(2):209-19.

57. Kiriya S, Kozaka K, Takada T, Strasberg SM, Pitt HA, Gabata T, Hata J, Liau KH, et al. Tokyo Guidelines 2018: diagnostic criteria and severity grading of acute cholangitis (with videos). *J Hepatobiliary Pancreat Sci*. 2018;25(1):17-30.

59. Koch M, Garden OJ, Padbury R, Rahbari NN, Adam R, Capussotti L, Fan ST, Yokoyama Y, et al. Bile leakage after hepatobiliary and pancreatic surgery: a definition and grading of severity by the International Study Group of Liver Surgery. *Surgery*. 2011;149(5):680-8.

60. Bassi C, Marchegiani G, Dervenis C, Sarr M, Abu Hilal M, Adham M, Allen P, Andersson R, et al. The 2016 update of the International Study Group (ISGPS) definition and grading of postoperative pancreatic fistula: 11 Years After. *Surgery*. 2017;161(3):584-91.

61. Pavlidis ET, Pavlidis TE. Pathophysiological consequences of obstructive jaundice and perioperative management. *Hepatobiliary Pancreat Dis Int*. 2018;17(1):17-21.

62. Ducreux M, Cuhna AS, Caramella C, Hollebecque A, Burtin P, Goere D, Seufferlein T, Haustermans K, et al. Cancer of the pancreas: ESMO Clinical Practice Guidelines for diagnosis, treatment and follow-up. *Ann Oncol*. 2015;26 Suppl 5:v56-68.
63. Farooqui W, Penninga L, Burgdorf SK, Krohn PS, Storkholm JH, Hansen CP. Relieving the bile ducts prior to pancreatoduodenectomy - A retrospective cohort study. *Ann Med Surg (Lond)*. 2022;84:104894.
64. Teoh AY, Dhir V, Jin ZD, Kida M, Seo DW, Ho KY. Systematic review comparing endoscopic, percutaneous and surgical pancreatic pseudocyst drainage. *World J Gastrointest Endosc*. 2016;8(6):310-8.
65. Moole H, Dharmapuri S, Duvvuri A, Dharmapuri S, Boddireddy R, Moole V, Yedama P, Bondalapati N, et al. Endoscopic versus Percutaneous Biliary Drainage in Palliation of Advanced Malignant Hilar Obstruction: A Meta-Analysis and Systematic Review. *Can J Gastroenterol Hepatol*. 2016;2016:4726078.
66. Yang MJ, Kim JH, Hwang JC, Yoo BM, Kim SS, Lim SG, Won JH. Usefulness of combined percutaneous-endoscopic rendezvous techniques after failed therapeutic endoscopic retrograde cholangiography in the era of endoscopic ultrasound guided rendezvous. *Medicine (Baltimore)*. 2017;96(48):e8991.
67. van der Merwe SW, van Wanrooij RLJ, Bronswijk M, Everett S, Lakhtakia S, Rimbas M, Hucl T, Kunda R, et al. Therapeutic endoscopic ultrasound: European Society of Gastrointestinal Endoscopy (ESGE) Guideline. *Endoscopy*. 2022;54(2):185-205.
68. Sut M, Kennedy R, McNamee J, Collins A, Clements B. Long-term results of percutaneous transhepatic cholangiographic drainage for palliation of malignant biliary obstruction. *J Palliat Med*. 2010;13(11):1311-3.
69. Rivera-Sanfeliz GM, Assar OS, LaBerge JM, Wilson MW, Gordon RL, Ring EJ, Kerlan RK, Jr. Incidence of important hemobilia following transhepatic biliary drainage: left-sided versus right-sided approaches. *Cardiovasc Intervent Radiol*. 2004;27(2):137-9.
70. Andriulli A, Loperfido S, Napolitano G, Niro G, Valvano MR, Spirito F, Pilotto A, Forlano R. Incidence rates of post-ERCP complications: a systematic survey of prospective studies. *Am J Gastroenterol*. 2007;102(8):1781-8.

71. Liu J-G, Wu J, Wang J, Shu G-M, Wang Y-J, Lou C, Zhang J, Du Z. Endoscopic Biliary Drainage Versus Percutaneous Transhepatic Biliary Drainage in Patients with Resectable Hilar Cholangiocarcinoma: A Systematic Review and Meta-Analysis 2018-2018-Sep-. 1053-60 p.
72. Asadi H, Hollingsworth R, Pennycooke K, Thanaratnam P, Given M, Keeling A, Lee M. A review of percutaneous transhepatic biliary drainage at a tertiary referral centre. *Clin Radiol*. 2016;71(12):1312 e7- e11.
73. Nennstiel S, Weber A, Frick G, Haller B, Meining A, Schmid RM, Neu B. Drainage-related Complications in Percutaneous Transhepatic Biliary Drainage: An Analysis Over 10 Years. *J Clin Gastroenterol*. 2015;49(9):764-70.
74. Donnellan F, Enns R, Kim E, Lam E, Amar J, Telford J, Byrne MF. Outcome of repeat ERCP after initial failed use of a needle knife for biliary access. *Dig Dis Sci*. 2012;57(4):1069-71.
75. Hameed A, Pang T, Chiou J, Pleass H, Lam V, Hollands M, Johnston E, Richardson A, et al. Percutaneous vs. endoscopic pre-operative biliary drainage in hilar cholangiocarcinoma - a systematic review and meta-analysis. *HPB : the official journal of the International Hepato Pancreato Biliary Association*. 2016;18(5):400-10.
76. Duan F, Cui L, Bai Y, Li X, Yan J, Liu X. Comparison of efficacy and complications of endoscopic and percutaneous biliary drainage in malignant obstructive jaundice: a systematic review and meta-analysis. *Cancer Imaging*. 2017;17(1):27.
77. Khan SA, Davidson BR, Goldin RD, Heaton N, Karani J, Pereira SP, Rosenberg WM, Tait P, et al. Guidelines for the diagnosis and treatment of cholangiocarcinoma: an update. *Gut*. 2012;61(12):1657-69.
78. Paik WH, Park YS, Hwang JH, Lee SH, Yoon CJ, Kang SG, Lee JK, Ryu JK, et al. Palliative treatment with self-expandable metallic stents in patients with advanced type III or IV hilar cholangiocarcinoma: a percutaneous versus endoscopic approach. *Gastrointest Endosc*. 2009;69(1):55-62.
79. Darnell EP, Wang TJ, Lumish MA, Hernandez-Barco YG, Weniger M, Casey BW, Qadan M, Lillemoe KD, et al. Preoperative cholangitis is an independent risk factor

for mortality in patients after pancreatoduodenectomy for pancreatic cancer. *Am J Surg.* 2021;221(1):134-40.

80. Angileri SA, Gorga G, Tortora S, Avriilingi M, Petrillo M, Ierardi AM, Carrafiello G. Biliary injuries after pancreatic surgery: interventional radiology management. *Gland Surg.* 2019;8(2):141-9.

81. Antolovic D, Koch M, Galindo L, Wolff S, Music E, Kienle P, Schemmer P, Friess H, et al. Hepaticojejunostomy--analysis of risk factors for postoperative bile leaks and surgical complications. *J Gastrointest Surg.* 2007;11(5):555-61.

82. Duconseil P, Turrini O, Ewald J, Berdah SV, Moutardier V, Delpero JR. Biliary complications after pancreaticoduodenectomy: skinny bile ducts are surgeons' enemies. *World J Surg.* 2014;38(11):2946-51.

83. Cozzi G, Severini A, Civelli E, Milella M, Pulvirenti A, Salvetti M, Romito R, Suman L, et al. Percutaneous transhepatic biliary drainage in the management of postsurgical biliary leaks in patients with nondilated intrahepatic bile ducts. *Cardiovasc Intervent Radiol.* 2006;29(3):380-8.

84. de Jong EA, Moelker A, Leertouwer T, Spronk S, Van Dijk M, van Eijck CH. Percutaneous transhepatic biliary drainage in patients with postsurgical bile leakage and nondilated intrahepatic bile ducts. *Dig Surg.* 2013;30(4-6):444-50.

85. Mansueto G, Gatti FL, Boninsegna E, Conci S, Guglielmi A, Contro A. Biliary Leakage After Hepatobiliary and Pancreatic Surgery: A Classification System to Guide the Proper Percutaneous Treatment. *Cardiovasc Intervent Radiol.* 2020;43(2):302-10.

Bibliography of the candidate's publication in relation to the thesis

58. Kokas B, Szijarto A, Farkas N, Ujvary M, Mori S, Kalocsai A, Szucs A. Percutaneous transhepatic drainage is safe and effective in biliary obstruction-A single-center experience of 599 patients. *PLoS One.* 2021;16(11):e0260223.

86. Kokas B, Ulmann L, Rozman P, Farkas N, Szijarto A, Szucs A. Postoperative bile leak after hepato-pancreato-biliary surgery in malignant biliary obstruction: rates, treatments, and outcomes in a high-volume tertiary referral center. *BMC Surg.* 2024;24(1):410.

9. Bibliography of the candidate's publications

37. Huszar O, Kokas B, Matrai P, Hegyi P, Petervari E, Vincze A, Par G, Sarlos P, et al. Meta-Analysis of the Long Term Success Rate of Different Interventions in Benign Biliary Strictures. *PLoS One*. 2017;12(1):e0169618.
86. Cantalejo-Diaz M, Ramia JM, Alvarez-Busto I, Kokas B, Blanco-Fernandez G, Munoz-Forner E, Olah A, Montalva-Oron E, et al. Long-term outcomes after breast cancer liver metastasis surgery: A European, retrospective, snapshot study (LIBREAST STUDY). *Surg Oncol*. 2024;57:102129.
87. Hahn O, Bardos D, Kupcsulik P, Szijarto A, Fulop A, Kokas B, Pekli D, Zsirka-Klein A, et al. [Decreasing morbidity after Associating Liver Partition and Portal vein ligation for Staged hepatectomy (ALPPS) with technical modification and patient selection]. *Orv Hetil*. 2019;160(32):1260-9.
88. Hahn O, Kupcsulik P, Pekli D, Fulop A, Bardos D, Kokas B, Szijarto A. Majsebeszet a Semmelweis Egyetem I. sz. Sebészeti Klinikáján. *Magy Seb*. 2020;73(3):95-9.
89. Illes K, Tamas J, Pekli D, Szlavik R, Kokas B, Szijarto A. [A rare type of hernia seen twice in our department]. *Magy Seb*. 2020;73(4):167-71.
90. Kokas B, Krizsany G, Pekli D, Meltzer A, Bardos D, Rozsa B, Bibok A, Korda D, et al. [A new method to enhance liver regeneration: double venous deprivation of the liver]. *Orv Hetil*. 2024;165(36):1433-9.
91. Korda DA, Bibok A, Doros A, Horvathy D, Hahn O, Kokas B, Pekli D, Meltzer AZ, et al. Initial experience with Double-vein Embolization in Hungary. *Eur J Radiol Open*. 2024;13:100613.
92. Pekli D, Kokas B, Bardos D, Fulop A, Pajor P, Hahn O, Illyes I, Kovacs A, et al. [Multimodality management of focal nodular hyperplasia]. *Orv Hetil*. 2022;163(15):606-12.

10. Acknowledgements

I would like to express my deepest gratitude to my thesis leader, Dr. Ákos Szücs, whose guidance, support, and encouragement were invaluable throughout the entire process of completing this PhD. Without his unwavering belief in my abilities and his dedicated mentorship, this work would not have been possible.

I extend my heartfelt thanks to Professor Attila Szijártó, the chief of the clinic, for providing me with the opportunity to conduct my research within an environment of excellence. His leadership and commitment to fostering academic and clinical advancement have been a great source of inspiration.

I am profoundly grateful to Dr. Oszkár Hahn, my main mentor in the surgical field. His expertise, patience, and insightful guidance have played a pivotal role in shaping both my professional growth and the direction of this research. His mentorship has been a cornerstone of my journey.

I would also like to acknowledge my co-authors, whose diligence in the collection of the enormous amount of data required for this research has been remarkable. Their collaborative spirit, meticulous work, and dedication have significantly contributed to the success of this endeavor.

Finally, I want to thank my wife, my family, my friends, and my colleagues for their constant encouragement and support throughout this journey. Their belief in me has been a driving force, and I am forever grateful for their presence in my life.